

Retinopathy of Prematurity: Clinical Features, Classification, Natural History, Management and Outcome

PARAG K SHAH, VISHMA PRABHU, RATNESH RANJAN, VENKATAPATHY NARENDRAN AND NARENDRAN KALPANA

From Pediatric Retina and Ocular Oncology Department, Aravind Eye Hospital & Postgraduate Institute of Ophthalmology, Coimbatore, Tamilnadu, India.

Correspondence to: Dr Parag K Shah, Department of Pediatric Retina and Ocular Oncology, Aravind Eye Hospital, Avinashi Road, Coimbatore 641 014, Tamil Nadu, India. drshahpk2002@yahoo.com

Context: Retinopathy of prematurity is an avoidable cause of childhood blindness. Proper understanding of the classification and treatment methods is a must in tackling this disease.

Evidence acquisition: Literature search with PubMed was conducted covering the period 1940-2015 with regards to retinopathy of prematurity, retrolental fibroplasia, its natural history, classification and treatment.

Results: The clinical features, screening and staging of retinopathy of prematurity according to International classification of retinopathy of prematurity (ICROP) has been included with illustrations. The standard current treatment indications, modalities and outcomes from landmark randomized controlled trials on retinopathy of prematurity have been mentioned.

Conclusions: This review would help pediatricians to update their current knowledge on classification and treatment of retinopathy of prematurity. Screening for retinopathy of prematurity, in India, should be performed in all preterm neonates who are born <34 weeks gestation and/or <1750 grams birthweight; as well as in babies 34-36 weeks gestation or 1750-2000 grams birthweight if they have risk factors for ROP. Screening should start by one month after birth.

Keywords: *Review, Update, Retrolental fibroplasia, Prematurity.*

Retinopathy of prematurity (ROP) formerly known as retrolental fibroplasia is an enigmatic disease of the developing retinal vasculature of the prematurely born infants. It is a vasoproliferative retinopathy, first described by Terry [1] in 1942 in a premature infant who had grayish white vascular membranes behind the lens in both the eyes. Unlike the vast number of diseases, this was not a disease that was present for decades or centuries just waiting to be discovered. This disease did not exist before the 1930s. It began, as we now know, when infant incubators came into use and supplemental oxygen was seen to promote the survival of prematurely born infants.

Its incidence increases with decreasing gestation and birthweight [2,3]. Apart from prematurity, the other risk factors of ROP include: hyperoxia, sepsis, blood transfusions, acidosis, antioxidant deficiency, patent ductus arteriosus and apnea.

In the Indian scenario, screening for ROP should be performed in all preterm neonates who are born <34 weeks gestation and/or <1750 g birthweight; as well as in babies 34-36 weeks gestation or 1750-2000 g birthweight if they have risk factors for ROP. These are India specific NNF guidelines and are different from Western countries due to a number of reasons [4]. Screening should start by one

month after birth, and as early as 2-3 weeks of age in infants born <28 wks or <1200g birthweight as per these guidelines [5]. Meticulous coordination between the neonatologist, neonatal nurses and the ophthalmologist is required [6].

CLINICAL FEATURES AND CLASSIFICATION

Retinopathy of prematurity is generally classified according to the International Classification of ROP (ICROP) [7-9]. This classification system uses retinal landmarks to minimize inter-examiner variability.

ROP is classified based on the zone, extent of disease, stage, and followed by documentation of the status of the vessels in the posterior pole (plus disease).

1. **Zone:** It refers to the location of the disease. The purpose of the zone is to define the anteroposterior location of the retinopathy. Accordingly, retina can be divided into three concentric zones of retinal involvement with each zone centered on the optic disc though the true centre of retina is the fovea. This is because vascularisation proceeds from optic nerve and progresses towards ora serrata. Zone 1 which is the inner most zone consists of a circle, whose radius is twice the disc-to-fovea distance in all directions from the optic disc, roughly an angle of 30°. This distance is

about the same as the viewing field of a 30 diopter lens. Zone II extends from the edge of zone I peripherally to the nasal ora serrata and continues temporally along the same radius of curvature. Zone III is the residual temporal crescent anterior and lateral to zone II. The more posterior the location of ROP, more severe it is (**Fig. 1**).

- Extent:** The extent of the ROP is determined by the number of clock hours of retina involved. For the observer examining each eye, the nasal side of the right eye is at 3'O clock and the nasal side of the left eye is at 9'O clock (**Fig. 1**).
- Staging:** It indicates the degree of abnormal vascular changes at the junction of the vascular and avascular retina. The vascularized retina of premature infants without ROP blends almost imperceptibly into the anterior, non-vascularized retina. These are called immature retinal vessels. Some also call it as stage 0 ROP. With the onset of clinically apparent ROP, the junction between the vascularized and avascular retina becomes more pronounced. There are 5 stages to describe the abnormal vascular response at the junction of vascularised and avascular retina.

(a) *Stage 1- Demarcation line:* The demarcation line is seen as a distinct white and flat line but still lies within the plane of the retina, which separates the avascular retina anteriorly from vascular retina posteriorly (**Web Fig. 1A**).

(b) *Stage 2- Ridge of elevated tissue:* In this stage the demarcation line will have height and width. This ridge may be white or pink and rarely, vessels may leave the surface of the retina to enter it. Small tufts

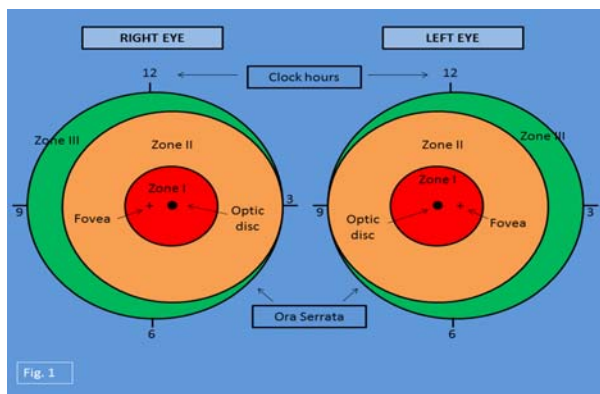


FIG. 1 Schematic diagram of right eye and left eye showing zones to describe location of disease and clock hours to describe extent of ROP. Zone I location (red colour) has highest risk of blindness. Zone II (orange colour) has moderate risk and zone III (green colour) has least risk of blindness. (See color image at website).

of new vessels also called as “popcorn” lesions may be seen located posterior to the ridge, but not attached to it (**Web Fig. 1B**).

- Stage 3- Ridge with extraretinal fibrovascular proliferation:* This stage is characterised by extraretinal, fibrovascular tissue proliferating from the ridge into the vitreous. The proliferating tissue is localised continuous with the posterior and anterior aspect of the ridge, causing a ragged appearance of the ridge (**Web Fig. 1C**).
 - Stage 4- Subtotal retinal detachment:* This is characterised by partial detachment of the retina which may be due to exudative effusion of fluid, traction or both. This stage is sub divided into stage 4A, which is extrafoveal retinal detachment. It is a convex tractional detachment which occurs in the periphery without macular involvement (**Web Fig. 1D**). Stage 4B consists of partial retinal detachment involving the fovea (**Web Fig. 2A**).
 - Stage 5- Total Retinal Detachment:* This is the end stage where there is total detachment (**Web Fig. 2B**). The detachment is mostly funnel shaped, and the funnel is usually divided into anterior and posterior part.
- Plus Disease:** It is a sign indicating severity of ROP and is defined as venous dilation and arterial tortuosity of the vasculature in the posterior pole (**Web Fig. 2C**). It may be associated with rigid pupil, vitreous haze or neovascularization of the iris. It is one of the most important signs warranting treatment.
 - Pre-Plus Disease:** It is defined as vascular abnormalities of the posterior pole that are insufficient for the diagnosis of plus disease but demonstrate more arteriolar tortuosity and more venous dilation than normal [9]. Thus it is an intermediate level of plus disease between frank plus disease and normal posterior pole vessels (**Web Fig. 2D**).

- Aggressive Posterior ROP (AP-ROP):** It is an uncommon, rapidly progressive, severe form of ROP previously referred to as “rush disease.” It is characterized by posterior location, rapidly evolving plus disease, and neovascularization that may be subtle or even intraretinal in nature [9]. Early in the development of AP-ROP, the posterior pole vessels usually exhibit dilation and tortuosity in all four quadrants. ROP may initially manifest as only a flat network of neovascularisation at the junction of the vascularized and avascularized retina (**Web Fig. 3**). These vascular changes can often be overlooked by a less experienced examiner and the eye may rapidly end

up in retinal detachment and blindness (stage 5 disease) without intervention. In developed countries, AP-ROP is usually seen in lowest birth weight infants, however in India it has also been reported in bigger preterm infants commonly due to exposure to excessive oxygen in unblended form [10].

NATURAL HISTORY

There is no disease at birth in a premature baby's eye. The retina can be immature, that is, incompletely vascularised which is normal for the premature age because retina matures in normal babies by about 40 weeks that is close to the expected date of delivery. ROP starts within 30 days of birth in the retina and hence, the first ROP retinal screening must be completed by 30 days of birth [4]. ROP is a disease in which most of the cases regress spontaneously either by involution or evolution from a vasoproliferative phase to a fibrotic phase. The process of regression most commonly occurs at the junction of vascular and avascular retina. On serial examination, anteroposterior location of retinopathy may change from zone I to zone II or zone II to zone III and the ridge will change its colour from salmon pink to white [6]. The reported incidence of acute ROP varies from 9.8% to 72.7% and that of threshold ROP varies from 3.6% to 34.8% [11-16]. Spontaneous regression can be seen in stage 1, stage 2 and early stage 3 without plus disease (depending on zone), and the rest of the cases could progress to form retinal detachment and severe distortion of the posterior retina that leads to visual disability or even blindness [17].

During the natural history of ROP, it was seen that vascular congestion in the posterior pole acts as an important clinical indicator of the activity of the shunt lesions in active phase. Similarly reduced congestion and tortuosity of vessels indicated early regression [9]. In two major Cryotherapy for Retinopathy of Prematurity Cooperative Group (CRYO-ROP) studies [18,19] prognosis of ROP was based on the presence of plus disease, location by zone of the disease and the ROP status. Early Treatment for Retinopathy of Prematurity Cooperative Group (ETROP) study [20] confirmed the importance of plus disease and zone. Hence the more posterior the disease, the presence of plus disease, and the presence of stage 3 disease all increase the risk of progression to an unfavourable outcome [21].

TREATMENT

Indications for Treatment

The ICROP classification gives the various stages of ROP but it did not suggest when to start treating ROP. The treatment guidelines were given by two landmark trials, the CRYO-ROP [19] and ETROP [20].

Threshold disease: In 1988, the CRYO-ROP [19] study recommended that peripheral retinal ablation at threshold stage can prevent progression to retinal detachment. It is defined as Stage 3 in zone I or II involving > 5 contiguous or 8 cumulative clock hours with plus disease. If untreated, the risk of unfavourable outcome at threshold disease is nearly 50%.

After following the CRYO-ROP guidelines as the standard of care for a decade, many ophthalmologists questioned the timing indications for treatment of ROP and advocated earlier treatment. However, the idea of earlier treatment had a concern of the expected increase in laser treatment in eyes with ROP that might otherwise regress spontaneously.

High Risk Prethreshold or Type I ROP: In 1999, the National Eye Institute (Bethesda, USA) started the ETROP study [20] to estimate the new criteria for earlier treatment, using a computer-based algorithm, RM-ROP which included more detailed risk criteria than were used in CRYO-ROP. In 2003, the CRYO-ROP treatment criteria were replaced with the ETROP treatment criteria. Retinal ablative therapy should be given to Type 1 ROP, which is defined as zone I any stage with plus disease or zone I stage 3 without plus or zone II stages 2 or 3 with plus. For an eye with type 2 ROP, treatment should be considered when it progresses to type 1 prethreshold or threshold ROP. Type 2 ROP is defined as zone I, stage 1 or 2 ROP without plus or zone II stage 3 without plus.

Treatment Methods and Outcomes

For the vasoproliferative stage of disease (high risk prethreshold and threshold stages), the principle of management includes ablation of the peripheral non-vascularized retina which stops release of angiogenic factors. Surgical management is required for cicatricial stages (4 and 5). Surgical modalities mainly target release of tractional membranes developing in the late stage of disease.

Cryotherapy: In 1980s, based on the concept of ablation of non-vascularised retina, cryotherapy emerged as the first standard treatment modality for acute phase ROP. It involves freezing from the external ocular surface, affecting the sclera, choroid, and the full thickness of the retina. Cryotherapy is not very popular now as it needs general anaesthesia or sedation, and post-operative complications include pain, lid oedema, conjunctival laceration and haemorrhage, preretinal and vitreous haemorrhage [22].

Laser therapy: Over the period, clinical studies established the superiority of laser therapy to cryotherapy, and laser photocoagulation evolved as the

technique of choice for ablation of the avascular retina in ROP in 1990s [23]. Laser photocoagulation involves transpupillary confluent or near confluent application of burns using indirect ophthalmoscopic delivery. Laser therapy has resulted in better visual outcomes and fewer adverse effects including less stress on the neonate compared to cryotherapy [24]. The main advantages are that it can be performed under topical anesthesia and systemic and local complications are much less compared to cryotherapy. Laser photocoagulation was the main ablative treatment used in ETROP study, and a reduction in unfavourable visual outcomes from 19.5% to 14.5% and unfavourable structural outcomes from 15.6% to 9.1% was noted at 9 months with earlier treatment [20].

Intravitreal Anti-vascular endothelial growth factor (VEGF) therapy: In 2007 initial case reports were published, describing fast regression of ROP after single intravitreal injection of bevacizumab alone or in combination with laser treatment [25]. Since then off-label use of anti-VEGF agents, primarily bevacizumab, is emerging as a popular therapeutic modality for acute ROP. Bevacizumab Eliminates the Angiogenic Threat of Retinopathy of Prematurity (BEAT-ROP) study [26] is the first prospective, randomized, controlled, stratified, multicenter clinical study that established superior efficacy of intravitreal bevacizumab monotherapy compared to conventional laser therapy for stage 3+ ROP for zone I, but not for zone II disease. Although, no systemic or local toxic effects attributable to bevacizumab were observed, the study concluded that the population size was too small to assess safety of bevacizumab treatment. Intravitreal anti-VEGF injections are very controversial as they may stop growth of not only abnormal retinal new vessels but also of the normal ones. Systemic absorption of these drugs [27] may stop vascular development in other developing organs. Moreover late reactivation, choroidal ruptures and abnormal liver function tests have also been reported [28, 29]. Thus currently anti-VEGF injections are used in ROP only when the standard treatment (which is laser) fails or in cases with severe APROP.

Surgery: Despite the good efficacy of therapies mentioned earlier, a significant number of eyes progress to the stages 4 or 5, especially in countries like India, partly due to lack of awareness [30]. Surgery is the only treatment modality for advanced ROP stages, and several procedures have been described. The choice of technique depends on the stage of ROP, location of the traction and the presence or absence of retina-lens apposition. Surgical modalities include scleral buckling or lens-sparing vitrectomy for stages 4, and lensectomy with vitrectomy or open sky vitrectomy for stage 5 [31].

Anatomical success is 90%, 44.4% and only 14.3% for stages 4A, 4B and 5 respectively. Visual success can be good with central fixation for stage 4A, ambulatory or form vision for stage 4B and only perception of light for stage 5 [31].

CONCLUSION

India has the highest number of preterm deliveries in the world and hence, a huge burden of ROP [32]. Staging the disease correctly, following the international treatment guidelines and timely screening could help in reducing this burden. ROP blindness is incurable and only way to avoid this is by dilated retinal examination of all premature at risk babies definitely by 30 days of birth [4].

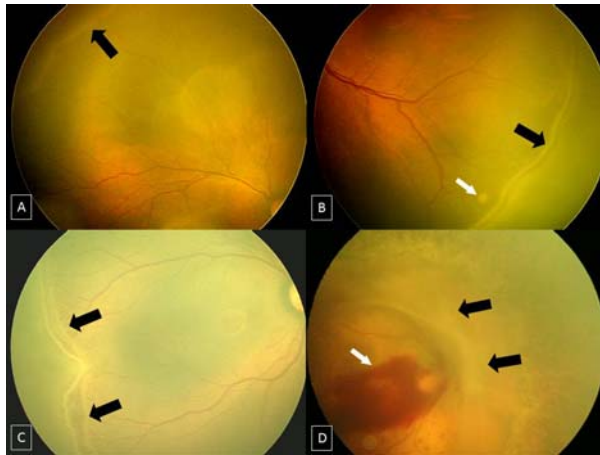
Contributors: PKS, VP, RR, VN, NK: (i) Substantial contributions to the conception or design of the work; or the acquisition, analysis, or interpretation of data for the work; AND (ii) Drafting the work or revising it critically for important intellectual content; AND (iii) Final approval of the version to be published; AND (iv) Agreement to be accountable for all aspects of the work in ensuring that questions related to the accuracy or integrity of any part of the work are appropriately investigated and resolved.

Funding: None; *Competing interest:* None stated.

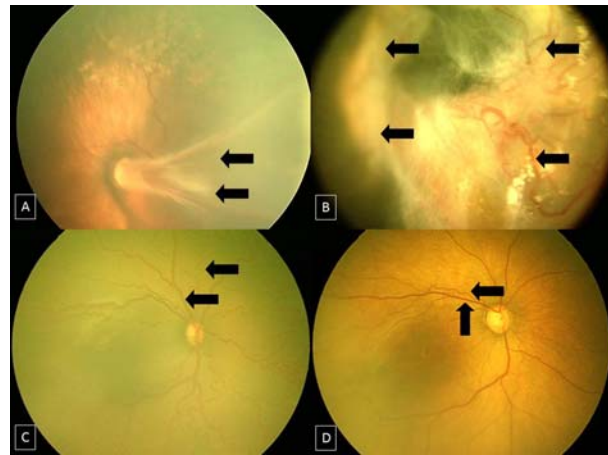
REFERENCES

1. Terry TL. Extreme prematurity and fibrovascular overgrowth of persistent vascular sheath behind each crystalline lens. *Am J Ophthalmol.* 1942;25:203.
2. Bossi E, Koerner F. Retinopathy of prematurity. *Intensive Care Med.* 1995;21:241-6.
3. Keith CG, Doyle LW. Retinopathy of prematurity in extremely low birth weight infants. *Pediatrics.* 1995;95:42-5.
4. Pjaver RK, Bilagi AP, Vinekar A, Deorari AK, Jalali S. Evidence based ROP guidelines in the NNF Evidence based guidelines. 2010. P. 253-63. Available from http://aimaonline.org/iap-neochap-2013/uploads/acd-corner/nnf_guidelines-2011.pdf. Accessed April 15, 2015.
5. Jalali S, Anand R, Rani PK, Balakrishnan D. Impact of the day-30 strategy in the disease presentation and outcome of ROP. The Indian Twin Cities ROP report number 3. *Indian J Ophthalmol.* 2014;62:610-4.
6. Jalali S, Anand R, Kumar H, dogra MR, Azad RV, Gopal L. Program planning and screening strategy in ROP. *Indian J Ophthalmol.* 2003;51:89-99.
7. The Committee for the Classification of Retinopathy of Prematurity. An International Classification of Retinopathy of Prematurity. *Arch Ophthalmol.* 1984; 102:1130-4.
8. The International Committee for the Classification of the Late Stages of Retinopathy of Prematurity. An International Classification of Retinopathy of Prematurity. II. The classification of retinal detachment. *Arch Ophthalmol.* 1987;105:906-12.
9. International Committee for the Classification of Retinopathy of Prematurity. The International

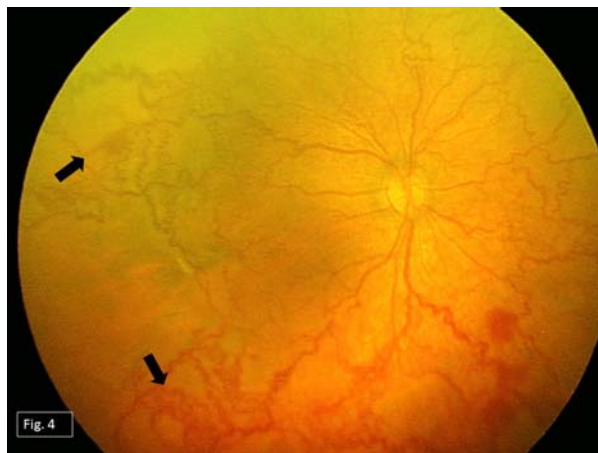- Classification of Retinopathy of Prematurity Revisited. *Arch Ophthalmol.* 2005;123:991-9.
10. Shah PK, Narendran V, Kalpana N. Aggressive posterior retinopathy of prematurity in large preterm babies in South India. *Arch Dis Child Fetal Neonatal Ed.* 2012;97:F371-5.
 11. Akman I, Demirel U, Yenice O, Ilerisoy H, Kazokoglu H, Ozek E. Screening criteria for retinopathy of prematurity in developing countries. *Eur J Ophthalmol.* 2010;20:931-7.
 12. Austeng D, Kallen KB, Ewald UW, Jakobsson PG, Holmstrom GE. Incidence of retinopathy of prematurity in infants born before 27 weeks' gestation in Sweden. *Arch Ophthalmol.* 2009;127:1315-9.
 13. Lad EM, Hernandez-Boussard T, Morton JM, Moshfeghi DM. Incidence of retinopathy of prematurity in the United States: 1997 through 2005. *Am J Ophthalmol.* 2009;148:451-8.
 14. Gu MH, Jin J, Yuan TM, Yu HM. Risk factors and outcomes for retinopathy of prematurity in neonatal infants with a birth weight of 1501-2000g in a Chinese neonatal unit. *Med Princ Pract.* 2011;20:244-7.
 15. Chen Y, Li XX, Yin H, Gilbert C, Liang JH, Jiang YR, *et al*; Beijing ROP Survey Group. Risk factors for retinopathy of prematurity in six neonatal intensive care units in Beijing, China. *Br J Ophthalmol.* 2008;92:326-30.
 16. Chiang MF, Arons RR, Flynn JT, Starren JB. Incidence of retinopathy of prematurity from 1996 to 2000: Analysis of a comprehensive New York state patient database. *Ophthalmology.* 2004;111:1317-25.
 17. Quinn GE, Gilbert C, Darlow BA, Zin A. Retinopathy of prematurity: An epidemic in the making. *Chin Med J (Engl).* 2010;123:2929-37.
 18. Schaffer DB, Palmer EA, Plotsky DF, Metz HS, Flynn JT, Tung B, *et al.* The Cryotherapy for Retinopathy of Prematurity Cooperative Group. Prognostic factors in the natural course of retinopathy of prematurity. *Ophthalmology.* 1993;100:230-37.
 19. Cryotherapy for Retinopathy of Prematurity Cooperative Group. Multicenter trial of cryotherapy for retinopathy of prematurity: Preliminary results. *Arch Ophthalmol.* 1988;106:471-9.
 20. Early Treatment for Retinopathy of Prematurity Cooperative Group: Revised indications for the treatment of retinopathy of prematurity. Results of the early treatment for retinopathy of prematurity randomized trial. *Arch Ophthalmol.* 2003;121:1684-96.
 21. Reynolds JD. Retinopathy of Prematurity. *In: Reynolds JD, Olitsky SE, editors. Pediatric Retina.* Berlin: Springer; 2011. P. 85-116.
 22. Jandeck C, Kellner U, Heimann H, Foerster MH. Comparison of the anatomical and functional outcome after laser or cryotherapy for retinopathy of prematurity (ROP). *Ophthalmologie.* 2005;102:33-8.
 23. Paysee EA, Lindsey JL, Coats DK, Contant CF Jr, Steinkuller PG. Therapeutic outcomes of cryotherapy versus transpupillary diode laser photocoagulation for threshold retinopathy of prematurity. *J AAPOS.* 1999;3:234-40.
 24. Hubbard GN 3rd. Surgical management of retinopathy of prematurity. *Curr Opin Ophthalmol.* 2008;19:384-90.
 25. Shah PK, Narendran V, Tawansy KA, Raghuram A, Narendran K. Intravitreal bevacizumab (Avastin) for post laser anterior segment ischemia in aggressive posterior retinopathy of prematurity. *Indian J Ophthalmol.* 2007;55:75-6.
 26. Mintz-Hittner HA, Kennedy KA, Chuang AZ; BEAT-ROP Cooperative Group. Efficacy of intravitreal bevacizumab for stage 3+ retinopathy of prematurity. *N Engl J Med.* 2011;364:603-15.
 27. Wu WC, Lien R, Liao PJ, Wang NK, Chen YP, Chao AN, *et al.* Serum levels of vascular endothelial growth factor and related factors after intravitreal bevacizumab injection for retinopathy of prematurity. *JAMA Ophthalmol.* 2015;133:391-7.
 28. Wong RK, Hubschman S, Tsui I. Reactivation of retinopathy of prematurity after ranibizumab treatment. *Retina.* 2015;35:675-80.
 29. Klufas MA, Chan RV. Intravitreal Anti-VEGF therapy treatment for Retinopathy of Prematurity: what we know after 7 years. *J Pediatr Ophthalmol Strabismus.* 2015;52:77-84.
 30. Sathiamohanraj SR, Shah PK, Senthilkumar D, Narendran V, Kalpana N. Awareness of retinopathy of prematurity among pediatricians in a tier two city of South India. *Oman J Ophthalmol.* 2011;4:77-80.
 31. Shah PK, Narendran V, Kalpana N, Tawansy KA. Anatomical and visual outcome of stages 4 and 5 retinopathy of prematurity. *Eye.* 2009;23:176-80.
 32. Lawn JE, Kinney MV, Belizan JM, Mason EM, McDougall L, Larson J, *et al.*; Born Too Soon Preterm Birth Action Group. Born too soon: Accelerating actions for prevention and care of 15 million newborns born too soon. *Reprod Health.* 2013;10:S6.



Web FIG. 1 (A): Fundus picture of right eye showing stage 1 demarcation line (black arrow). (B): Fundus picture of left eye showing stage 2 elevated ridge (black arrow). "Popcorn" new vessel is shown in white arrow. (C): Fundus picture of right eye showing stage 3 with extra retinal fibrovascular proliferation ridge (black arrows). (D): Fundus picture of right eye showing stage 4A partial retinal detachment (black arrows) nasal to optic disc and vitreous hemorrhage (white arrow) over macula.



Web FIG. 2 (A): Fundus picture of left eye showing stage 4B partial retinal detachment involving the macula (black arrows). (B): Fundus picture of right eye showing total retinal detachment (black arrows). (C): Fundus picture of right eye showing dilatation and tortuosity of posterior pole vessels (black arrows) signifying plus disease. (D): Fundus picture of right eye showing mild dilatation and tortuosity of posterior pole vessels (black arrows) signifying pre plus disease.



Web FIG. 3 Fundus picture of right eye showing posterior location of the disease, posterior pole vessel dilatation with tortuosity and flat new vessels (black arrows), suggestive of Aggressive Posterior ROP.