

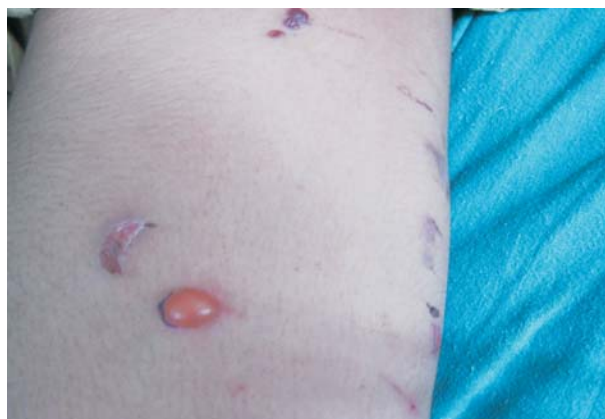

FIG. 1 Tense, hemorrhagic bullae, bizarre shaped, crescent shaped and linear superficial erosions over the thigh.

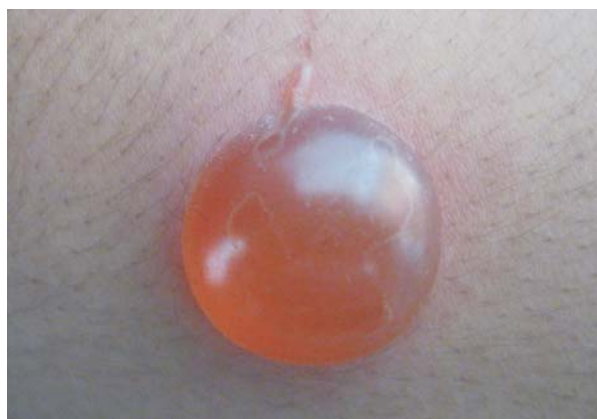

FIG. 2 A tense blister with linear erythema and vesiculation indicating streaking.

impulse control and admitted to inducing lesions with chemicals and pinching. She was kept under observation and treated with Olanzapine and topical antibiotics with counseling which led to healing of lesions.


Dermatitis artefacta is a disorder of self-injurious behavior for psychological gain. There is predominant involvement of adolescent females. Bullous dermatitis artefacta can be differentiated from immunobullous diseases by the erratic history, overnight onset and presence of bizarre, linear or geometric lesions and superficial erosions. The lesions can be induced by

picking, pinching, burning, scalding with chemicals, suctioning or cryoinjury. The management should include avoidance of confrontation, behavioral therapy, and appropriate pharmacotherapy. A high index of suspicion can ensure timely psychiatric intervention.

D PANDHI AND A SINGAL

*Department of Dermatology and STD,
University College of Medical Sciences and
Guru Tegh Bahadur Hospital,
University of Delhi, Delhi, India.
deepikapandhi@rediffmail.com*

BOOK REVIEW



Principles of Medical Education

**TEJINDER SINGH, PIYUSH GUPTA
AND DALJIT SINGH**

*Jaypee Brothers; New Delhi
Pages: 210; Price: Rs. 295/-.*

This is an excellent compilation of every possible aspect of medical education; needs of both the learner and the teacher have been attended to. Complex concepts have been made comprehensible through generous use of examples. I particularly enjoyed the chapters that dealt

with clinical teaching, and with assessment. We teachers are sorely in need of reminding that there is a method to the madness of teaching, and many advantages to learning how to teach effectively. Medical students must get the best learning deal possible to ensure they become competent, humane, and ethical medical practitioners. This book is a big step in that direction.

UPREET DHALIWAL

*Professor of Ophthalmology,
University College of Medical Sciences; and
Dean, Faculty of Medical Sciences,
University of Delhi, Delhi 110 095, India.
upreetdhaliwal@yahoo.com*