FANCONI'S ANEMIA : A CLINICO-HEMATOLOGICAL AND CYTOGENETIC STUDY

U.H Athale
S.R. Rao
P.R. Kadam
B. Gladstone
C.N. Nair
P.A. Kurkure
S.H. Advani

ABSTRACT

Eleven patients with typical features of Fanconi's anemia with cytogenetic studies were evaluated. Cytogenetic abnormalities was seen in all but one patient. Two patients had acute non-lymphoblastic leukemia (ANLL) and nine had Fanconi's anemia (FA). All patients with FA responded to oxymetholone and are well with a median follow up of 38.6 months. Both patients with ANLL died. This study stresses the need of an accurate cytogenetic analysis in FA patients along with a clinicohematological correlation.

Key words: *Fanconi's anemia, Cytogenetics.*

From the Department of Medical Oncology, Tata Memorial Hospital, Dr. Ernest Borges Marg, Parel, Bombay 400 012.

Reprint requests: Dr. S.H. Advani, Department of Medical Oncology, Tata Memorial Hospital, Dr. Ernest Borges Marg, Parel, Bombay 400 012.

Received for publication July 31, 1990; Accepted January 7, 1991

Fanconi's anemia (FA) is characterised clinically by progressive pancytopenia, diverse congenital anomalies and increased predisposition to malignancy(1). The high frequency of spontaneous chromosomal aberrations probably leads to a high incidence of malignancies in these patients and their relatives. This paper presents the clinico-hematological features and cytogenetic analysis in all patients with FA alongwith family studies.

Material and Methods

During October, 1988 to December, 1989, eleven patients with FA were diagnosed at the Medical Oncology Department of the Tata Memorial Hospital. The following hematological investigations were carried out. A complete hemogram including reticulocyte count, serum iron and iron binding capacity; hemoglobin electrophoresis and HBF estimation; sickling test, osmotic fragility, acid hams test and sucrose lysis test whenever indicated. Bone marrow (BM) aspiration and biopsy specimens were processed for routine examination. Cytochemical staining, immunophenotyping using a panel of monoclonal antibodies for Myeloid markers–My-7, My-9 covering various lineages was done whenever indicated.

Every patient was subjected to routine biochemical profile, radiological investigations including complete skeletal survey, ultrasonography of the abdomen and intravenous pyelography and psychological evaluation to determine the intelligent and developmental quotients.

Cytogenetic Studies

Chromosomal preparations were made in bone narrow (BM) and phytohemag-

glutinin (PHA) stimulated cultured peripheral blood lymphocytes. The chromosomal aberration studies were carried out on aceto-arcein or giemsa stained metaphases. Achromatic regions less than a chromatid in width were analysed as gaps. For the chromosomal pattern and constitutional karyotype, Trypsin-Giemsa banding method was performed on BM metaphases and PHA stimulated peripheral blood lymphocyte mitoses, respectively. A total of 20-30 mitoses and a minimum of 10 metaphases were scored for chromosomal aberration analyses and for the detection of karyotype constitution, respectively.

Results

Salient features of the cases and their family members are provided in *Table I*. The age at diagnosis ranged from 2-13 years with a male predominance. There were three families with affection of more than 1 family member (cases 1 & 3, 5, 6 & 10, 11) Consanguinous marriage was noticed in two instances.

The clinical presentation was usually insiduous with progressive pallor and weakness, 2 children presented with infection, and bleeding tendency was seen in 4. Only 1 child (Case 7) presented with lymphadenopathy and organomegaly. Almost all patients had constitutional anomalies which included growth retardation in 7 cases, microcephaly in 8, hyperpigmentation in 6 and musculoskeletal anomalies in 8. The commonest musculoskeletal anomalies involved the thumb; 2 patients had bifid thumbs; 4 had hypoplastic thumbs with atrophy of thenar muscles; 2 of these had an extra osseous digit beneath. One patient had webbing of second and third toes. Ocular abnormalities in the form of microphthalmia, small palpebral fissures and squint were noticed in 5 cases. Hypogonadism was seen in one case. Case 3 had hypoplastic, ectopic and fused kidneys with double ureters whereas Case 8 had bilateral ectopic and hypoplastic kidneys.

The relevant laboratory features are given in *Table II*. Anemia and thrombocytopenia was present in all. Neutropenia (absolute neutrophil count <1000/cu mm) was seen in 7). Reticulocyte count was elevated in 4 patients, complete hemolytic work up, however was normal. Fetal hemoglobin level more than 2% was present in 6 patients, in three of them it was markedly increased. The first hematologic manifestation in Case 7 was ANLL (details of diagnosis provided in *Table I*). Chromosomal studies were performed in all patients (*Table III*). The constitutional karyotype of all FA cases and their relatives exhibited normal diploid pattern except Case 9 where an extra E-group marker, more like chromosome No. 16 was seen in one of the twenty metphases (*Fig. 1*). The remaining 19 cells showed normal diploid pattern. The BM of the same patient did not show any chromosomal changes. The percentage mitoses showing aberrations was in the range of 20-100%. Among the various types of aberrations, chromatid breaks and gaps were most frequent, while dicentrics and exchanges were less common.

Therapy and Clinical Course

All the cases (except Case 7) received androgen therapy (oxymethalone in an average dose of 5 mg/kg) with or without additional steroids (prednisolone 0.5-1 mg/kg). Most of the patients showed good response, 3 showed moderate response and 1 patient failed to show any response. Two patients had ANLL. One of these developed leukemia 8 years following the

TABLE I—*Clinical Profile of 11 Patients with Fanconis Anemia*

No	Age (yrs) Sex	Affection of family members	Consan-guinity	MR	GR	Physical Features			Malformations		Family studies
						Micro-cephaly	Occular abnor-malities	Pigmen-tation	Musc skelt	G-U	
1	8 F	+	+	–	–	+	+	–	–	–	
2	5 F	+	+	–	–	+	+	–	–	–	Normal
3	3 M	+	+	+	–	–	–	–	+	+	
4	10 M	–	–	–	–	–	–	+	+	–	Not done
5	13 M	+	–	+	+	+	+	+	+	+	Sibling and mother normal. Fathor showed chromosomal aberrations. No anemia or congenital defects.
6	9 M	+	–	+	+	+	+	+	+	–	
7	7 M	–	+	–	+	+	+	–	–	–	Case or AML-M_o, Other family members normal
8	9 M	+	–	+	+	+	+	–	+	+	Father short stature & microcephaly. No anemia, other family members normal.
9	19 M	–	–	–	+	+	–	+	+	–	Family members normal
10	2 F	+	–	+	+	+	–	+	+	–	2 sisters with phenotypic and chromosomal abnormalities. Elder brother and parents normal.
11	5 F	+	–	+	+	+	–	+	+	–	

+ Positive, – Negative, MR= Mental retardation; GR= Growth retardation; GU = Genito-Urinary malformations; AML-M_o = Acute myeloid leukemia; M_o = Variety where cytochemistry is normal and myeloid leukemia is detected by electron microscopy.

TABLE II–*Hematological parameters of the patients with FA at Initial Presentation*

No	Hb (g/dl)	Tc (× 10/L)	ANC (/cmm)	Platelets (× 10/L)	Retic (%)	HBF (%)	BM Asp.	BM biopsy
1	10.0	5.6	3000	84.0	3.5	1.2	Hypo	Hypo
2	8.0	4.9	2800	20.0	0.9	2.5	Hypo	Hypo
3	6.8	13.0	5600	85.0	1.1	3.5	Hypo	Hypo
4	3.2	1.3	250	9.0	0.1	2.5	Hypo	Hypo
5	7.3	4.9	750	29.0	1.14	11.4	Hypo	Hypo
6	9.0	7.8	858	26.0	2.7	17.0	Hypo	Hypo
7	7.0	29.9	150	85.0	0.3	9.8	ANLL	Hyper
8	8.6	2.3	850	50.0	0.9	16.0	Hypo	Hypo
9	10.0	3.7	1200	50.0	3.1	14.0	Hypo	Hypo
10	7.7	6.3	1000	30.0	2.1	13.4	Hypo	Hypo
11	12.0	9.5	1200	40.0	1.2	1.5	Hypo	Hypo

Hypo = Hypoplastic; Hyper = Hypercellular;
ANLL = Acute Nonlymphoblastic Leukemia.

TABLE III–*Chromosomal Aberrations in Patients with Fanconi's Anemia*

No	Age/Sex (yrs)	No. of mitoses analysed	% Mitoses with aberrations	Aberrations seen				
				Breaks	Gaps	Dicentrics	Exchanges	Karyotype constitution
1	8 F	30	100	28	5	4	3	16, XX
2	5 F	20	80	15	4	–	1	16, XX
3	3 M	35	0	–	–	–	–	16, XY
4	10 M	30	100	15	6	6	5	16, XY
5	13 M	20	100	26	6	–	1	16, XY
6	9 M	25	100	30	8	–	–	16, XY
F*	42 M	20	30	5	2	1	–	16, XY
7	7 M	20	25	3	1	1	–	16, XY
8	9 M	20	20	3	1	–	–	16, XY
9	19 M	20	80	13	4	–	–	16, XY
10	2 F	20	80	12	5	–	–	16, XY
11	5 F	20	40	25	7	–	–	16, XY

F* = Father of cases 5 & 6.

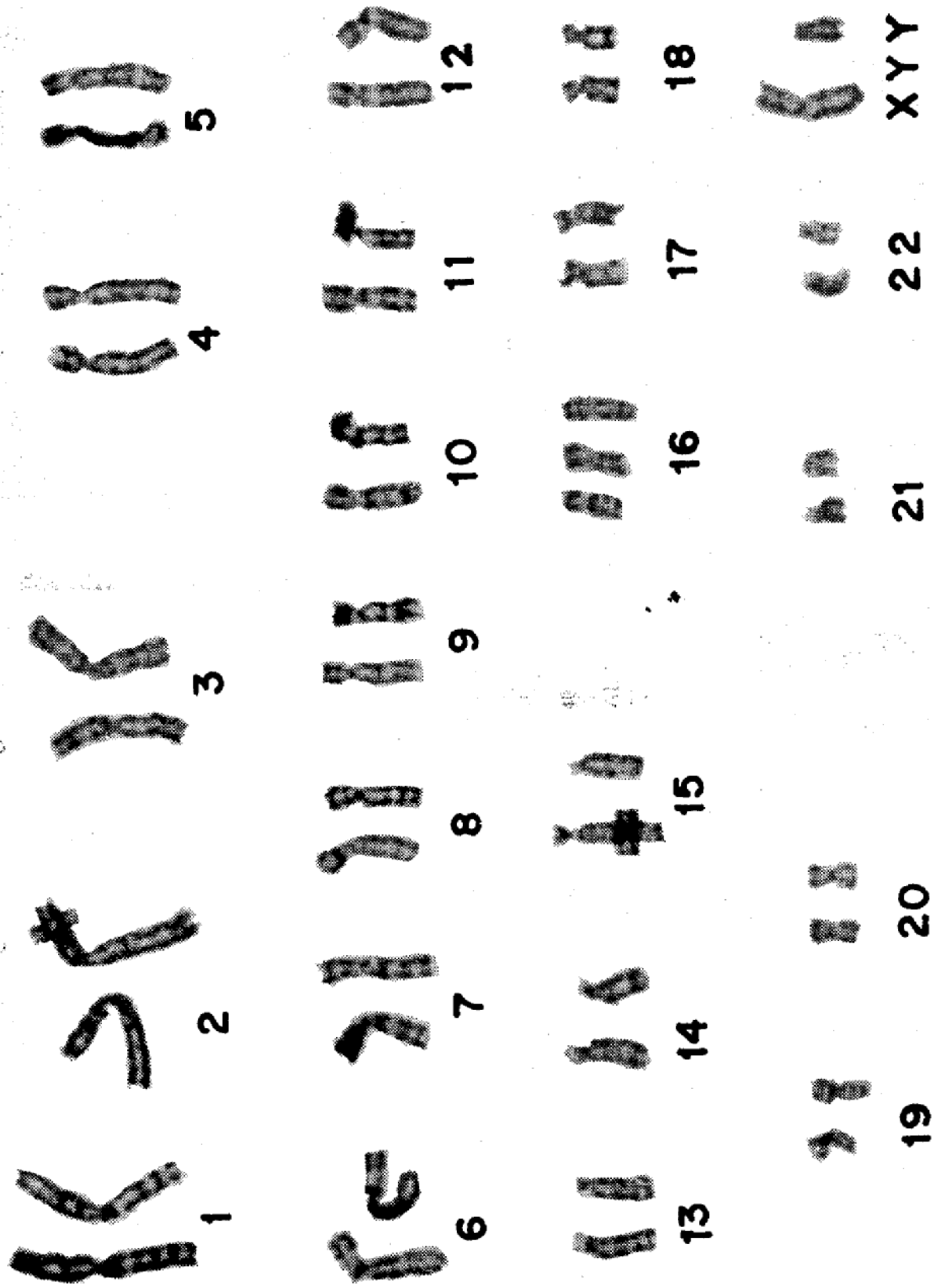

Fig. 1. A G-Banded karyotype from PHA-simulated PB lymphocytes showing extra E-group marker chromosome.

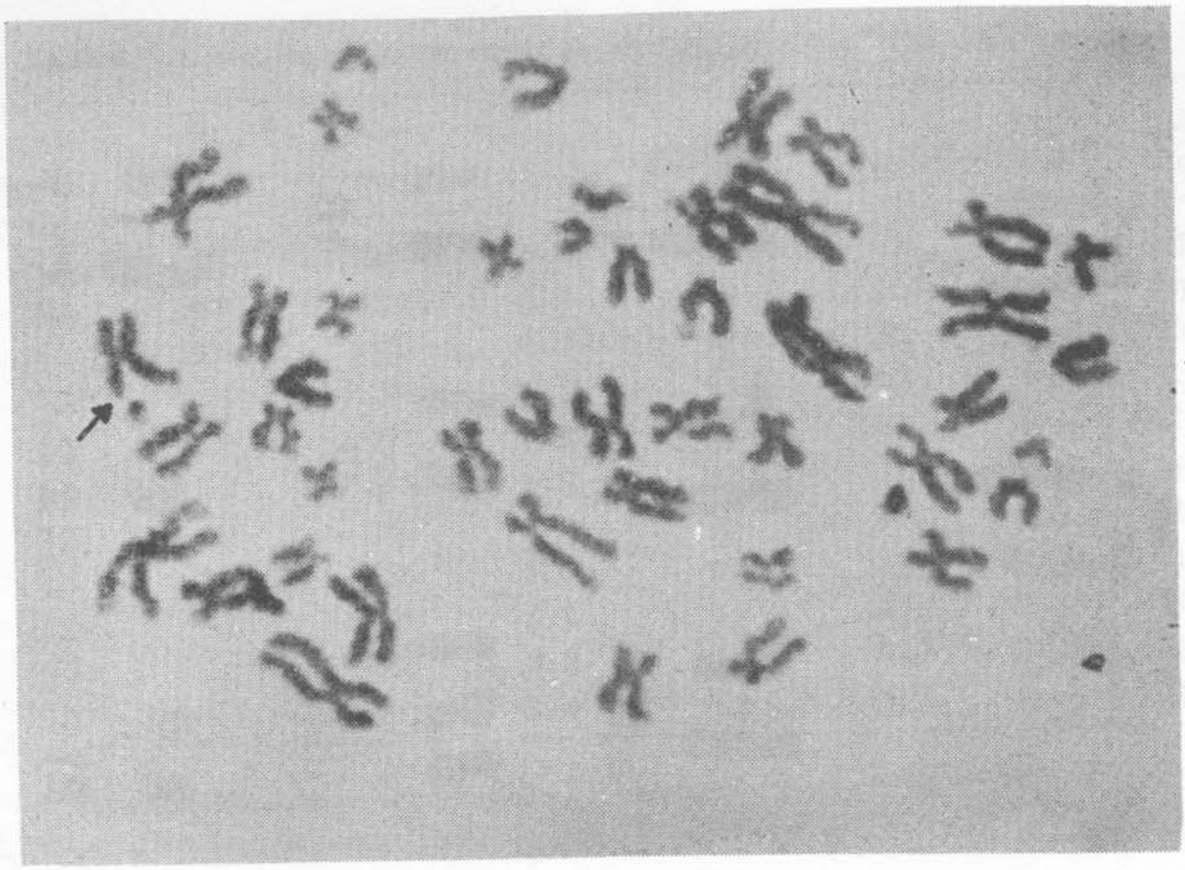

Fig. 2. A metaphase spread from the bone marrow showing a chromatid break

hypoplastic phase and succumbed to severe sepsis before chemotherapy could be instituted. The other child had ANLL as the first hematological manifestation. He received aggressive induction therapy with 50% reduction of doses comprising cytosine arabinoside, doxorubicin and VP-16. The cytopenia following chemotherapy was prolonged and he achieved complete remission for eight months followed by relapse. The average duration of follow up is 38.6 months (range 6-96 months). Case 1 died due to sepsis, Case 4 dropped out of therapy but the rest are well and alive (*Table IV*).

Discussion

Fanconi first described this disorder in 1927. Uehlinger proposed the term "familial hypoplastic pancytopenia" and it was Naegli in 1931, who popularized the eponym "Fanconi's anemia"(1). The frequency of occurrence of FA is estimated to be 1 in 360,000 but only 300 cases have been reported(1).

In the present series, consanguinity was seen in 2 cases. About 10-20% of the families with FA have consanguinous marriages(1). Amongst the reported families with FA, in 70% only 1 member is affected while in 30% there were at least 2 affected members(2).

Although there are no clear examples of parent child transmission, the inheritance pattern is autosomal recessive. In complete expression of homozygosity or heterozygous state may manifest as physical abnormalities, leukemias, diabetes mellitus with or without associated marrow

TABLE IV—*Response to Therapy and Outcome in 11 Patients with Fanconi's Anemia*

Case No	1	2	3	4	5	6	7	8	9	10	11
Therapy given	OXY PRED	OXY PRED	OXY PRED	OXY —	OXY PRED	OXY PRED	ANLL INDN	OXY PRED	OXY —	OXY PRED	OXY PRED
Resp.	++	+	+	—	++	+	++	—	++	+	+
Malign.	+++	—	—	—	—	—	++	—	—	—	—
Follow Up (months) Upto Dec.'89	96	40	36	10	40	20	8	12	90	6	6
Outcome	DEAD	AL	AL	LFU	AL	AL	AL	AL	AL	AL	AL

— means no response; — — oxypred not given; + means moderate response; ++ good response; +++ presence of malignancy; AL alive; OXY oxymethalone; PRED prednisolone; LFU lost to follow up.

The present series supports the hypothesis that FA is a heterogenous disorder with autosomal recessive inheritance; the underlying chromosomal aberrations making these patients more susceptible to malignant transformation and myelotoxic effect of chemotherapeutic drugs. Androgen therapy gives a high rate of response. In view of the variant clinical features, overlap presentation between other constitutional anemias and increased sensitivity to mutagenic agents needing therapeutic modification, we stress the importance of accurate diagnosis of FA.

REFERENCES

1. Fanconi G. Familial constitutional panmyelocytopathy: Fanconi's anemia. 1. Clinical aspects. Semin Hematol 1967, 4: 233-240.
2. Gastearena J, Giralt M, Orue MT, Oyarzabal FJ. Fanconi's anemia: Clinical Study of 6 cases. Am J Pediatr Hematol Oncol 1986, 8: 173-177.
3. Alter BP, Potter NV, Li FP. Aplastic anemia. *In:* Blood Diseases of Infancy and Childhood Vth edn. Eds Miller DR, O' Reilly RJ. St. Louis, The C.V. Mosby Co., 1984, pp 522-554.
4. Auerbach AD, Weiner MA, Warburton D, *et al*. Acute myeloid leukemia as the first hematologic manifestation of Fanconi's anemia. Am J Hematol 1982, 12: 289-300.
5. Bloom GE, Warner S, Gerald PS. Chromosomal abnormalities in constitutional aplastic anemia N Eng J Med 1966, 274: 8-14.
6. Rogers PCJ, Desai F, Karabus CD, Haretley PS, Fisher RM. Presentation and outcome of 25 cases of Fanconi's anemia. Am J Pediatr Hematol Oncol 1989, 11: 141-145.
7. Berger R, Bernheim A, Le Coniat M, Vecchione D, Schaison G. Chromosomal studies of Leukemic and pre-leukemic Fanconi's anemia patients. Human Genet 1980, 56: 59-62.
8. Pushpa V. Fanconi's constitutional panmyelopathy. Indian J Pediatr 1987, 54: 775-778.
9. Auerbach AD, Adler B, Chagani RSK. Prenatal and post natal diagnosis and carrier detection of Fanconi's anemia by a cytogenetic method. Pediatrics 1981, 67: 128-135.
10. Auerbach AD, Rogatko A, Schroeder KTM. International Fanconi's Anemia Registry: Relation of clinical symptomis to diepoxy butane sensitivity. Blood 1989, 73: 391-396.
11. Gluckman E, Berger R, Dutreix, J. Bone marrow transplantation for Fanconi's anemia. Semin Hematol 1984, 21: 20-26.