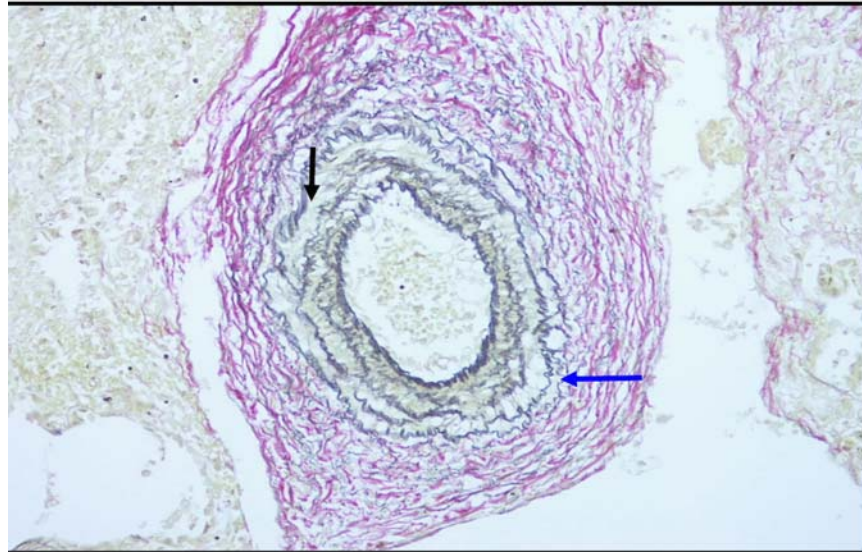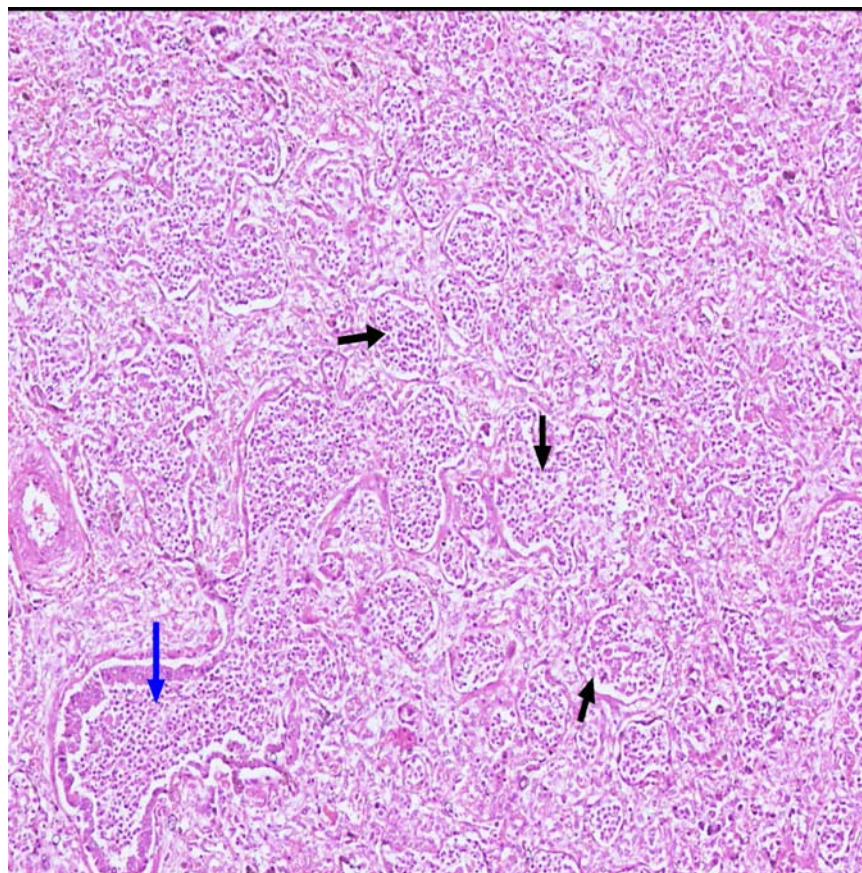
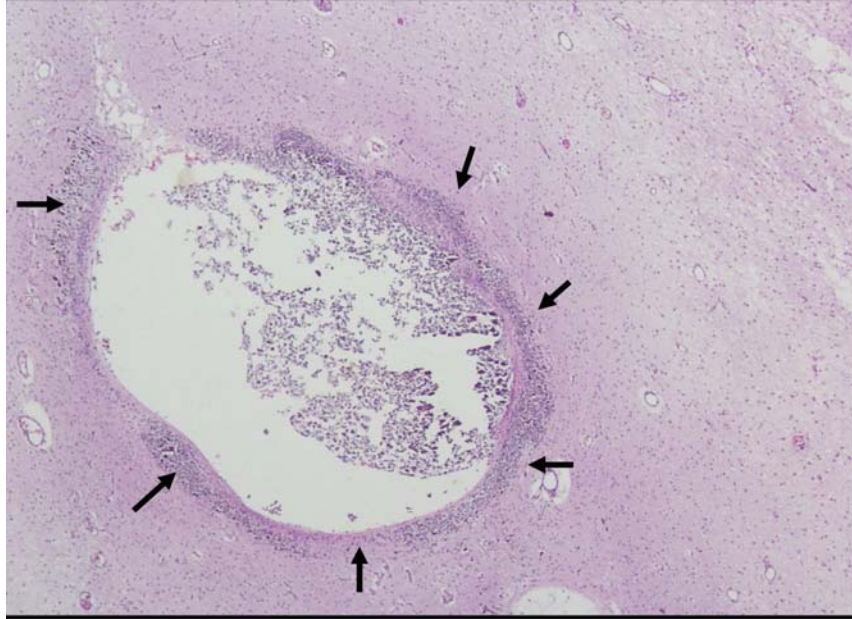


Web Fig. 1 Photomicrograph from intra-acinar pulmonary artery showing intimal thickening, reduplication of internal elastic lamina and adventitial thickening (Elastic von Gieson $\times 400$).



Web Fig. 2 Photomicrograph from focus of bronchopneumonia showing polymorphs and lymphocytes in bronchiole and adjacent alveolar spaces (H&E $\times 100$).



Web Fig. 3 Photomicrograph showing focal areas of calcification in perivascular spaces of white matter (H&E $\times 100$).