

Evaluating Neonates With Antenatal Hydronephrosis Using a Standard Protocol: An Audit of Hospital Records

RAMESH BABU¹, BINU NINAN² AND VENKATA SAI³

From Departments of ¹Pediatric Urology, ²Neonatology and ³Radiology, Sri Ramachandra University, Porur, Chennai, India.

Correspondence to: Dr Ramesh Babu,
Professor of Pediatric Urology, Sri
Ramachandra University, Porur,
Chennai 600 106, India.

drrameshbabu1@gmail.com

Received: July 20, 2017;

Initial review: November 20, 2017;

Accepted: June 02, 2018.

Aims: To audit the extent of evaluation of neonates with antenatal hydronephrosis. **Methods:** Records of all neonates with antenatal hydronephrosis between January 2013 and December 2016 were audited to look for patient factors and investigation results. **Results:** 290 records were evaluated, 93 (32%) of which had abnormalities detected on voiding cystourethrogram. In the presence of hydroureter, 65% had an abnormality while in the absence only 11% were abnormal. In the presence of pelvis ≥ 20 mm, 93% had abnormal diuretic renogram, while with pelvis < 20 mm, only 1.5% were abnormal ($P=0.001$). Numbers needed to harm calculation revealed 1 in 2 patients would receive an unnecessary voiding cystourethrogram in the absence of hydroureter, and unnecessary diuretic renogram when pelvis < 20 mm. **Conclusions:** While evaluating neonates with antenatal hydronephrosis invasive tests can be limited, if evaluation is guided by ultrasonographic criteria.

Keywords: *Diagnosis, Radioisotope renography, Vesico-ureteric reflux.*

Published online: June 02, 2018. PII: S097475591600122

With the advent of fetal ultrasound, antenatal hydronephrosis is being diagnosed frequently. Studies [1-7] have shown that fetal vesico-ureteric reflux (VUR) is too benign a condition to warrant an invasive voiding cysto-urethrogram (VCUG). The revised guidelines published by the Indian Society of Pediatric Nephrology (ISPN) recommend a VCUG to be performed in all patients with unilateral or bilateral hydronephrosis with renal pelvic antero-posterior diameter (APD) > 10 mm, hydronephrosis of Society for Fetal Urology (SFU) grade 3-4, or ureteric dilatation [8]. We audited the hospital records over a four-year period of following ISPN recommendations, and assessed the utility of invasive tests like VCUG in neonates with antenatal hydronephrosis.

METHODS

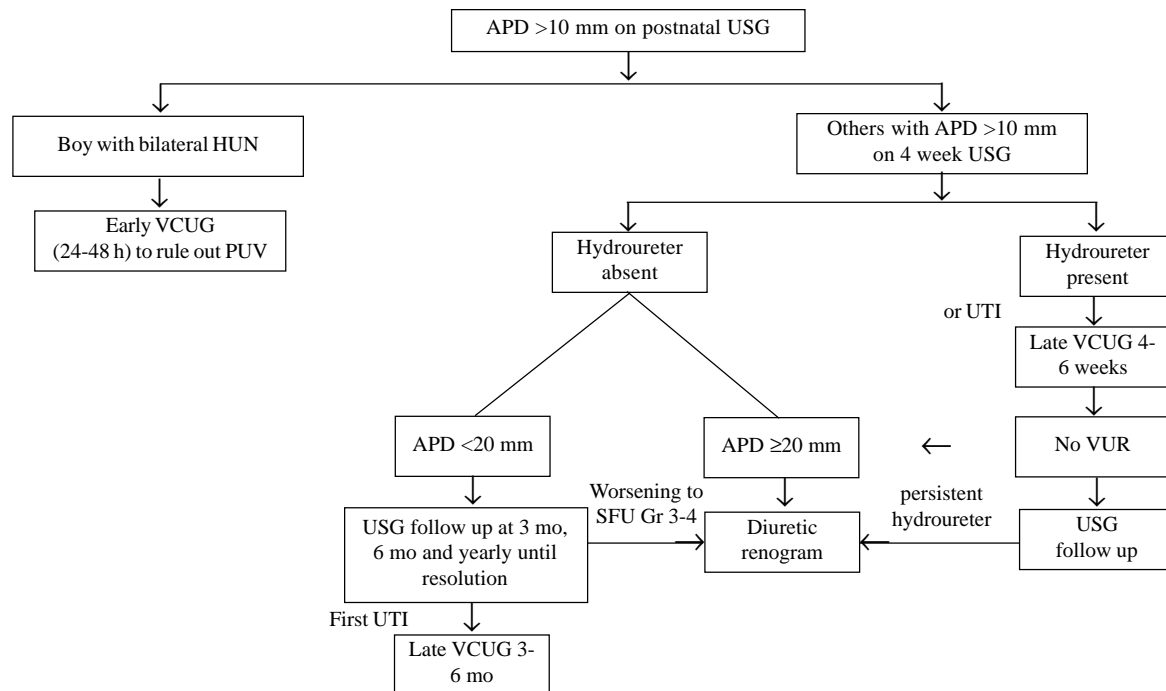
Records of all neonates who presented with antenatal hydronephrosis between January 2013 and December 2016 were evaluated. These neonates had been managed with a uniform protocol as per ISPN [8]. Records were audited to look for the patient gender, ultrasound factors (unilateral/bilateral, presence/absence of hydroureter) and radiological findings on VCUG (abnormal/normal). Treatment data were obtained from records to identify significant abnormalities that warranted medical or surgical treatment.

Those who were detected to have posterior urethral valves (PUV) on early VCUG underwent cystoscopic fulguration after stabilization. Those diagnosed to have VUR on late VCUG were started on continuous antibiotic prophylaxis. In the remaining, a Diuretic renography was performed at 6-8 weeks of life to assess renal function and drainage; those with persistent obstructive pattern and reduction in split renal function underwent surgical intervention.

APD from initial USG was correlated with diuretic renography findings to determine mean APD in those with obstruction. APD value, two standard deviation below the mean was used to determine how many could have avoided diuretic renography. Based on the findings, Numbers Needed to Harm (NNH) was calculated. Statistical analysis was performed using Fisher's exact test and P value less than 0.05 was considered significant.

RESULTS

Among 310 neonates evaluated for antenatal hydronephrosis over the 4 year period, after excluding those with incomplete record, a total of 290 were evaluated (180 males; bilateral 130) (**Fig. 1**). The median (range) follow-up was for 2 (1-4) years. All the patients underwent VCUG; 93 (32%) had abnormalities detected on VCUG. In boys with bilateral hydro-uretero-nephrosis, PUV was demonstrated in 100%. In the presence of bilateral hydronephrosis (without



VCUG – voiding cystourethrogram; APD – antero posterior diameter of renal pelvis; USG – ultrasonogram; HUN – hydroureteronephrosis; VUR – vesicoureteric reflux; PUV – posterior urethral valve; SFU – society of fetal urology.

FIG. 1 Algorithm (based on the present study) to limit invasive tests during post natal evaluation of neonates with fetal hydronephrosis.

hydroureter) only 24% had an abnormal VCUG. In the presence of unilateral hydronephrosis, only 5% had an abnormal VCUG and none warranted an intervention. Presence of hydroureter was significantly associated with an abnormal VCUG (65% vs 11%, $P=0.001$) (Table I).

All patients with normal VCUG ($n=197$) underwent Diuretic renography, and an obstructive pattern was identified in 60 (20.5%). The mean (SD) APD in those with obstructive pattern was significantly higher than in

those without obstruction [26 (2.9) vs 14 (2.5) mm; $P=0.001$]. Obstructive pattern was significantly more common in those with $APD \geq 20$ mm [93.5% vs 1.5%, $P=0.001$] (Table I). The two patients with $APD < 20$ mm remained stable without any need for surgery, and 43 (74%) of those with $APD \geq 20$ mm had drop in split renal function and underwent a pyeloplasty.

One in two patients would be harmed by the unnecessary voiding cystourethrogram in the absence of hydroureter and unnecessary diuretic renogram when $APD < 20$ mm. A total of 11/290 (3.8%) encountered problems related to VCUG (hematuria 4, dysuria 4, urinary retention 2, urosepsis 1) and 22/197 (11%) due to diuretic renography (multiple venous access 12, sedation issues 7, repeat study 3).

DISCUSSION

In this medical record review, we found that in the absence of hydroureter a chance of finding a significant abnormality (grade 3-5 VUR) in VCUG is 11%. Similarly in those with $APD < 20$ mm, the chance of finding a significant obstruction in Diuretic renography is only 0.5%.

Mears, *et al.* [3] felt a more conservative approach to the postnatal investigation of antenatal hydronephrosis did not result in any missed damaged kidneys. Erickson, *et al.*

TABLE I ASSOCIATION OF POSTNATAL ULTRASONOGRAPHIC FINDINGS AND INVASIVE INVESTIGATIONS IN ANTENATALLY-DETECTED HYDRONEPHROSIS

USG criteria	Voiding Cystourethrogram (n=290)	
	Abnormal	Not Abnormal
Hydroureter	73 (65%)	40 (35%)
No hydroureter	20 (11%)	157 (89%)
	Renogram Findings (n=197)	
	Obstructive pattern	No obstruction seen
$APD \geq 20$ mm	58 (93.5)	4 (6.5)
$APD < 20$ mm	2 (1.5)	133 (98.5)

All values in No. (%); APD: Antero-posterior diameter of renal pelvis; USG: Ultrasonography.

WHAT THIS STUDY ADDS?

- Ultrasonographic criteria (absence of hydroureter and APD <20 mm) could help in avoiding invasive tests like voiding cystourethrogram and diuretic renogram.

[13] reported that no cases of SFU III hydronephrosis have required surgery, whereas, only 50% of children followed conservatively required surgery in another report [14]. Lee, *et al.* [15] showed that by using ultrasonography criteria 63% VCUGs could have been avoided. The SFU guidelines have suggested an individualized approach, based on multiple sonographic factors like laterality, ureteric dilatation, bladder wall thickening and urethral dilatation [7].

On the basis of our findings we propose an algorithm (**Fig. 1**) to limit the number of invasive investigations like VCUG or Diuretic renography in those with ANH. We suggest that those without hydroureter could be spared a VCUG unless they develop a UTI. Similarly, those with <20 mm APD, Diuretic renography is reserved for those with worsening hydronephrosis. One essential caveat in this recommendation is the availability of an experienced pediatric sonologist who can pick up a hydroureter or measure APD properly. This protocol is based on a single center data. Further larger studies covering multiple centers would be able to throw more light on the extent of evaluation required in neonates with antenatal hydronephrosis.

Contributions: RB conceived the study analyzed the results and prepared the manuscript; BN and VS helped in correcting the manuscript

Funding: None; *Competing interests:* None stated.

REFERENCES

1. Babu R, Sai V. Postnatal outcome of fetal hydronephrosis: Implications for prenatal counseling. *Indian J Urol.* 2010; 26:60-2.
2. Ansari MS, Ayyildiz HS, Jayanthi VR. Is voiding cystourethrogram necessary in all cases of antenatal hydronephrosis? *Indian J Urol.* 2009;25:545-6.
3. Mears AL, Raza SA, Sinha AK, Misra D. Micturating cystourethrograms are not necessary for all cases of antenatally diagnosed hydronephrosis. *J Pediatr Urol.* 2007;3:264-7.
4. Yeung CK, Godley ML, Dhillon HK, Gordon I, Duffy PG, Ransley PG. The characteristics of primary vesico-ureteric reflux in male and female infants with pre-natal hydronephrosis. *Br J Urol.* 1997;80:319-27.
5. Marra G, Barbieri G, Dell'Agnola CA, Caccamo ML, Castellani MR, Assael BM. Congenital renal damage associated with primary vesicoureteral reflux detected prenatally in male infants. *J Pediatr.* 1994;124:726-30.
6. Pauchard JY, Chehade H, Kies CZ, Girardin E, Cachat F, Gehri M. Avoidance of voiding cystourethrography in infants younger than 3 months with *Escherichia coli* urinary tract infection and normal renal ultrasound. *Arch Dis Child.* 2017; 102:804-8.
7. Nguyen HT, Herndon CD, Cooper C, Gatti J, Kirsch A, Kokorowski P, *et al.* The Society for Fetal Urology Consensus Statement on the Evaluation and Management of Antenatal Hydronephrosis. *J Pediatr Urol.* 2010;6: 212-31.
8. Sinha A, Bagga A, Krishna A, Bajpai M, Srinivas M, Uppal R, *et al.* Revised Guidelines on Management of Antenatal Hydronephrosis. *Indian Pediatr.* 2013;50: 215-31.
9. Arora S, Yadav P, Kumar M, Singh SK, Sureka SK, Mittal V, *et al.* Predictors for the need of surgery in antenatally detected hydronephrosis due to UPJ obstruction - A prospective multivariate analysis. *J Pediatr Urol.* 2015;11:248.e1-5.
10. Passerotti CC, Kalish LA, Chow J, Passerotti AM, Recabal P, Cendron M, *et al.* The predictive value of the first postnatal ultrasound in children with antenatal hydronephrosis. *J Pediatr Urol.* 2011;7:128-36.
11. Onen A, Jayanthi VR, Koff SA. Long-term follow-up of prenatally detected severe bilateral newborn hydronephrosis initially managed nonoperatively. *J Urol.* 2002;168:1118-20.
12. Farhat W, McLorie G, Geary D, Capolicchio G, Bägli D, Merguerian P, *et al.* The natural history of neonatal vesicoureteral reflux associated with antenatal hydronephrosis. *J Urol.* 2000;164:1057-60.
13. Erickson BA, Maizels M, Shore RM, Pazona JF, Hagerty JA, Yerkes EB, *et al.* Newborn Society of Fetal Urology grade 3 hydronephrosis is equivalent to reserved percentage differential function. *J Pediatr Urol.* 2007;3:382-6.
14. Chertin B, Pollack A, Koulikov D, Rabinowitz R, Hain D, Hadas-Halpren I, *et al.* Conservative treatment of ureteropelvic junction obstruction in children with antenatal diagnosis of hydronephrosis: lessons learned after 16 years of follow-up. *Eur Urol.* 2006;49:734e8.
15. Lee RS, Cendron M, Kinnamon DD, Nguyen HT. Antenatal hydronephrosis as a predictor of postnatal outcome: A meta-analysis. *Pediatrics.* 2006;118:586-93.