

Role of Chest X-ray in Predicting Outcome of Acute Severe Pneumonia

BHAVNEET BHARTI, LADBANS KAUR AND SAHUL BHARTI

From Civil Hospital, Rohru, Shimla, Himachal Pradesh, India.

Correspondence to : Dr Bhavneet Bharti, Assistant Professor, Advanced Pediatric Center, Postgraduate Institute of Medical Education and Research, Chandigarh 160 012, India.

E-mail: bhavneetb@yahoo.com

Manuscript received: July 18, 2007; Initial review completed: October 1, 2007;

Revision accepted: March 14, 2008.

ABSTRACT

Objective: Radiological appraisal in children with clinically diagnosed severe pneumonia and its association with clinical outcome. **Design:** Prospective. **Setting:** Civil Hospital in Himachal Pradesh. **Patients:** Eighty-three children hospitalized with severe pneumonia. **Results:** Lobar consolidation (n=43, 51.8%) was the most common radiological abnormality. Twenty six (31.3%) had interstitial abnormalities and 14(16.9%) had normal chest radiographs. Clinical characteristics at admission could not predict a radiographic abnormality. Time to defervescence for outcome measures of fever and tachypnea was similar in children with consolidation, interstitial pneumonia or normal radiograph. However, length of hospital stay was significantly longer in children with abnormal chest radiographs on univariate analysis. **Conclusion:** Radiological findings in hospitalized children with clinically defined severe pneumonia have limited value in predicting clinical improvement.

Key words: Children, Pneumonia, Radiology, Respiratory Infection.

INTRODUCTION

Traditionally, guidelines classify children with pneumonia into phenotypic subtypes based mainly on the distribution of tachypnea and lower chest indrawing in a community setting(1). Nonetheless, radiological evaluation is invariably at the forefront when a clinician encounters a child with suspected pneumonia in the hospital. Most of the radiological studies in pneumonia have focused on epidemiologic, diagnostic and etiological perspectives. The evaluation of clinical outcome measures (time to defervescence of fever and tachypnea) has been infrequently taken into account *vis-à-vis* underlying type of radiological abnormalities(2-4). Given the paucity of data about clinical-radiological interface of pneumonia in resource constrained settings, this study aimed to identify easily observable respiratory

features or patient characteristics that were associated with radiological abnormalities and, to evaluate the role of chest radiography in determining the clinical outcome (time to defervescence) of acute severe pneumonia.

METHODS

All consecutive children, mostly 5 years or below, hospitalized with severe pneumonia were prospectively evaluated throughout their length of stay in hospital. Children having duration of illness >2 weeks or predominant wheezing were excluded. Patients were enrolled between May 1997 and June 1998 at a Civil Hospital (Tehsil Rohru, district Shimla) serving a catchment area of approximately 100 villages in Himachal Pradesh, India and caring for 200 to 300 patients per day (with pediatric

Accompanying Editorial: Pages 889-890

patients constituting at least 1/3rd of daily outpatient attendance). The diagnosis of severe pneumonia was based on either WHO criteria for children aged 5 years or less(1) or typical auscultatory signs of pneumonia in older children (only 5 patients). All children were subjected to chest radiography if feasible. Nutritional status was expressed as z scores for weight-for-age using reference median values of healthy Indian children. Clinical evidence of rickets was recorded if at least two of the following criteria were found: widening of wrists, rachitic rosary, box shaped head with frontal bossing, pectus deformity of chest, and abnormally wide or open anterior fontanel.

Two clinical researchers recorded the history and physical findings, clinical course and resolution of symptoms and signs throughout the length of stay in hospital. An experienced radiologist, unaware of clinical findings, reported on all the chest radiographs. The three mutually exclusive radiographic groups were defined as follows: (i) unequivocal focal or segmental consolidation with or without pleural effusion; (ii) interstitial pneumonia with diffuse bronchovascular markings with or without hilar lymphadenopathy; and (iii) normal chest radiographs. Descriptive and graphic analyses were used to analyze means, standard deviations, and normality of data. Non parametric tests (Mann Whitney U test and Kruskal Wallis test) for quantitative data, and Chi-square and Fisher exact test for categorical data were used.

RESULTS

115 consecutive children, aged 2 months to 10 years, hospitalized with severe pneumonia were prospectively evaluated. Radiographic investigation could be carried out only in 90 children. Seven chest radiographs were further excluded from this study (4 suboptimal and 3 wrongly labeled). The mean (+SD) age of remaining 83 children was 1.9(±1.6) years (median age 1.25 years, range 3 months to 7.3 years); 43(51.3%) were male. Chest radiographs were reported as normal in 14(16.9%); lobar consolidation was observed in 43(51.8%) including one empyema and two small pleural effusions; and 26(31.4%) had interstitial pneumonia with diffuse and prominent bronchovascular markings. Perihilar

prominence and/or hilar lymphadenopathy occurred in 20(24.1%) cases. Three children with consolidation had typical air bronchogram patterns and one infant presented with hyperinflation as well. The lobar consolidation ($n=43$) occurred on right side in 26(60.5%), left side in 9(20.9%) while remaining 8(18.6%) children had bilateral consolidation. Similarly, of 26 children with interstitial abnormalities on chest radiographs, 18(69.2%) had diffuse bilateral picture, 2(7.7%) with predominantly left side involved while remaining 6(23.1%) had predominantly right-sided involvement.

When demographic and clinical characteristics of children with severe pneumonia were stratified by their groups of radiographic findings (normal, lobar consolidation and interstitial pneumonia), no significant differences were observed for the various characteristics among different radiographic groups (**Table I**). There was only a trend for significance in the occurrence of normal chest radiographs in infants (10/39, 25.6%) as compared to children above one year of age (4/44, 9.3%) ($P=0.07$). Of the remaining 29 infants with severe pneumonia, 18 (46.2%) had consolidation while 11(28.2%) had interstitial radiographic abnormalities. Duration of illness after onset of respiratory symptoms till hospitalization was not significantly different between those with normal and abnormal chest radiographs. However, those with lobar consolidation showed a marginal trend in presenting earlier (5.2 ± 2.2 days) than those with interstitial radiographic findings (6.7 ± 3.8 days) ($P=0.07$). Moreover clinical characteristics and outcome measures did not differ statistically between right sided ($n=26$) vs. left sided ($n=9$) lobar consolidation. Chest radiographic findings were further analyzed on the basis of vaccination status in affected children. A completely vaccinated child in current study received only conventional vaccines that are routinely provided in a primary health care setup. None of the vaccinated children received newer vaccines for *H. influenzae* or Pneumococcus. Out of 28 children with nil or incomplete vaccination status, 67.9% had lobar consolidation and 14.3% had diffuse interstitial pneumonia. In contrast, only 43.6% of completely vaccinated children had lobar consolidation while 40% had diffuse interstitial

TABLE I DEMOGRAPHIC VARIABLES, AND SYMPTOMS AND SIGNS OF RESPIRATORY ILLNESS IN CHILDREN WITH SEVERE PNEUMONIA STRATIFIED BY THEIR CHEST X-RAY FINDINGS

	Chest X-ray findings		
	Normal (n=14)	Lobar consolidation (n=26)	Interstitial pneumonia (n=43)
Quantitative variables (mean ± SD)			
Age (yrs)	1.4±1.3	2.2±1.8	1.6±1.3
Duration of fever (d)	5.0±3.5	4.5±1.8	5.3±3.6
Duration of cough (d)	4.7±3.4	4.5±3.1	5.4±3.6
Prior treatment duration (d)	1.6±1.9	1.2±1.4	2.0±2
Duration of illness on admission (d)	5.7±3.1	5.3±2.2	6.8±3.8
Day of illness when fever became continuous (d)	1.5±2.3	1.3±1.7	1.2±2.3
Day of illness when fever became high grade (d)	1.6±2.4	2.1±2.4	1.8±2.2
Duration of anorexia (d)	3.3±2.2	2.9±1.8	3.6±2.4
Respiratory rate/min	67±12	65±15	66±13
Heart rate/min	145±14	140±18	141±12
Length of stay in hospital (d)	4.9±2.6	7.3±2.8	6.3±2.6
Qualitative Variables [n (%)]			
Severe lower chest indrawing (n=26)	2 (14.3%)	17 (39.5%)	7 (26.9%)
Grunting present (n=31)	8 (57.1%)	15 (34.9%)	8 (30.8%)
Inability to drink (n=15)	4 (28.6%)	7 (16.3%)	4 (15.4%)
Rickets (n=36)	4 (28.6%)	18 (41.9%)	14 (53.8%)
Weight for age Z score above -2 (n=51)	5 (35.7%)	27 (62.8%)	16 (61.5%)
Passive smoking (parents+domestic) (n=54)	8 (57.1%)	31 (72.1%)	15 (57.7%)

pneumonia ($P=0.04$). The radiological findings also lacked any statistical relationship with various clinical outcome measures (**Table II**). On the other hand, clinical signs of severe pneumonia were significantly related to outcome measure of tachypnea defervescence after start of therapy. Mean duration of tachypnea to subside after admission was significantly longer in those children with severe tachypnea at admission (Spearman correlation $r=0.48$, $P<0.001$), severe lower chest indrawing ($P=0.03$), and grunting ($P=0.03$). Radiographic abnormalities showed significant univariate association with length of hospital stay (**Table II**). Malnutrition prevalence was high in our study cohort; 57% children having weight for age below -2 Z score (based on median references of Indian Children) and rickets affected slightly less than half of (43.4%) enrolled children. Defervescence of

tachypnea demonstrated a trend for delayed resolution in children with weight for age Z score below -2 ($P=0.05$) as well as presence of rickets ($P=0.06$). This was more pronounced in children with abnormal chest radiographs (**Fig. 1 a,b**).

DISCUSSION

Chest radiography has carved a vital and inevitable niche in the management of childhood pneumonia, particularly in developed countries. Though optimized for epidemiological use, radiographic reference standards in pediatric pulmonary infections are yet nebulous for use in direct clinical care(5-7). Moreover, little is known about the link between key radiological attributes to clinical defervescence outcomes in childhood pneumonia in resource constrained settings(2,8). The current study, therefore, is one such study conducted in

TABLE II CLINICAL OUTCOME MEASURES STRATIFIED BY CHEST RADIOGRAPHIC FINDINGS

Variables*	CXR [†]	N**	Mean±SD (days)	P value
Fever started decreasing	1	13	1.8±0.8	0.68
	2	39	2.0±1.0	
	3	19	2.0±0.5	
Fever became passive (<37.5°C)	1	13	3.1±1.4	0.44
	2	37	3.9±1.9	
	3	18	3.8±1.4	
Tachypnea started decreasing	1	13	2.0±0.7	0.45
	2	39	2.0±1.0	
	3	19	2.4±1.2	
Tachypnea became passive	1	12	3.3±1.6	0.24
	2	38	4.5±2.4	
	3	19	4.4±1.9	
Duration of length of stay	1	14	4.3±2.5	0.01
	2	40	7.3±2.8	
	3	24	6.3±2.6	

* Duration of hospitalization when the variable occurred; [†]CXR (chest radiograph) 1 = normal, 2 = lobar consolidation, 3= diffuse interstitial; ** Only children with complete follow up data were included for analysis

hospitalized children with severe pneumonia detailing underlying radiological features and their association with clinical measures of defervescence. Our analysis highlights the premise that radiological landscape in pneumonia tends to have either extreme features to guide their clinicians (*e.g.* empyema or lobar consolidation with air bronchogram and effusion), or “completely masquerade radiologists” (with seemingly normal chest radiographs)(8-11). A well-defined lobar consolidation in 51.8% of cases in our study is an overarching indicator of severity of pneumonia and possible bacterial etiology(12-14). This finding is further supported by a review of 59 studies where a bacterial cause was confirmed in over 50% of cases by lung tap(15). Still, normality of chest radiographs in 16.9% of children with severe pneumonia leaves one second-guessing about their “rule in” utility, particularly in infants. Infants accounted for 71.4% of normal chest radiographs (10/14) in our study cohort. Anecdotal evidence suggests this as typical of early phase of pneumonia presenting with fever and tachypnoea before chest radiographic changes are seen(9,16). Moreover, the abnormal radiological appearance is often difficult to define especially in infants with inflammatory lung illness where hyperinflation may be the only radiological clue and features of the airspace

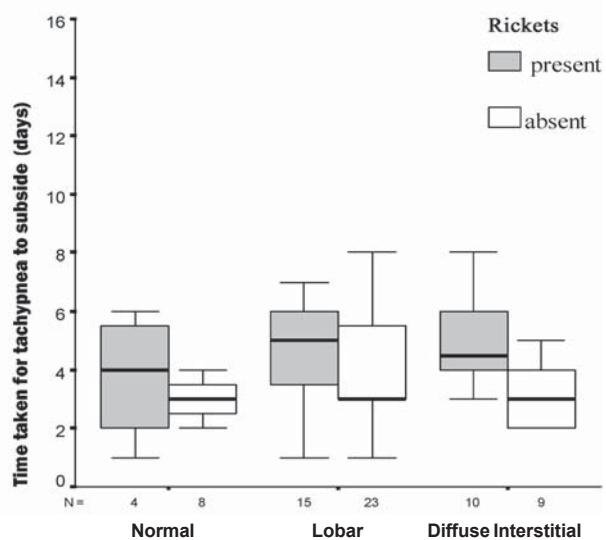
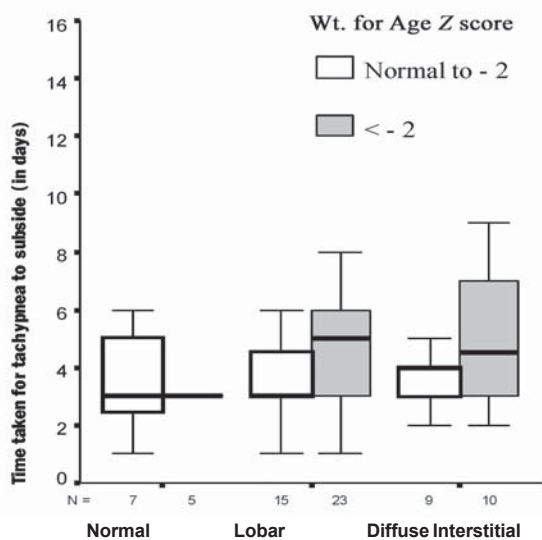


Fig. 1 (a) Tachypnea outcome of radiographic groups stratified by weight for age Z scores (b) Tachypnea outcome of radiographic groups stratified by rickets (present/absent).

WHAT IS ALREADY KNOWN?

- Routine chest radiography is not recommended in ambulatory children aged over 2 months with acute lower respiratory infections.

WHAT THIS STUDY ADDS?

- Radiological evaluation in hospitalized children with community acquired severe pneumonia in resource constrained settings has limited predictive ability for defervescence.

consolidation are lacking(17). Another interesting observation in our study was the higher distribution of radiological consolidation in non vaccinated or incompletely vaccinated children (68%) as compared to completely vaccinated children (44%), though the two vaccination groups did not vary in other confounding factors like malnutrition, rickets as well as severity of respiratory illness. There is already some epidemiological evidence of heterologous immunity and nonspecific protective effects of live vaccines against non-targeted infections particularly in high mortality areas(18).

The time to defervescence of fever and tachypnea did not differ depending on the type of underlying radiological findings in our study, though children with lobar consolidation and possibly bacterial etiology had significantly longer duration of hospital stay in our study. This is in contrast to the results of a study by Lin, *et al.*(19) where fever clearance took much longer duration in complicated lobar pneumonia as compared to uncomplicated lobar consolidation in children. This clinical recovery-radiological dissociation may however be due to lack of complicated lobar pneumonia cases in our study.

As regards the utility of chest radiographs, a randomized controlled trial by Swingler, *et al.*(20) had not favored the routine use of chest radiographs in ambulatory children aged over 2 months with acute lower respiratory infections when stratified further by WHO case definition of pneumonia. Similarly, our cohort study also echoes the inadequacy of radiological inputs in the recovery outcomes measures of hospitalized children with severe pneumonia and further endorses the WHO case management guidelines of using simple clinical signs to manage pneumonia in children in resource constrained settings, in developing countries.

We, however, consider that some caution is required before using our results in different settings especially due to lack of mortality and fewer complicated pneumonia cases in our study. Furthermore, the interpretation of chest radiographs by single radiologist could be another limitation of our study.

Contributors: BB was involved in designing the study and she will act as guarantor of the study. BB and SB were involved in data collection, analysis and manuscript writing. LK analyzed and interpreted the radiological data.

Funding: None.

Competing interests: None stated.

REFERENCES

1. World Health Organization. The management of acute respiratory infections in children. In: Practical Guidelines for Outpatient Care. Geneva: WHO; 1995.
2. Nacul LC, Kirkwood BR, Carneiro AC, Pannuti CS, Magalhaes M, Arthur P. Aetiology and clinical presentation of pneumonia in hospitalized and outpatient children in Northeast Brazil and risk factors for severity. *J Health Popul Nutr* 2005; 23: 6-15.
3. Don M, Fasoli L, Paldanius M, Vainionpaa R, Kleemola M, Raty R, *et al.* Aetiology of community-acquired pneumonia: serological results of a paediatric survey. *Scand J Infect Dis* 2005; 37: 806-812.
4. Michelow IC, Olsen K, Lozano J, Rollins NK, Duffy LB, Ziegler T, *et al.* Epidemiology and clinical characteristics of community-acquired pneumonia in hospitalized children. *Pediatrics* 2004; 113: 701-707.
5. World Health Organization Pneumonia Vaccine Trial Investigators Group. Standardization of interpretation of chest radiographs for the diagnosis

- of pneumonia in children. WHO document WHO/V&B/01.35 Geneva: WHO; 2001.
6. Cherian T, Mulholland EK, Carlin JB, Ostensen H, Amin R, Campo MD. Standardised interpretation of paediatric chest radiographs for the diagnosis of pneumonia in epidemiological studies. *Bull World Health Organ* 2005; 83: 353-359.
 7. Kiekara O, Korppi M, Tanska S, Soimakallio S. Radiological diagnosis of pneumonia in children. *Ann Med* 1996; 28: 69-72.
 8. Banajeh SM. Outcome for children under 5 years hospitalized with severe acute lower respiratory tract infections in Yemen: a 5 year experience. *J Trop Pediatr* 1998; 44: 343-346.
 9. Redd SC, Patrick E, Vreuls R, Metsing M, Moteetee M. Comparison of the clinical and radiographic diagnosis of paediatric pneumonia. *Trans R Soc Trop Med Hyg* 1994; 88: 307-310.
 10. Donnelly LF, Klosterman LA. The yield of CT of children who have complicated pneumonia and noncontributory chest radiography. *Am J Roentgenol* 1998; 170: 1627-1631.
 11. Kiekara O, Korppi M, Tanska S, Soimakallio S. Radiological diagnosis of pneumonia in children. *Ann Med* 1996; 28: 69-72.
 12. Virkki R, Juven T, Rikalainen H, Svedstrom E, Mertsola J, Ruuskanen O. Differentiation of bacterial and viral pneumonia in children. *Thorax* 2002; 57: 438-441.
 13. Grafakou O, Moustaki M, Tsofia M, Kavazarakis E, Mathioudakis J, Fretzayas A. Can chest X-ray predict pneumonia severity? *Pediatr Pulmonol* 2004; 38: 465-469.
 14. Korppi M, Kiekara O, Heiskanen-Kosma T, Soimakallio S. Comparison of radiological findings and microbial aetiology of childhood pneumonia. *Acta Paediatr* 1993; 82: 360-363.
 15. Vuori-Holopainen E, Peltola H. Reappraisal of lung tap: review of an old method for better etiologic diagnosis of childhood pneumonia. *Clin Infect Dis* 2001; 32: 715-726.
 16. Swingler GH, Zwarenstein M. Chest radiograph in acute respiratory infections in children. *Cochrane Database Syst Rev* 2008; 1: CD001268.
 17. Davies HD, Wang EE, Manson D, Babyn P, Shuckett B. Reliability of chest radiograph in the diagnosis of lower respiratory infections in young children. *Pediatr Infect Dis J* 1996; 15: 600-604.
 18. Shann F. Heterologous Immunity and the nonspecific effects of vaccines. A major medical advance? *Pediatr Infect Dis J* 2004; 23: 555-558.
 19. Lin CJ, Chen PY, Huang FL, Lee T, Chi CS, Lin CY. Radiographic, clinical and prognostic features of complicated and uncomplicated community-acquired lobar pneumonia in children. *J Microbiol Immunol Infect* 2006; 39: 489-495.
 20. Swingler GH, Hussey GD, Zwarenstein M. Randomised controlled trial of clinical outcome after chest radiograph in ambulatory acute lower-respiratory infection in children. *Lancet* 1998; 351: 404-408.