

Case Reports

Perforated Meckel's Diverticulum Causing Giant Pseudocyst and Secondary Appendicitis

Joseph John
Kamalesh Pal*
Vinod Prem Singh*

Meckel's diverticula are known to present with a myriad of complications. However its perforation followed by development of a giant pseudocyst and secondary appendicitis is not reported in literature thus far. We report this complication in a 5½-month-old infant.

Key words: *Meckel's diverticulum, perforation, pseudocyst, secondary appendicitis.*

Meckel's diverticulum was first described by Fabricius Hildanus in 1598 and was later named after Johann Friedrich Meckel, a German comparative anatomist who first recognized its developmental origin in 1809. In majority of patients the embryonic vitelline duct usually obliterates by the fifth to ninth week of intrauterine life but in about 2% of population however a vitelline remnant persists and may result in a variety of intra-abdominal complications(1). It is the most

From the: Departments of Pediatrics and Pediatric Surgery, Christian Medical College and Hospital, Ludhiana 141 008, Punjab, India.*

Correspondence to: Dr. Joseph John, Lecturer, Department of Pediatrics, Christian Medical College and Hospital, Ludhiana 141 008. E-mail drjj@rediffmail.com

*Manuscript received: September 26, 2005;
Initial review completed: November 9, 2005;
Revision accepted: April 24, 2006.*

common congenital anomaly of the gastrointestinal tract occurring in 1-3% of the population. Meckel's diverticula with or without a fibrous connection to the umbilicus account for 90% of all omphalomesenteric duct anomalies(3).

Case Report

A 5½-month-old male infant was admitted with complaints of fever for 7 days, vomiting, loose stools and abdominal fullness for 2 days prior to admission. Examination revealed an average built infant weighing 4.5 kg with mild pallor, tachycardia and tachypnea. His heart rate was 184/min, respiratory rate was 64/min and axillary temperature was 100°F. Abdominal examination showed mild fullness; liver was palpable 8cm below the right costal margin, it was tender, firm, the surface was smooth and the edge was not assessable. Percussion note over the liver was resonant and the bowel sounds were exaggerated.

An admitting diagnosis of hepatic abscess with septicemia and congestive cardiac failure was made. Investigations revealed Hb - 9.8 g/dL, TLC - 18300/mm³, DLC - P₇₀ L₂₈ M₂, MP - negative. An upright X-ray abdomen showed a hypodense area occupying the area of the liver. Ultrasonogram of the abdomen revealed a large hypoechoic cystic area with internal echoes within it, placed anterior to the liver having an approximate volume of 300 mL. This was confirmed by a CT scan.

Exploratory laparotomy revealed (i) a large pseudocyst in the peritoneal cavity containing frank pus; (ii) ruptured Meckel's diverticulum extruding bile and (iii) an inflamed appendix in the wall of the abscess

cavity. The abscess was drained and pus and peritoneal fluid sent for culture. A resection anastomosis, appendectomy and thorough peritoneal lavage was done.

The tissue biopsy confirmed the operative findings of a pseudocyst, secondary to a perforated Meckel's diverticulum with abscess formation and acute periappendicitis and subserositis. There was presence of ectopic gastric mucosa at the tip of the Meckel's diverticulum. Peritoneal fluid sent for culture showed 80000 WBC/mL with 60% polymorphonuclear cells and 40% lymphocytes. Pus, peritoneal fluid and stool cultures grew *E. coli* with identical sensitivity pattern though the blood culture did not show any growth.

The post-operative period was uneventful and the patient was discharged on the 17th hospital day. The baby is doing well at ten months follow up.

Discussion

Meckel's diverticulum is a true diverticulum because it arises from the anti mesenteric border of the small bowel, and contains all layers of the intestinal wall. Less than 5% of all Meckel's diverticula are symptomatic(4) though few like Mackey and Dineen(5) have reported a higher rate of 16.9% of symptomatic patients.

The male to female ratio 2:1 to 3:1 has been reported in literature(1,5,6). The position of the diverticulum is highly variable and although it has been reported as far proximal as the ligament of trietz, it is usually found within 100 cm of the ileo caecal valve(5). Ninety per cent are 1-10 cm long, but record lengths up to 100 cm have been reported(7,8). Approximately 50% contain heterotopic mucosa, of which, more than 60% contain gastric mucosa, 16% pancreatic acinar tissue,

and the remainder brunners glands, pancreatic islets, colonic mucosa, hepatobiliary tissue or a combination of tissues(9).

In neonates symptomatic lesions account for 85% of cases, in children aged 1 month to 2 years 77% of lesions are symptomatic while those more than 4 years only 15% are symptomatic(1). Ninety per cent of bleeding diverticula contain heterotopic mucosa. Bleeding is the predominant symptom of patients aged 1 month to 4 years of age (2,5) nearly always being caused by ulceration of the ileal mucosa adjacent to the acid producing gastric mucosa. Other complications include obstruction, intussusception, volvulus, perforation, strangulation due to a mesodiverticular band, Littre's hernia, diverticulitis and peptic ulceration of ileal mucosa(5). The rarer complications are foreign bodies in the diverticular lumen(5), subphrenic abscess(7) and tumors. Among tumors carcinoids are the commonest others include sarcomas, benign mesenchymal tumors and adenocarcinomas.

Although such a myriad of complications have been described, to the best of our knowledge this is the first case report of a perforated Meckel's diverticulum that has presented with a pre hepatic giant pseudocyst with secondary appendicitis. Our patient had an acute presentation with features of intra abdominal septic pathology confined to the right hypochondrium. Preoperative investigations were suggestive of an abscess anterior to the liver. Unusual site and sheer size of the abscess had caused a diagnostic dilemma. We encountered a mobile caecum and vermiform appendix involved in the pseudocyst with features of inflammation in the serosal and subserosal layers of the appendix akin to secondary appendicitis described by Nordbark and Matikainen(10).

CASE REPORTS

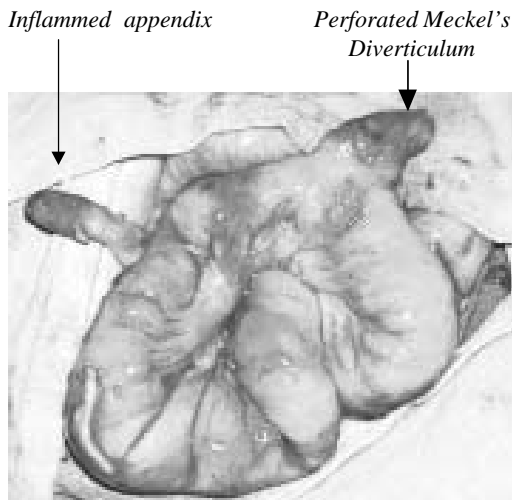


Fig.1. Intraoperative photograph showing the perforated Meckel's diverticulum and inflamed appendix.

Contributors: JJ was involved in the primary care of the patient, drafted the manuscript and will act as guarantor; KP and VPS were involved in the surgical management of the patient, provided the photographs, critically reviewed and corrected the manuscript.

Competing interests: None.

Funding: None.

REFERENCES

1. Vane DW, West KW, Grosfeld JL. Vitelline duct anomalies. *Arch Surg* 1987; 122: 542-547.

2. Turgeon DK, Barnett JL. Meckel's Diverticulum. *Am J Gastroenterol* 1990; 85: 777-781.

3. DiGiacomo JC. Surgical management of Meckel's diverticulum. *South Med J* 1993; 86: 671-675.

4. Mackey WC, Dineen P. A 50 year experience with Meckel's diverticulum. *Surg Gynecol Obstet* 1983; 156: 56-64.

5. Kusumoto H, Yoshida M, Takahashi I, Anai H, Maehara Y, Sugimachi K. Complications and diagnosis of Meckel's diverticulum in 776 patients. *Am J Surg* 1992; 164: 382-383.

6. Fa-Si-Oen PR, Roumen RMH, Croiset van Uchelen FAAM. Complications and management of Meckel's diverticulum: A review. *Eur J Surg* 1999; 165: 674-678.

7. Kundra R Wardhan H. Perforated Meckel's diverticulum presenting as subphrenic abscess. *Indian J Pediatr* 2001; 68: 353-354.

8. Moses WR. Meckel's diverticulum. Report of two unusual cases. *N Engl J Med* 1947; 237: 118-122.

9. Yamaguchi M, Takeuchi S, Awazu S. Meckel's diverticulum, investigation of 600 patients in the Japanese literature. *Am J Surg* 1978; 136: 247-249.

10. Nordbark I, Mati kainen M. Secondary appendicitis: A sign of some other intra-abdominal inflammation. *Ann Chir Gynecol* 1985; 74: 134-136.