

Seckel Syndrome with Polyarteritis Nodosa

Ramazan Kutlu
Alpay Alkan,
Onur Kutlu*
Cengiz Yakinci*

Seckel syndrome is a rare genetic disorder with a typical "bird-headed" appearance. It could affect many organ systems but renal involvement is uncommon. Polyarteritis nodosa is systemic vasculitic disorder which also involves kidneys. We report a case of Seckel syndrome in a 9 year-old boy with renal involvement due to polyarteritis nodosa. According to the literature, this is the first report of polyarteritis nodosa in Seckel syndrome.

Key words: *Polyarteritis nodosa, Seckel syndrome.*

Seckel syndrome is a rare autosomal recessive disorder characterized by proportionate dwarfism, delayed mental development, microcephaly and typical facial appearance(1-4). Renal involvement in this syndrome is quite rare(2). On the other hand, polyarteritis nodosa is also a rare, systemic necrotizing vasculitis of medium-sized arteries and frequently involves the kidneys, skin, joints, gastrointestinal tract and central and peripheral nervous system(5-8). Although aneurysms are regarded as classical angiographic findings in polyarteritis nodosa, there

are other non-aneurysmal angiographic findings that should also be considered in the diagnosis of polyarteritis nodosa.

We report a case of Seckel syndrome with cerebral infarct and severe hypertension whose investigations showed polyarteritis nodosa. To the best of our knowledge, polyarteritis nodosa in Seckel syndrome has not been reported previously.

Case Report

A 9-year-old boy with left arm and leg weakness of two weeks duration and difficulty in walking was admitted to our hospital. Six months ago, he had been diagnosed as having malignant hypertension and chronic renal insufficiency, and treated with enalapril, nifedipine and furosemide. Past medical history revealed low birth weight, mental and motor development delay and surgery for left club foot. His parents were second degree relatives. On physical examination the weight, height and head circumference were below the 3rd percentile. Micrognathia, malocclusion of the teeth, prominent "bird-like" nose, pes plana valgus and hallux valgus deformities were present (*Fig. 1*). Neurological examination showed 3/5 power, hyperactive deep tendon reflexes and positive Babinski sign on the left. Laboratory findings showed hemoglobin level of 7.9 g/dL, leukocytes 14,600/cu mm, urea nitrogen 87 mg/dL, creatinine 2.2 mg/dL, sodium 134 mEq/L, potassium 5.8 mEq/L, calcium 9 mg/dL, albumin 3.5 g/dL, uric acid 6.3 mg/dL and phosphate 5.6 mg/dL. Blood level of creatine kinase was 23 U/L (normal 0-172 U/L), C-reactive protein was negative and glomerular filtration rate was 14 ml/min. A detailed hepatitis B serology was negative and blood levels of proteins C and S normal. Serology for antinuclear cytoplasmic antibodies was negative. Urinalysis showed a specific gravity of 1020, pH 5, trace

From the Departments of Radiology and Pediatrics, Inonu University School of Medicine, Malatya, Turkey*

Correspondence to: Dr. Ramazan Kutlu, Department of Radiology, Turgut Ozal Medical Center, Inonu University School of Medicine, 44069 Malatya, Turkey. E-mail: rkutlu@inonu.edu.tr

Manuscript received: May 6, 2003;

Initial review completed: July 30, 2003;

Revision accepted: May 14, 2004.

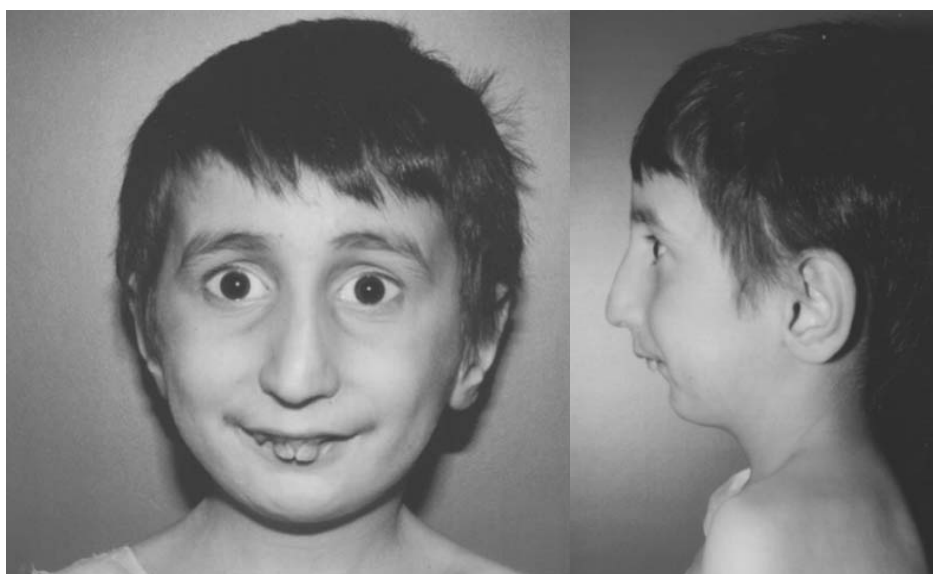

Fig. 1. Facial appearance of Seckel syndrome; note the micrognathia, malocclusion of the teeth, prominent "bird-like" nose.

proteinuria and 2-3 white cells/HPF. Echocardiography showed mitral insufficiency and left ventricle dilatation and hypertrophy. Glomerular filtration rate was calculated as 7% on DTPA examination. Electromyography was normal. Renal ultrasonography showed increased parenchymal echoes bilaterally. Cranial computed tomography examination showed infarct in the right frontal region and magnetic resonance angiography demonstrated irregular narrowing in right middle cerebral artery and right posterior cerebral artery. Cranial digital subtraction angiography examination revealed widespread narrowing, irregularity, especially prominent in middle cerebral artery and supraclinoid internal carotid artery. Mesenteric and renal angiography showed multiple small saccular aneurysms in the intrarenal branches of the right renal, lumbar and jejunal branch of superior mesenteric arteries and peripheral renal perfusion defects bilaterally (*Fig. 2*). On basis of the modified American College of

Rheumatology (ACR) classification criteria, he was diagnosed as having polyarteritis nodosa(8). Antihypertensive medications and oral prednisolone (1 mg/kg/day) were given, and hemodialysis initiated. After one month of treatment, no significant response to therapy was observed. Since the patient was lost to follow-up, other treatment options could not be performed.

Discussion

Seckel syndrome is an autosomal recessive condition without any sex predilection, with a incidence reported of 1:10,000 live-born children(3,4). Due to inconsistency in diagnosis, less than one-third of the reported cases appear to fulfil Seckel's original criteria(4). Low birth weight, microcephaly, proportionate short stature, moderate to severe mental retardation, secondary premature synostosis, retarded bone age, and characteristic facial anomalies, including receding forehead and chin, antimongoloid slant of the eyes, a

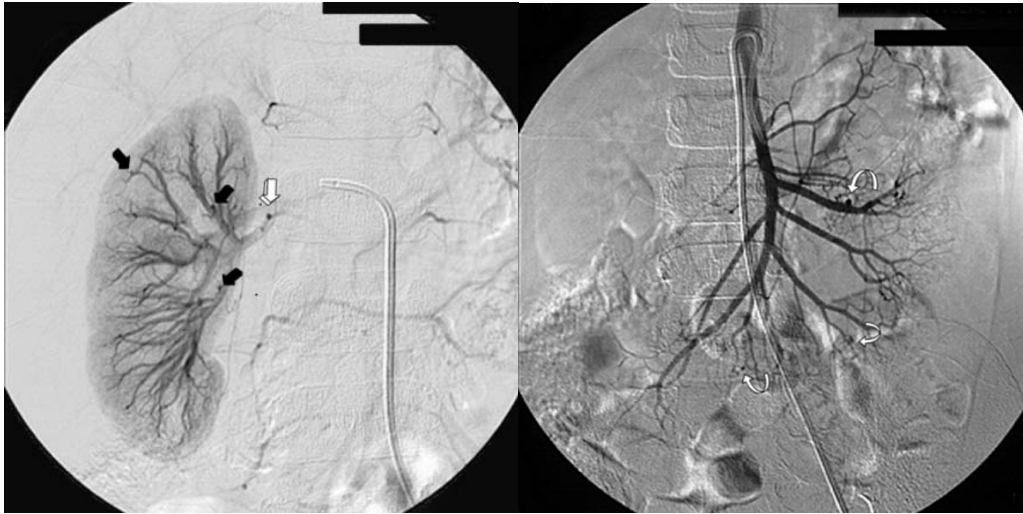


Fig. 2. Right renal artery (A) and superior mesenteric artery (B) injections show small saccular aneurysms in the intrarenal branches of the right renal (black arrows), lumbar (white arrow) and jejunal branch of superior mesenteric (curved arrow) arteries.

large and prominent beaked nose and large or bulging eyes, clinodactyly of the fifth finger, dislocation of the radial head, absent ear lobes, dental abnormalities, 11 pairs of ribs, receding hair and redundant wrinkled skin on the palms are characteristic(1-4). The present case had low birth weight, microcephaly, beaked nose, micrognathia, prominent upper jaw, developmental delay and mental retardation.

Polyarteritis nodosa is a rare, systemic necrotizing arteritis with nodules along the walls of medium and small muscular arteries(5,6,8). Polyarteritis nodosa affects multiple organ systems, most commonly kidneys, gastrointestinal tract, nervous system, muscles and soft tissue(5,7,8). There is a considerable overlap in the clinical features of vasculitides in childhood, therefore the epidemiology of polyarteritis nodosa is probably imprecise(5,8). Ozen, *et al.*(9) defined two major and ten minor criteria for identifying pediatric patients with polyarteritis nodosa. They suggest that in patients with five

of these 12 diagnostic criteria, especially those with renal involvement, therapy should be initiated promptly while diagnostic procedures are being carried out(9). Our case had one major (renal involvement) and five minor criteria (hypertension, leukocytosis, peripheral neuropathy, constitutional symptoms, central nervous system involvement). The original ACR criteria for polyarteritis nodosa in adults were modified to make the criteria applicable to children and related to definitions of weight loss, hypertension, and elevation of blood urea nitrogen and creatinine. The presence of three or more of the criteria defined a patient as having polyarteritis nodosa(8). In our case there were more than three of the required criteria (failure to thrive, leg tenderness and weakness, systemic hypertension, elevated urea nitrogen and creatinine, arteriographic abnormalities). Although tissue biopsy and visceral angiography are important diagnostic tools for polyarteritis nodosa, none of these has proved to be the gold-standard(8). Multiple aneu-

CASE REPORTS

rysms in various organs (typically kidney, liver and intestines), vessel narrowing and occlusion are the classic angiographic manifestations of polyarteritis nodosa, and more than two-thirds of all patients have positive abdominal arteriograms(5).

We could not find any biological basis for the association of Seckel syndrome and polyarteritis nodosa in the present case and therefore this could be coincidental recurrence of two rare conditions.

Contributors: RK, CY, AA and OK were involved in management of the patient. RK and AA prepared and CY and OK reviewed and edited the manuscript. RK will act as the guarantor of the paper.

Funding: None.

Competing interests: None.

REFERENCES

1. Guirgis MF, Lam BL, Howard C. Ocular manifestations of Seckel syndrome. *Am J Ophthalmol* 2001; 132: 596-597.
2. Sorof JM, Dow-Smith C, Moore PJ. Severe hypertensive sequelae in a child with Seckel syndrome (bird-like dwarfism). *Pediatr Nephrol* 1999; 13: 343-346.
3. D'Angelo VA, Ceddia AM, Zelante L, Florio FP. Multiple intracranial aneurysms in a patient with Seckel syndrome. *Child Nerv Syst* 1998; 14: 82-84.
4. Carfagnini F, Tani G, Ambrosetto P. MR findings in Seckel's syndrome: report of a case. *Pediatr Radiol* 1999; 29: 849-850.
5. Oran I, Memis A, Parildar M, Yuntun N. Multiple intracranial aneurysms in polyarteritis nodosa: MRI and angiography. *Neuroradiology* 1999; 41: 436-439.
6. Besbas N, Ozen S, Saatci U, Topaloglu R, Tinaztepe K, Bakkaloglu A. Renal involvement in polyarteritis nodosa: evaluation of 26 Turkish children. *Pediatr Nephrol* 2000; 14: 325-327.
7. Bakkaloglu SA, Ekim M, Tumer N, Tulunay O, Ozer T. Severe renal impairment in the case of classic polyarteritis nodosa. *Pediatr Nephrol* 2001; 16: 148-150.
8. Brogan PA, Davies R, Gordon I, Dillon MJ. Renal angiography in children with polyarteritis nodosa. *Pediatr Nephrol* 2002; 17: 277-283.
9. Ozen S, Besbas N, Saatci U, Bakkaloglu A. Diagnostic criteria for polyarteritis nodosa in childhood. *J Pediatr* 1992; 120: 206-209.