

- RB. London, Oxford University Press, 1982, pp 69-70.
2. Gupta MS, Mehta L, Malhotra S, *et al.* Jaccoud's arthritis. *J Assoc Phys India* 1990, 38: 947-948.
 3. Tatarkina ND, Dudidov AI, Liubarskaia DA. Postrheumatic Jaccoud's arthritis. *Reumatologica-Mosk* 1989, 1: 70-71.
 4. Joao-SR, Afonso MR, Martin Junior L, *et al.* Jaccoud's syndrome: A case report. *Arq-Bras-Cardioj* 1989, 53: 221-223.
 5. De-la-sota-M. Jaccoud's arthropathy in knees in systemic lupus erythematosus. *Maldonaclo-Cocco-ja Clin Rheumatol* 1989,8:416-417.
 6. Kahn-MF. Jaccoud's arthritis and urticarial hypocomplementic vasculitis. *J Rheumatol* 1989, 16: 252.
 7. Maher JM, Strosberg JM, Rowley RF, *et al.* Jaccoud's arthropathy and inflammatory bowel disease. *J Rheumatol* 1992, 19: 1637-1639.
 8. Biasi-D, Carletto A, Caramaschi P, *et al.* Jaccoud's postrheumatic arthritis. *Recenti-Prvg-Med* 1992, 83: 197-199.

Osteogenesis Imperfecta Type II in One of a pair of Twins

Girish Gupta
Praveen Kumar
Anil Narang

Osteogenesis imperfecta type II also called osteogenesis imperfecta congenita or Vrolik's disease is a rare connective tissue disease affecting 1 in 62,000 births(1). A

From the Division of Neonatology, Department of Pediatrics, Postgraduate Institute of Medical Education and Research, Chandigarh 160 012.

Reprint requests: Dr. Anil Narang, Additional Professor, Division of Neonatology, Department of Pediatrics, PGIMER, Chandigarh 160012.

*Received for publication: February 18, 1994;
 Accepted: June 30, 1994*

variety of biochemical defects in type I procollagen resulting in disruption of triple helical conformation and procollagen suicide are responsible for the clinical features(2). Some cases are autosomal recessivtf but many are new dominant mutations. A large majority of patients die in early neonatal period or infancy but the incidence in general population is kept constant as a result of new mutations. It has been estimated that the mutation rate in osteogenesis imperfecta is 4×10^{-5} per gene per generation(3). The occurrence of osteogenesis imperfecta in one of a pair of twins would be a rare chance association. On extensive review of literature we could come across only two such reports(4,5). The purpose of this communication is to describe our experience of such a case, emphasize the inclusion of long bone evaluation in the 'routine' antenatal ultrasound examination and raise the management dilemma posed by such a situation.

Case Report

Baby S, second of the twins, female

child was born to 29 years old third gravida by Cesarean section for nonprogress of labor at 37 weeks. Ultrasound examination at 26 weeks gestation had revealed twin pregnancy with two placentae and appropriately grown fetuses. Twin II weighed 1.6 kg and had Apgar scores of 4 and 8 at 1 and 5 minutes, respectively. Twin I was 2.23 kg male child with uneventful course.

On examination, the baby was symmetrically growth retarded, short limbed, dwarf. His length was 34 cm (<3rd centile) and the upper segment to lower segment ratio was 3.2. Head circumference was 33 cm (50th centile) while the chest circumference was 24 cm. He had a very soft skull with multiple wormian bones, large fontanelle, and prominent eye balls with blue sclerae. The limbs were short, thickened and deformed with multiple areas of crepitus over long bones and ribs. The thorax was narrow

and bell shaped (*Fig. 1*). With the diagnosis of osteogenesis imperfecta type II, the child was managed with oxygen and IV fluids because of respiratory difficulty but he succumbed at 41 hours of age.

Radiography revealed generalized osteopenia, multiple fractures of long bones and ribs giving the appearance of crumpled femora and beaded ribs, and multiple wormian bones in the skull (*Fig. 2*). Serum calcium was 9.8 mg/dl, inorganic phosphate 3.6 mg/dl and alkaline phosphatase was 30 IU/L. Cranial and abdominal ultrasound examination did not reveal any other malformations. The autopsy confirmed the presence of fractures and bony deformities.

The marriage was non-consanguinous and there was no history of frequent fractures in the family. The examination of the elder sibling and parents was normal. Skeletal surveys of the parent, elder sib and

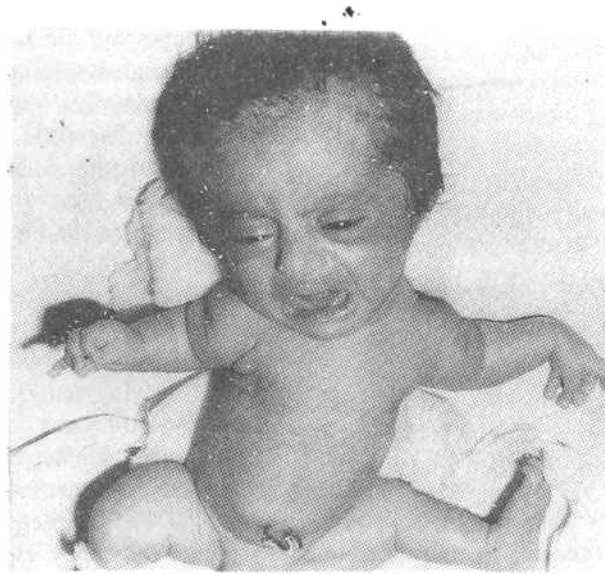

Fig. 1. Front view showing short, deformed limbs and narrow thorax.

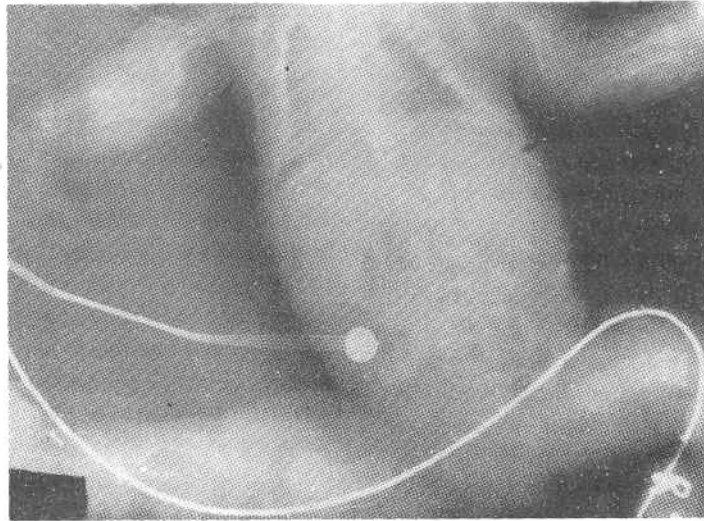


Fig. 2. Skeletal X-ray showing multiple fractures, crumpled femora and thoracic deformity.

first twin did not reveal any abnormality.

Discussion

Congenital anomalies in twins are generally discordant. This is true for both dizygotic and monozygotic twins. The concordance rates have varied from 3.6% to 18.8% in various studies(6). Even chromosomal anomalies are usually discordant in dizygotic babies and surprisingly, also occasionally in monozygotic twins as well. This is because the defect commonly occurs after the process of twinning is completed. In the index case, the absence of evidence of the disease in any of the parents and the discordancy in the pair of dizygotic twins obviously points towards a new mutation.

As osteogenesis imperfecta type II is a lethal condition, prenatal diagnosis is of paramount importance. The recurrence risk is estimated to be 6% in parental gonadal

mosaicism, though it would be much higher in the infrequently occurring autosomal inheritances(7,8). With refinement of ultrasonographic techniques, more and more skeletal dysplasias can now be diagnosed antenatally. Munoz *et al.*(9) have suggested a diagnostic triad of (a) marked femoral shortening <3 SD, (b) multiple fractures in single bone, and (c) demineralization of calvaria, to label a case as osteogenesis imperfecta on prenatal ultrasound examination. They even suggested that a negative study at 17 weeks excludes the diagnosis. In twin pregnancy, partly because one fetus lying anteriorly may limit the acoustic window and possible visualization of the same twin's parts twice, there are more chances of missing the diagnosis. In a review of 226 suspected cases of skeletal dysplasias Sharoney *et al.*(10) found that routine ultrasound examination between 16-24 weeks of gestation was the usual mode of

diagnosis. As the family history was positive only in 9.7% cases, these authors suggested that measurement of long bone size should be a part of the routine antenatal ultrasound examination. 'Routine' ultrasound examination, when one is not specifically looking for skeletal dysplasia is likely to miss the diagnosis as possibly happened in the index case. However, one should be careful not to make the diagnosis of skeletal dysplasia unless the bone lengths are less than 3 SD(9). Even Sharoney *et al.*(10) found a 7% false positive rate. Hence, they advised intrauterine X-ray should be done for confirmation of diagnosis in suspicious cases. DNA analysis and restrictive enzyme phosphorylation study of COL1A1 locus in fetal tissues is also being explored as a possible way of early fetal diagnosis(8).

Antenatally diagnosed osteogenesis imperfecta would warrant termination of pregnancy in a single fetus. However, in twins with only one affected fetus would pose a difficult management dilemma. As the occurrence of such an event itself is rare, no guidelines are available. Selective feticide has been performed for other genetic and structural anomalies like trisomy 21, Tay-Sachs disease, microcephaly, etc.(11). The other options available are abortion of both fetuses or continuation of the pregnancy. Continuing the pregnancy most often results in delivery of a normal baby along with an abnormal one who may be a tremendous familial and social burden; the abnormal twin may also jeopardize the normal fetus.

REFERENCES

1. Silience DO, Senn A, Danks DM. Genetic heterogeneity in osteogenesis imperfecta. *J Med Genet* 1979, 16: 101-116.
2. Prockop DJ, Chu M-L, DeWet W, *et al.* Mutations in osteogenesis imperfecta leading to the synthesis of abnormal type I procollagens. *Ann NY Acad Sci* 1985, 460: 289-297.
3. Luck JV. Bone and joint diseases: Pathology correlated with roentgenological and clinical features. Springfield IH, Charles C Thomas, 1950, p 384.
4. Levin EJ. Intrauterine osteogenesis imperfecta in one of a pair of twins. *Am J Roentgenol* 1965, 93L 405-407.
5. Morin LRM, Herlicoviez M, Loisel JC, Jacob B, Feuilly C, Stanescu V. Prenatal diagnosis of lethal osteogenesis imperfecta in twin pregnancy. *Clin Genet* 1991, 39: 467-470.
6. Little J, Bryan EM. Congenital anomalies in twins. *Semin Perinatol* 1986, 10: 50-64.
7. Young ID, Harper PS. Recurrence risk in osteogenesis imperfecta congenita. *Lancet* 1980, 1:432.
8. Byers PH, Starman BJ, *et al.* A novel mutation causes a perinatal lethal form of osteogenesis imperfecta. An insertion in one alpha 1 (I) collagen allele (COL1A1). *J Biol Chem* 1988, 263: 7855-7861.
9. Munoz C, Filly RA, Golbus MS. Osteogenesis imperfecta type II: prenatal-sonographic diagnosis. *Radiology* 1990, 174: 181-185.
10. Sharoney R, Browne C, Lachman RS, Rimoin DL. Prenatal diagnosis of skeletal dysplasias. *Am J Obstet Gynecol* 1993, 169: 668-675.
11. Cunningham FG, MacDonald PC, Gant NF. Multifetal pregnancy. *In: Williams Obstetrics*, 18th edn. London, Prentice-Hall International Inc. 1989, pp 649-650.