
Brief Reports

Diastrophic Dysplasia

A. Duraiswamy
S. Iyer
A.S. Kher
B.A. Bharucha

Diastrophic dysplasia is a rare form of short limbed dwarfism recognizable at birth which includes diastrophic dwarfism and diastrophic variant(1). We report a classic case of this form of short stature.

Case Report

A ten-month-old girl was assessed for short stature and club feet. She was born following an uneventful antenatal period of a non-consanguinous marriage. The child was noted to have short limbs and bilateral club feet at birth. The neonatal period was uneventful. Physiotherapy and operative correction was done for the deformity at 4 months after which partial correction was achieved. Except for mild delay in motor

From the Department of Pediatrics, Seth G.S. Medical College and K.E.M. Hospital, Parel, Bombay 400 012.

Reprint requests: Dr. B.A. Bharucha, Associate Professor of Pediatrics, Department of Pediatrics, K.E.M. Hospital, Parel, Bombay 400 012.

*Received for publication: December 8, 1993;
Accepted: April 29, 1994*

milestones, the child had been thriving well.

On examination, total length was less than third percentile for age. Bilateral rhizomelic shortening of the limbs was noted. A proximally placed, hypermobile thumb (hitch hiker thumb) was noted bilaterally (*Fig. 1*). Hard swellings in both pinnae with deformity; thoraco lumbar scoliosis to the left, limited elbow extension, hypermobile knee joints were additional clinical findings. The feet showed partial equinovarus deformity. The skeletal survey showed shortened tubular bones with metaphyseal widening and flattened femoral epiphyses; the hands showed deformed and short first metacarpals and four carpal bones in the wrist. The spinal X-ray showed scoliosis to the left in the thoraco lumbar vertebrae with apex at D12 level. There was no evidence of deafness, congenital heart disease or cleft palate. The parents and the elder sib were normal.

Discussion

Diastrophic dysplasia is a recessively inherited skeletal dysplasia caused by irregular chondrocyte distribution at the growth plate and fibrocystic changes in the matrix(1). There is wide variation in the phenotype including a lethal neonatal form(2) with respiratory distress, severe skeletal changes, congenital heart disease and high mortality. The classic non-lethal form includes less severe forms(3,4) with typical skeletal changes, better growth potential and variability in clinical features (previously segregated as the diastrophic variant) as well as the more typical phenotype (previously designated diastrophic dwarfism). Rhizomelic short stature and equino varus are noted at birth but scoliosis appears later.

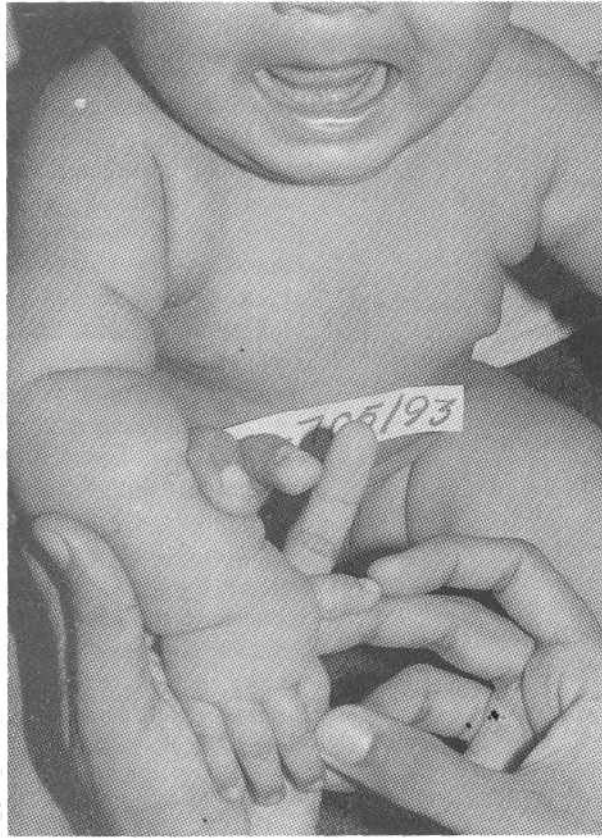


Fig. 1. Hand showing proximal, hypermobile "hitch hiker" thumb.

Our case had scoliosis at 10 months of age. The inflammatory cystic swelling of the pinna has its onset during neonatal period and heals with deformity and firm calcific swellings as was the case in our patient. The equinovarus deformity is notoriously resistant to therapy as borne out by the residual deformity in our case even with physiotherapy and surgery. Rarer malformations(1,3) include Robin anomalad, conductive deafness, cleft palate, heart disease, facial hemangioma, none were observed in our patient. Apart from the classical X-ray changes already described, selective delay

in femoral head epiphyseal appearance, paradoxical accelerated carpal bone age, calcified costal cartilage, stippled epiphyses and absent sciatic notches are also sometimes seen(1,5). Complications include spinal cord injury; motor delay; degenerative joint disease and progressive scoliosis. Prognosis for lifespan and intelligence is normal. Average adult heights are 88-128 cm for males and 105-123 cm for females(1). Antenatal diagnosis can be offered for the next pregnancy through ultrasound screening for abnormal thumb and short limbs(6).

Acknowledgement

The authors wish to thank the Dean, Dr. P.M. Pai for giving us permission to publish this article.

REFERENCES

1. Buyse ML. Birth Defects Encyclopedia, Oxford, Blackwell Scientific Publications, 1990, pp 533-535.
2. Gustavson KH, Holmgren G, Jagell S, Joralf H. Lethal and non-lethal diastrophic dysplasia: A study of 14 Swedish cases. Clin Gen 1985, 28: 321-334.
3. Jones KL. Smith's Recognizable Patterns of Human Malformation. Philadelphia, WB Saunders Co, 1988, pp 326-328.
4. Mehta L, Verma IC, Soni JP, Singhanian RU. Diastrophic dysplasia—A case report. Indian J Pediatr 1992, 59: 755-757.
5. Spranger JW, Langer LD, Weidmann HR. Bone dysplasias—Atlas of Constitutional Disorders of Skeletal Development, 1974, pp 102-107.
6. Gollop TR, Eigier A. Prenatal ultrasound diagnosis of diastrophic dysplasia at 16 weeks. Am J Med Gen 1987, 27: 321-324.

Thanatophoric Dysplasia

M.L. Kulkarni
C. Sureshkumar
V. Venkataramana
Samuel Koshy
M. Bhagyavathi
G. Shekhar Reddy

Thanatophoric dwarfism (TD) literally meaning death seeking dwarf is the most common form of lethal bone dysplasia and is characterized by severe micromelia and other malformations.

From the Department of Pediatrics, J.J.M. Medical College, Davangere 577 004, Karnataka.

Reprint requests: Prof. M.L. Kulkarni, 2373, M.C.C "A" Block, Davangere 577 004, Karnataka.

*Received for publication: December 12, 1993;
 Accepted: May 2, 1994*

TD has an estimated prevalence of 0.28 to 0.60 per 1000 births(1). In Indian literature, a few isolated cases are described(2). In this report we describe five cases of thanatophoric dwarfism picked up during a period of 2 years. Four cases were out of 13,244 births (five births + still born) in 3 hospitals attached to medical college, Davangere (3 per 10,000 births) and the other case was delivered outside but was brought to our hospital in gasping state and later died. In one case an antenatal diagnosis was made. The rarity of the disorder and the information regarding the prevalence during our period of study, prompted us to report these cases.

Case Reports

Case I: A 24-year-old, healthy, non-consanguineously married woman with history of one previous abortion was brought to the hospital at 22 weeks of gestation for antenatal evaluation. The pregnancy was reported uneventful. Ultrasound examination showed a single live fetus, and amniotic fluid was adequate. Biparietal diameter of the fetus was corresponding to 22 weeks of