

**OSTEOMA OF THE TONGUE:
A RARE CAUSE OF UPPER
AIRWAY OBSTRUCTION**

Mohd. Maqbool
Rafiq Ahmad
Rauf Ahmad

Osteomas of the tongue arising in the dorsum near the region of foramen of cecum and varying in size from a "pea" to "cherry" have been reported in the literature and almost all the cases occurred in females(1). From review of literature, we could not find an osteoma larger than a "cherry" in size. The case being reported here is unique not only in size but also in its location, *i.e.*, arising from the vallecula.

Case Report

An eight-year-old female child presented with history of nocturnal choking leading to repeated arousals from sleep and failure to thrive, for six months duration. Dysphagia, recurrent cough and fever were other associated symptoms. There was no history of pain or constitutional symptom or trauma. On examination, the child was of thin built. Systemic examina-

tion was normal except for occasional crepitation on both sides.

Oral examination revealed a large, smooth surfaced, non-tender hard mobile swelling at the back of the tongue (*Fig. 1*). Indirect laryngoscopy was not possible as the swelling obscured the view. X-ray soft tissues of the neck revealed a large rounded radio-opaque shadow in the region of vallecula extending above the level of the epiglottis. The laryngotracheal air column was normal (*Fig. 2*). With hard consistency and radiographic appearances,

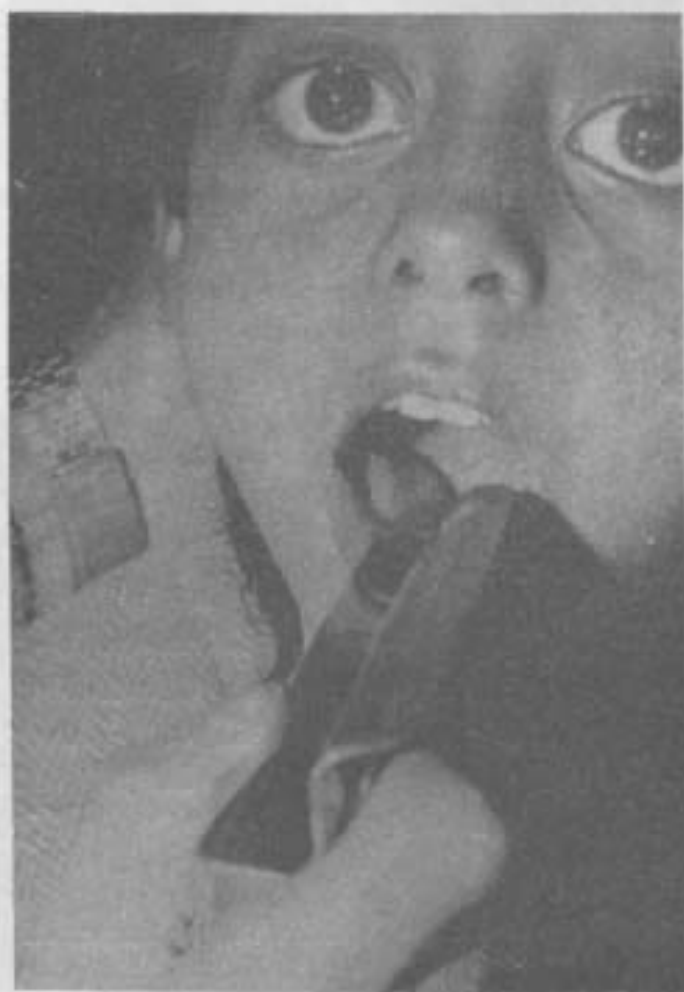

Fig. 1. Clinical photograph of the patient showing the large pedunculated osteoma at the base of the tongue.

*From the Department of Otorhinolaryngology,
Government Medical College, Srinagar
190 010, Kashmir.*

*Reprint requests: Dr. Rauf Ahmad, 177,
Nursing Garh, Srinagar 190 010, Kashmir.*

Received for publication: December 20, 1991;

Accepted: May 20, 1992

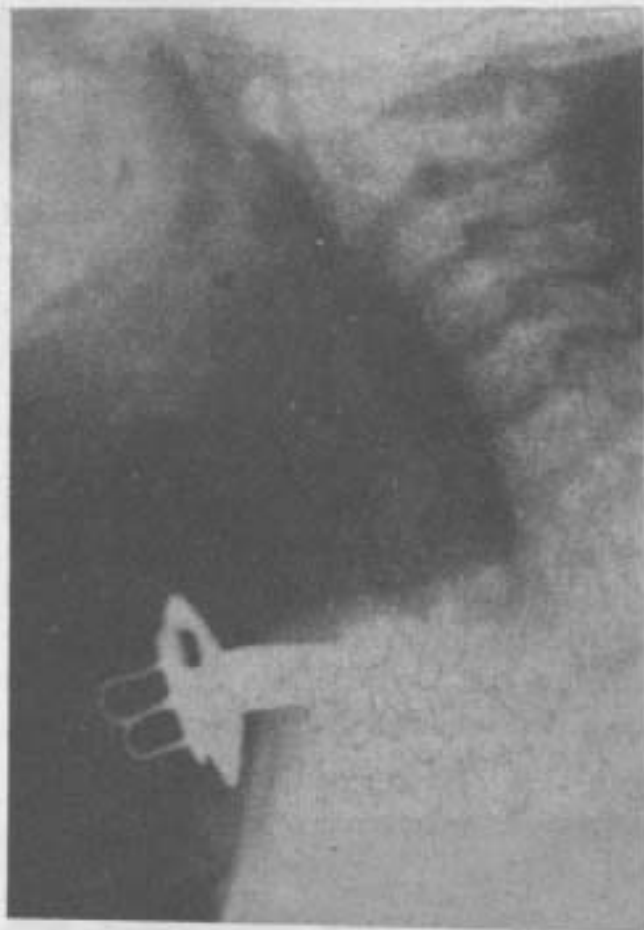


Fig. 2. X-ray soft tissues neck showing large radio-opaque shadow in the region of vallecula. The shadow in the prevertebral region is due to surgical emphysema secondary to tracheostomy.

a provisional diagnosis of osteoma of tongue was made. As the swelling was large and obscured the view of the larynx on direct laryngoscopic examination, a preliminary tracheostomy was necessary for anesthetizing the patient.

On examination under anesthesia, the swelling was found to be arising from the right vallecula with a solitary peduncle. The tumor measured 4 cm \times 5 cm and was excised completely using anterior pharyngotomy approach. The post-operative period was uneventful and the tracheostomy was closed subsequently.

Histopathology of the tumor showed metaplastic bone and was diagnosed as osteoma (*Fig. 3*).

Discussion

Bony and cartilagenous lesions of the tongue have been divided into two groups(1). The first group is comprised of predominantly osteoid growths that occur in the posterior midline of the tongue almost exclusively in females. The second group which has a more random sexual dis-

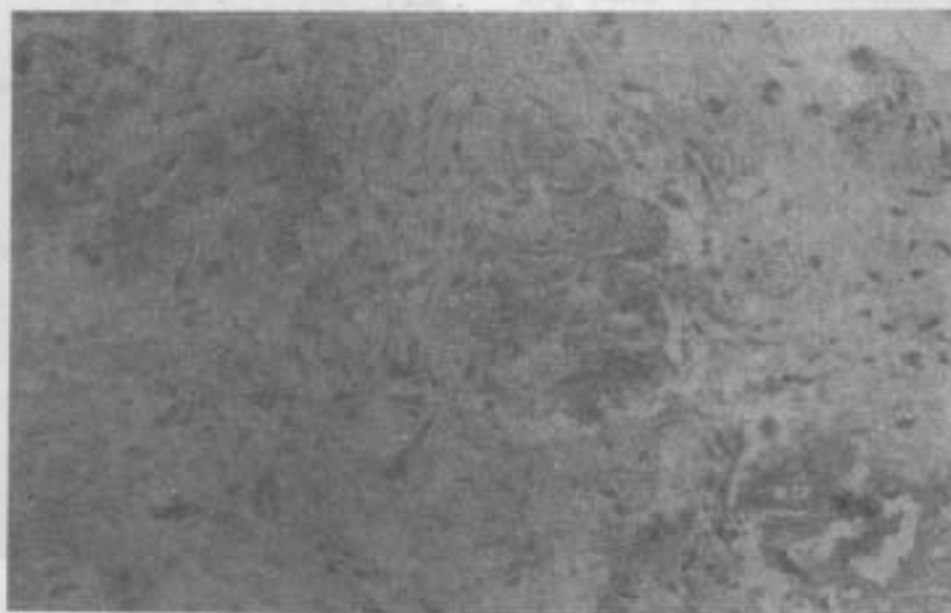


Fig. 3. Photomicrograph showing metaplastic bone surrounded by granulation tissue (H & E \times 400).

tribution is found in the anterior or lateral part of the tongue and contains both bone and cartilage usually more of the latter.

The etiopathogenesis of such tumors is not clear. It has been postulated(1-3) that ectopic embryonic rests of pleuripotential mesenchyma in the region of foramen of cecum give rise to such lesions. Another possibility suggested is the post-traumatic mesenchymal metaplasia(4) which results in osteochondroid growths usually in the anterior part of the tongue.

The present case seems to be congenital in origin and seems to fit better in the former category as in this location other developmental anomalies presenting in the pediatric age group also occur, viz., thyroglossal cysts and ectopic thyroid tissue. The large size and location of the present lesion coupled with the normal relaxation of pharyngeal musculature during sleep was responsible for the airway obstruction and attacks of apnea during sleep. This was confirmed by the relief of these symptoms after surgery. The predominant occurrence of lingual osteomas in females continues to be an enigma.

REFERENCES

1. Roy JJ, Klien HA, Tipton DL. Osteochondroma of the tongue. Arch Path 1970, 89: 565-568.
2. Catalado E, Skhlar G Meyer I. Osteoma of the tongue. Arch Otolaryngol 1967, 85: 202-206.
3. Jag Bhawan, Raj Gopalan MR. Osteochondroma of tongue. Ind J Path Micro 1976, 19: 135.
4. Gupta ML, Dube MK, Gupta N, Gupta AN, Gupta AK. Chondroma of the tongue. Indian Otolaryngol 1989, 41: 123-124.

Acute Acalculous Cholecystitis in Typhoid Fever

S.D. Subba Rao
S. Lewin
B. Shetty
A.J. D'Cruz
C. Ramachandra
M.K. Chandrasekhara

There has been an increase in number of cases of typhoid fever with rare complications(1). Acute acalculous cholecystitis (AAC) is one such complication. AAC is a rare disease in pediatric practice. The detection of 14 cases within a 5 month period is an indication of an increase in the incidence and awareness of AAC. The literature mentions *Salmonella* infections as a cause of cholecystitis with gallbladder involvement as a known component in the natural history of typhoid(2). The upsurge in multi-drug resistant and more virulent typhoid may explain the emergence of some of these complications(3).

Material and Methods

During the period January to June 1991, fourteen children with AAC were diagnosed at our hospital. All were admitted with a provisional diagnosis of typhoid

From the Departments of Pediatrics, Pediatric Surgery and Radiology, St. John's Medical College Hospital, Bangalore 560 004.

Reprint requests: Dr. S.D. Subba Rao, Assistant Prof. of Pediatrics, St. John's Medical College Hospital, Bangalore 560 004.

Received for publication: October 28, 1991;

Accepted: June 18, 1992