

Case Reports

Giant Duodenal Hematoma in Hemophilia A

Benny Benjamin
Sajjadur Rahman
Amir Osman
Narinder Kaushal

Acute abdomen in a child with hemophilia requires consideration of an intra-abdominal hemorrhagic complications(1). We report a child with hemophilia A who presented with acute gastric outlet obstruction secondary to a giant duodenal wall haematoma. We emphasize the role of serial imaging and a conservative approach in the evaluation and management of an acute abdominal problem of this nature.

Case Report

A 10-year-old boy presented with a 40h-history of progressive epigastric and right hypochondrial pain, non-bilious vomiting,

constipation and failure to pass flatus. There was no history of injury. He was known to have hemophilia A with recurrent bleeding (easy bruising, hemarthroses, intramuscular hematomas and prolonged wound bleeding) which responded to factor VIII therapy. His parents were consanguineous and he had a brother with hemophilia A. On examination, he was moderately dehydrated and there was no pallor or icterus. The temperature was 36.8°C, heart rate 102/minute, respiratory rate 20/minute and blood pressure 124/84 mm Hg. Abdominal examination showed guarding and tenderness in the epigastrium and right hypochondrium. The liver dullness was preserved and the bowel sounds were sluggish.

From the Department of Child Health, King Saud University, Abha and Departments of Pediatrics, Surgery and Radiology, Asir Central Hospital, Abha, Saudi Arabia.

Reprint requests: Dr. B. Benjamin, 3A, 38-4th Main Road, Gandhi Nagar, Adyar, Madras 600 020.

Received for publication: May 4, 1995;

Accepted: August 20, 1995

Investigations revealed normal blood counts, and levels of urea, creatinine, electrolytes, liver function tests, and amylase. The prothrombin time (PT) was normal; the partial thromboplastin time (PTT) was 54 seconds (control 30 seconds). An erect abdominal X-ray on day 1 showed a single air-fluid level in a dilated stomach. The abdominal ultrasound showed a well-defined hyper echoic mass measuring 39x38x56 mm adjacent to the gall bladder and to the right of the lower part of the stomach. The liver, spleen, pancreas and kidneys appeared normal. The abdominal CT scan confirmed the presence of the mass in the region of the duodenum, adjacent to the gall bladder and the inferior surface of the liver. A barium meal showed a dilated stomach with gastric outlet obstruction and the appearance of a filling defect in the distal pyloric antrum.

The child received intravenous rehydration, factor VIII replacement (50 units/kg stat followed by 25 units/kg 8 hourly) and continuous naso-gastric drainage. The patient developed fever, diffuse abdominal pain and peritonism on day 2 and a repeat ultrasound showed a collection of fluid in the pelvic peritoneum. He was given a 7 day course of parenteral ampicillin and gentamicin and total parenteral nutrition (TPN). Serial hemograms, liver function tests and amylase levels were normal. The abdominal pain started easing and he

started passing stools and flatus from day 4. A gastrograffin meal on day 6 showed a mass projecting from the free wall of the first and second parts of the duodenum causing a slit-like narrowing of its lumen (*Fig. 1*), and there was marked delay in gastric emptying. An ultrasound showed that the peritoneal fluid had absorbed and the duodenal mass was of the same size but had mixed echogenicity. Repeat ultrasound on day 13 revealed that the mass was smaller and hypoechoic and a barium meal showed moderate improvement in the caliber of the duodenal lumen (*Fig. 1*). He tolerated oral fluids from day 7 and blenderized semi-liquid diet from day 14; thereafter TPN and factor VIII therapy were discontinued. He was discharged on day 20 on a normal diet, with no abdominal pain, tenderness or masses and normal bowel habit. He has remained well at follow up.

Discussion

Intramural hematomas have been reported to occur in any part of the gastrointestinal tract from the esophagus to the colon(1-5). They usually present with acute abdomen or gastrointestinal obstruction(1,3,6,7), but are an unusual cause of either of these presentations. In children, they usually follow accidental or non-accidental abdominal trauma(7,8) and may be a rare complication of procedures such as small bowel biopsy(9) or of bleeding disorders such as the hemophilias

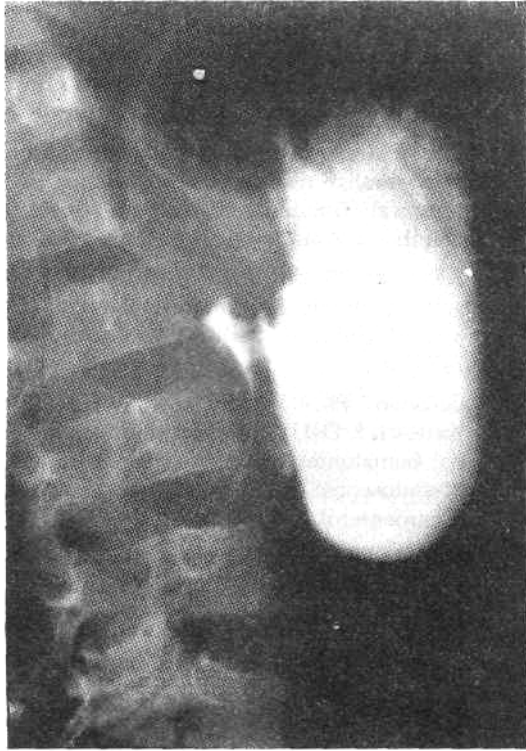

Fig. 1. Gastrograffin meal on day 6 showing a slit-like narrowing of the proximal duodenal lumen by a mass projecting from the free wall.

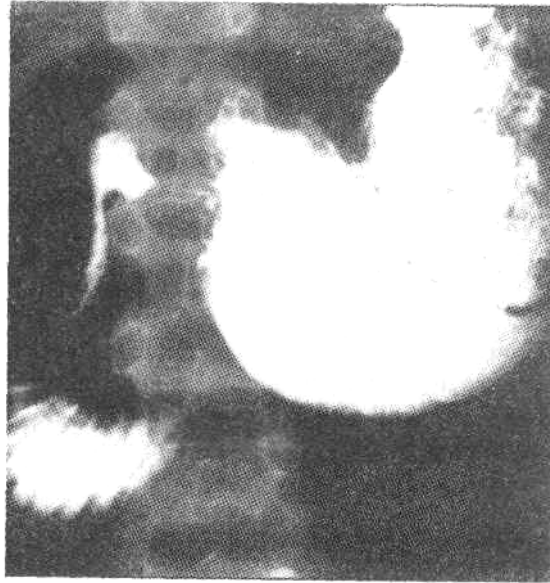


Fig. 2. Barium meal on day 13 showing partial resolution of the proximal duodenal obstruction. Note the normal caliber of the third part of the duodenum.

or purpuras(7,10). A bleeding diathesis should be excluded even in the absence of any suggestive past or family history.

A variety of imaging procedures have been used to diagnose and to follow the course of bowel wall hematomas. Contrast radiography is useful in defining the site and extent of bowel obstruction and in excluding a perforation(7). Ultrasound, CT and MRI imaging is useful in showing that an intramural hematoma is the cause of the obstruction, and in excluding the involvement of adjacent organs(1,10-14). There may be involvement of the pancreas, for example, in association with duodenal hematoma(6,15). Sequential imaging is

also helpful in demonstrating the evolution and resolution of the hematoma(5,7,10,13).

A conservative, expectant management approach in the form of nasogastric suction and TPN is appropriate in most patients with intramural bowel hematomas (1,3,7,15). Resolution can be anticipated to occur in 1-2 weeks, though this may sometimes be delayed for 1-2 months (3,7). In a patient with an underlying bleeding problem, early blood component replacement therapy to attain and maintain hemostatic levels of deficient factors is crucial in reducing life-threatening complications from internal hemorrhage (16). Surgical intervention is reserved for the few patients with complications such as perforation, intussusception or persistent obstruction (4, 5, 15).

Our patient was a known hemophiliac who presented with an acute abdomen. Initial imaging was useful in establishing the presence of a large hematoma causing gastric outlet obstruction. Though the hematoma was apparently 'spontaneous', the possibility of some trivial, unrecognized trauma cannot be excluded(5). Serial monitoring of serum bilirubin and amylase levels and contrast radiography enabled the conclusion that the hematoma, though extensive and involving the first and second parts of the duodenum, was confined to its free wall and had spared the bile and pancreatic ducts. An acute abdomen in a patient with hemophilia should be considered as being caused by a hemorrhagic complication unless proved otherwise (1). The importance of promptly identifying and correcting any underlying bleeding defect in reducing morbidity is highlighted. Conservative management under the supervision of a multidisciplinary team is advocated in dealing with this type of problem.

REFERENCES

1. McCoy HE, Kitchens CS. Small bowel hematoma in a hemophiliac as a cause of pseudoappendicitis: Diagnosis by CT imaging. *Am J Hematol* 1991, 38:138-139.
2. Intragumtornchai T, Israsena S, Benjacholamard V, Lerdlum S, Benjavongkulchai S. Esophageal tuberculosis presenting as intramural esophagogastric hematoma in a hemophiliac patient. *J Clin Gastroenterol* 1992,14:152-156.
3. Nogues A, Eizaguirre I, Sunol M, Tovar JA. Giant spontaneous duodenal hematoma in hemophilia A. *J Pediatr Surg* 1989, 24: 406-408.
4. LeBlanc KE. Jejuno-jejunal intussusception in a hemophiliac: A case report. *Ann Emerg Med* 1982,11:149-151.
5. Kahn A, Vandenbergert N, Cremer N, Fondu P. Intramural hematoma of the alimentary tract in two hemophilic children. *Helv Paediatr Acta* 1977, 31: 503-507.
6. Glassman MS, Rodrigues R, Bussel J, Spivak W, Hilgartner M. Acute obstructive pancreatitis secondary to a duodenal hematoma. *J Pediatr Gastroenterol Nutr* 1988, 7: 619-621.
7. Touloukian RJ. Protocol for the nonoperative treatment of obstructing intramural duodenal hematoma during childhood. *Am J Surg* 1983,145: 330-334.
8. Kleinman PK, Brill PW, Winchester P. Resolving duodenal-jejunal hematoma in abused children. *Radiology* 1986, 160: 747-750.
9. Ghishan FK, Werner M, Vieira P, Kuttesch J, DeHaro R. Intramural duodenal hematoma: an unusual complication of endoscopic small bowel biopsy. *Am J Gastroenterol* 1987, 82: 368-370.
10. Shirkhoda A; Mauro MA, Staab EV, Blatt PM. Soft-tissue hemorrhage in hemophiliac patients. Computed tomography and ultrasound study. *Radiology* 1983, 147: 811-814.
11. Morimoto K, Hashimoto T, Choi S *et al.* Ultrasonographic evaluation of intramural gastric and duodenal hematomata in hemophiliacs. *J Clin Ultrasound* 1988, 16: 108-113.
12. Martin B, Mulopulos GP, Butler HE. MR imaging of intramural duodenal hematoma. *J Comput Assist Tomogr* 1986, 10:1042-1043.
13. Hermann G, Gilbert MS, Abdelwahab IF. Hemophilia: Evaluation of musculoskeletal involvement with CT, sonography and MR imaging. *Am J Roentgenol* 1992, 158: 119-123.
14. Shih SL, Lin JC, Lee HC, Blickman JG. Unusual causes of obstructive jaundice in children: Diagnosis on CT. *Pediatr Radiol* 1992, 22: 512-514.
15. Jewett TC Jr, Caldarola V, Karp MP, Allen JE, Cooney DR. Intramural hematoma of the duodenum. *Arch Surg* 1988, 123: 54- 58.
16. Hamre MR, Haller JS. Intraspinal hematomas in hemophilia. *Am J Pediatr Hematol Oncol* 1992,14:166-169.