

cases is also recommended because: (a) presence of sinus connecting the skin to the pericardial cavity may lead to bacterial pericarditis; (b) vital mediastinal structures must be prevented from direct trauma; (c) many of these patients develop recurrent chest infection; and (d) the appearance of a child with its hearts bulging through its chest wall is very disturbing to parents.

#### REFERENCES

1. Kumar A, Nagesh NK, Mahajan S,

Chellani HK, Manmohan, Anand NK. Superior sternal cleft. *Indian Pediatr* 1988, 25: 203-206.

2. Mogiliner J, Siplovich L, Barziv J, Mares AJ. Surgical management of cleft sternum. *J Pediatr Surg* 1988, 23: 889-891.

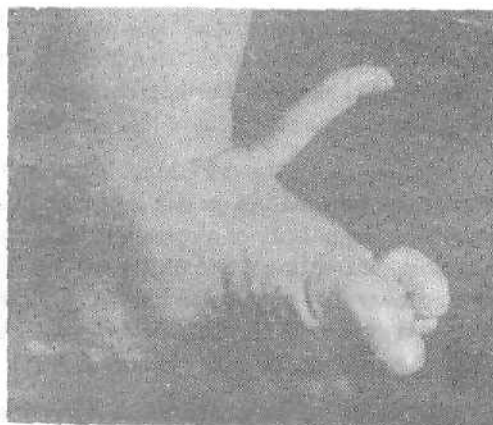
**N.C. Prajapati,  
P. Chaturvedi,**

*Neonatal Unit, Department of Pediatrics,  
M.G. Institute of Medical Sciences,  
Sevagram, Wardha 442 102.*

## Unusual Polydactyly Foot

Polydactyly is a developmental anomaly characterized by supernumerary<sup>1</sup> digits. Polydactyly foot, although not as common as that of hand, is definitely not rare. The sexes are equally affected but there is a racial predilection in that blacks show an incidence of 3.6 per 1000 live births and whites an incidence of 0.3 per 1000 live births(1). The variations of polydactyly are numerous, the most common is postaxial and is associated with syndactyly and short toes. Preaxial duplication or duplication of the hallux and multiple polydactyly are rather unusual. We report an unusual case of polydactyly where the accessory toe arose from the dorsal aspect of the foot. Such a bizarre anomaly has never been reported hitherto.

A six-month-old boy presented to the Outpatient Department with an accessory toe arising from the dorsal aspect of the left foot. Examination revealed a fully developed toe with nail adenaxe measuring 4 cm in length (*Fig. 1*). X-rays revealed three distinct phalanges articulating with the base of the middle metatarsal. There were no other associated abnormalities to suggest any genetic etiology. There was no history



*Fig. 1. Note well-formed accessory digit arising from the dorsal aspect of the foot.*

of similar abnormality in the family. Disarticulation of the metatarsophalangeal joint and excision of the accessory toe was done. The post-operative period was uneventful.

As emphasized by Tematamy *et al.*(2) polydactyly may occur with many established genetic syndromes; the associated abnormalities are usually that of skin, bone, eye and the orofacial region. The exact etiology in other non-syndromic types, as seen in our case, is not known. Irrespective of the etiology and morphology, an early treatment is indicated in all cases. The operative procedure has to be individualized so as to give the best contour to a particular foot. Complex anomalies should be handled by

a team comprising of pediatric, plastic and orthopedic surgeons.

#### REFERENCES

1. Venn Watson EA. Problems in polydactyly of the foot. *Orthop Clin North Amer* 1976, 7: 909.
2. Tematamy SA, McKusick VA. Synopsis of hand malformations with particular emphasis in genetic factors. *Birth Defects* 1969, 3: 125.

**Y.K. Sarin,**  
**A.K. Sharma,**

*Department of Pediatric Surgery,  
S.P.M.C.H.I. attached to S.M.S. Medical  
College, Jaipur 302 004.*