

epidermis. A diagnosis of classic type of nevus lipomatosis cutaneous superficialis was made.

Nevus lipomatosis cutaneous superficialis (NLCS) is a rare hamartoma of adipose tissue presenting as multiple, soft, skin-coloured or yellowish lobules that may coalesce to give rise to the distinctive cerebriform surface. The lesions may present at birth or develop in the first two decades of life. Lower back, hip, upper thigh and abdomen are the commonly affected sites. The common differential diagnoses in the present case were: plexiform neurofibromatosis (folded overlying skin and hyperpigmentation), verrucous epidermal nevus (dirty gray or

dark brown coalescing papules with a verrucous surface), superficial lymphatic malformation (grouped, tense vesicular lesions with clear colourless fluid). Since NLCS is usually asymptomatic, treatment is required only for the cosmetic reasons. Excision is usually curative and recurrences after surgery are uncommon.

***RAJESH KUMAR MANDAL, ABHIJIT DUTTA AND
#SUDIP KUMAR GHOSH**

*Departments of *Dermatology and Pediatric Medicine
North Bengal Medical College and
#Dermatology, RG Kar Medical College; Kolkata, West
Bengal, India.
dr.adutta@yahoo.co.in*

Fordyce's Spots

A 14-year-old boy presented with gradually increasing, asymptomatic white elevations over the mucosa of right cheek since 4 years of age. There was no history of tobacco abuse, and the past medical history and family history were unremarkable. Examination showed clusters of small white papules with smooth shiny surface on the right cheek (**Fig. 1**). The lesions could not be scraped off. Rest of the mucocutaneous and systemic examination was normal. The condition was diagnosed as Fordyce spots and the parents were reassured.

Fordyce spots are ectopically located visible sebaceous glands on the genitals, lips and oral cavity, vermillion border of the lips being the commonest site. They appear as small, painless, raised, pale, red or yellow-white spots of 1 to 3 mm diameter. Their presence is considered as normal anatomic variants rather than a true medical condition. They are not usually visible in young children, and tend to appear at about 3 years of age increase during puberty and become more obvious in later adulthood. The condition needs to be differentiated from candidiasis (easily detachable white pseudomembranes), leukoplakia (adherent white plaque often with fissured surface) and white sponge nevus

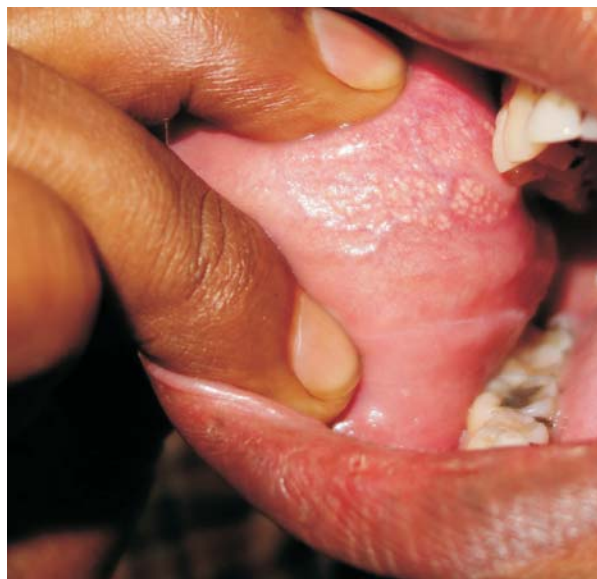


FIG. 1 Fordyce spots on mucosa of right cheek.

(thick, velvety, white spongy-looking plaques on buccal mucosa). No treatment is required; CO₂ laser or electro desiccations may be used to cosmetic concerns.

***ABANTI SAHA AND DEBABRATA BANDYOPADHYAY**
*Department of Dermatology,
Medical College, Kolkata, India.
sahaaby@gmail.com