

Neonatal Cholestasis with Ductal Paucity and Steatosis

RAJEEV KHANNA, SEEMA ALAM, *ARCHANA RASTOGI AND *CHHAGAN BIHARI SHARMA

*From the Departments of Pediatric Hepatology and *Pathology, Institute of Liver and Biliary Sciences, D-1, Vasant Kunj, New Delhi, India.*

Correspondence to: Rajeev Khanna, Department of Pediatric Hepatology, Institute of Liver and Biliary Sciences, D-1, Vasant Kunj, New Delhi 110 070. rrajeev_khanna@rediffmail.com

CLINICAL PROTOCOL

History: A 3.5-months-old male presented to us with small bowel type of diarrhea and recurrent non-bilious vomiting since birth; jaundice since 2.5 months of age; swelling all over body, clay colored stools, fever, cough and respiratory difficulty since 3 months of age, and refusal to feed from 2 days prior to admission. He also had prolonged bleeding at the site of intramuscular injection. There was no history of abnormal movements or altered sensorium. Investigations previously done at another center revealed severe anemia (Hb 5.7 g/dL), coagulopathy (prothrombin time 1 min) and lower respiratory tract infection, for which he had received three units of whole blood transfusion, vitamin K and parenteral antibiotics, and subsequently referred to our center.

He was second in birth order of a third degree consanguineous union, born full term vaginally with birth weight of 3.4 kg and uneventful perinatal and antenatal periods. His 21 months old elder brother had normal development with no similar history.

Clinical examination: On admission, he was afebrile with mild respiratory distress and normal cardiovascular status. He had pallor, icterus, pedal edema, angular cheilosis, glossitis and perianal excoriation. There was no evidence of skin or mucosal bleeds, cyanosis, clubbing, facial dysmorphism, lymphadenopathy, cataract, coloboma, posterior embryotoxon, chorioretinitis or cherry red spot. There were no features of xerophthalmia or rickets. His stools were persistently acholic. He had severe malnutrition with weight Z-score -2.37, length Z-score -3.52 and head circumference Z-score -1.53. His abdomen was distended with ascites and parietal edema, liver was palpable 6 cms below costal margin, firm in consistency with smooth surface (span 9 cms) and spleen 4 cms below costal margin. Both lung fields were clear on auscultation. There was no murmur or cardiomegaly. Child was lethargic and irritable corresponding to hepatic

encephalopathy stage 1-2. There were no meningeal signs, features of raised intracranial tension or neurological deficit.

Laboratory investigations: His hematological and biochemical profile during hospital stay is mentioned in **Table I**. Peripheral blood smear revealed normocytic hypochromic anemia. Renal function tests including electrolytes were normal. Urine was positive for non-glucose reducing substance (NGRS) but with no evidence of proteinuria. Stool was positive for fat globules. There was no fasting or post-prandial hypoglycemia. Triglycerides were high (509 mg/dL) while total cholesterol was normal.

Imaging: Chest and spine radiographs were normal. Abdominal sonogram showed enlarged echogenic liver, no dilatation of intrahepatic biliary radicles; gall bladder was contracted in the fasting state, common bile duct (CBD) was visualized with no evidence of triangular cord sign; spleen and kidneys were normal; there was no adrenal calcification. Echocardiography revealed structurally normal heart.

COURSE DURING HOSPITAL STAY

Child was started on parenteral antibiotics, urso-deoxycholic acid (UDCA), multivitamin supplements, medium chain triglycerides (MCT) based feeds and albumin infusion. Packed red cells were transfused. In view of high bilirubin, positive urine NGRS, vomitings and irritability, possibility of Galactosemia was kept and he was shifted to lactose free formula. Subsequently his Galactose-1-phosphate uridyl transferase (GALT) assay came out to be normal (15.5 g/dL; normal 15-45 g/dL), which could be false negative in this setting with recent (within 3 months) blood transfusions. Meanwhile other workup for intrahepatic cholestasis was done, which revealed normal alpha-fetoprotein for age (1135 ng/mL), normal urinary succinylacetone and normal serum alpha-1 antitrypsin (A1AT) (2.2 g/L, normal 0.9-2.0 g/L). His arterial blood gas analysis revealed normal pH and

TABLE I INVESTIGATIONS DURING HOSPITAL STAY

<i>Parameter</i>	<i>Day 1</i>	<i>Day 8</i>	<i>Day 20</i>	<i>Day 27</i>
Hemoglobin (g/dL)	10.3	7.4	9.8	8.0
Total leukocyte count (mm ³)	18200	25400	23400	20000
Differential leukocyte count (%)	P36 L53	P43 L53	P51 L42	P85 L08
Platelet (cells/mm ³ X 1000)	165	180	216	155
Bilirubin (Total/direct, mg/dL)	3.5/2.1	7.2/4.2	8.0/4.6	11.7/6.5
Aspartate aminotransferase (IU/L)	172	100	197	225
Alkaline aminotransferase (IU/L)	67	50	53	53
Alkaline phosphatase (IU/L)	94	70	103	107
Gamma glutamyl transpeptidase (IU/L)	170	89	102	141
Protein (g/dL)	3.0	5.8	5.2	5.9
Albumin (g/dL)	1.0	4.0	2.9	3.0
Prothrombin time (Test/control)	14.2/12	16.6/12	12.2/12	11.9/12
International normalized ratio	1.2	1.4	1.0	0.9
Ammonia (µg/dL)	203	65	181	118

lactate. Arterial ammonia was high (normal <60 µg/dL). Urine and plasma tandem mass spectrometry (TMS) did not reveal presence of abnormal metabolite for aminoacidurias, organic acidurias, and urea cycle, fatty-acid oxidation or respiratory chain defects. He was started on oral sodium benzoate for hyperammonemia.

Subsequently, he developed lower respiratory tract infection with polymorphonuclear leukocytosis. Antibiotics were changed, although blood and urine cultures were sterile. Immunoglobulin profile was normal and ELISA for HIV was negative. Chest findings improved transiently and a liver biopsy was undertaken. Magnetic resonance cholangiopancreatography (MRCP) and upper gastrointestinal endoscopy were planned, but the procedures were deferred considering his poor respiratory condition.

Chest X-ray showed persistence of infiltrates with development of bronchiectatic changes. Sweat chloride levels were high on two occasions (75.7 mmol/L and 70 mmol/L). Mutational analysis revealed heterozygous state for delta F508 mutation. He was started on 3% saline nebulisations and pancreatic enzyme supplements. Lactose-containing feeds were restarted and density was increased by adding puffed-rice powder. This was followed by improvement in stool frequency and consistency, and resolution of steatorrhea. His respiratory status improved and weight gain started. In view of high bilirubin, persistent hypoalbuminemia and increasing liver size (10 cm below costed margin) with Pediatric end-stage liver disease (PELD) score of 20, the option of liver transplantation was given to the family and

evaluation was initiated. He was discharged in a stable condition on Day 36 of hospitalization, but he died due to recurrence of pneumonia at 5 months of age at his native place. Autopsy was not conducted.

Unit's diagnosis: Neonatal cholestasis with acholic stools (Ductal paucity); with Severe protein energy malnutrition (wasting and stunting), anemia, anasarca; with chronic diarrhea and steatorrhea; with Pneumonia.

Discussion on clinical protocol: The clinical and laboratory information in the child suggested neonatal cholestasis. **Table II** provides clinical and laboratory pointers to establish the diagnosis in a cholestatic infant. Passage of pigmented stools for first three months, absence of history of hemolysis or total parenteral nutrition, sonographic visualization of gall-bladder and CBD, with no evidence of sludge in gall bladder or CBD or dilatation of intrahepatic biliary radicles (IHBRD), and subsequent liver biopsy findings excluded biliary atresia, choledochal cyst and inspissated bile duct syndrome. Although MRCP could not be done but liver biopsy did not suggest neonatal sclerosing cholangitis [1-3].

Paucity of intralobular bile ducts (PILBD, or ductal paucity) and progressive familial intrahepatic cholestasis (PFIC) are among the common intrahepatic causes of cholestasis (**Table III**). This was a full-term baby with no facial dysmorphism, heart murmur, vertebral or heart defect, posterior embryotoxon, microcephaly, cataract, chorioretinitis, hypoglycemic spells or skin rash, his A1AT level was normal; thus excluding common causes of ductal paucity [4]. The high GGT disfavored the

TABLE II KEY CLINICAL AND LABORATORY POINTERS TO DIAGNOSIS OF A CHOLESTATIC INFANT

Acholic stools	Biliary atresia, Choledochal cyst, Neonatal sclerosing cholangitis, inspissated bile duct syndrome, Spontaneous perforation of bile duct, Ductal paucity (PILBD)
Sick infant	MLD (Galactosemia, Tyrosinemia, Neonatal hemochromatosis, FATMO defects), Sepsis, Urinary tract infection, TORCH infections
Pruritus	PFIC types 1, 2 and 3, PILBD (Alagille's syndrome and Non-syndromic)
Ascites	MLD (Galactosemia, Tyrosinemia, Neonatal hemochromatosis), Late presentation of biliary atresia (>6 mo), End-stage liver disease due to any cause, Spontaneous perforation of bile duct
Dysmorphism	Alagille's, Down's syndrome, Williams syndrome, Peroxisomal defects, TORCH infections
Cardiac defect or murmur	Alagille's syndrome (Peripheral pulmonary artery stenosis), Congenital rubella (Patent ductus arteriosus, Tetralogy of Fallot, Ventricular septal defect), Biliary atresia (VSD, Atrial septal defect)
Eye findings	Galactosemia (Cataract), Alagille's syndrome (Posterior embryotoxon), TORCH infections (Chorioretinitis), Niemann-Pick disease type C (Cherry red spot)
Vertebral defects	Alagille's syndrome
Lymphedema	Agenes syndrome
Rickets ± Renal tubular acidosis	Galactosemia, Tyrosinemia
Low GGT	Progressive familial intrahepatic cholestasis (PFIC) types 1 & 2, Bile acid synthetic defects
Hyperammonemia	NICCD, Advance liver failure due to any cause
Hypoglycemia	MLD (Galactosemia, Tyrosinemia, Neonatal hemochromatosis, FATMO defects, Advance liver failure due to any cause)

PILBD = Paucity of intralobular bile ducts; *MLD* = Metabolic liver disease; *FATMO* = Fatty-acid transport and mitochondrial oxidation, *TORCH* = *Toxoplasma, Rubella, Cytomegalovirus, Herpes, Others*; *NICCD* = Neonatal intrahepatic cholestasis caused by citrin deficiency.

diagnosis of PFIC types 1 and 2 [5]. Cystic fibrosis (CF) was suggested by the infant's phenotype, which was later confirmed by sweat chloride testing and mutational analysis [6].

Among the metabolic liver disease, Galactosemia was considered in view of vomitings, irritability, failure to thrive, positive NGRS, chest infection and deteriorating liver functions; although, acholic stools, absence of hypoglycemia, non-response to galactose-free formula were against this possibility. Absence of liver failure with normal urinary succinylacetone excluded Tyrosinemia. Hyperammonemia and normal lactate with evidence of liver dysfunction suggested a possibility of neonatal intrahepatic cholestasis caused by citrin deficiency (NICCD), but the disorder was excluded on TMS [5].

PATHOLOGY PROTOCOL

Liver tissue comprised of ten portal areas. Hematoxylin and eosin staining revealed marked acinar disarray with swollen hepatocytes filled with marked macrovesicular steatosis (90%). There was cytoplasmic rarefaction with pseudoacinar transformation, along with hepatocellular and canalicular cholestasis, and formation of cholestatic rosettes. Few hepatocytes showed glycogenated nuclei.

Sinusoids were compressed. Portal areas displayed minimal mixed inflammation with absence of bile ducts in 7 out of 10 tracts. Masson's Trichrome staining showed mild periportal fibrosis. Periodic acid Schiff's (PAS) staining alone and with prior diastase digestion didn't reveal any cytoplasmic inclusions (**Fig. 1**).

Pathological diagnosis: Paucity of intralobular bile ducts; Macrovesicular steatosis.

Discussion on Pathology Protocol: Liver biopsy findings in this 3.5 months old male infant suggest ductal paucity with marked steatosis. **Table III** shows important histopathological pointers in liver biopsy of a cholestatic infant which may provide clue to diagnosis. Ductal paucity or PILBD is a histological term defined as number of bile ducts to portal tracts (BD/PT) ratio of less than 0.4 as mentioned for adults (normal range in children 0.9-1.8) commented in a biopsy containing at least 10 portal tracts [3, 7]. The concerned infant had ductal paucity (BD/PT ratio 0.3). Steatosis with ductal paucity at this young age pointed towards two differentials - α 1AT deficiency and CF [4].

Liver biopsy findings of AIAT deficiency are highly variable and include portal and lobular inflammation, necrosis, ductal paucity, ductular proliferation, portal

TABLE III KEY HISTOPATHOLOGICAL POINTERS IN LIVER BIOPSY TO DIAGNOSIS OF A CHOLESTATIC INFANT

Cholestasis (hepatocellular and canalicular bile stasis), bile plugs, ductular proliferation	Biliary atresia, extrahepatic obstruction (choledochal cyst, inspissated bile syndrome), bile-acid synthetic defects, PFIC type 1 and 3
Portal fibrosis with early cirrhosis	Biliary atresia, choledochal cyst, Metabolic disorders (Galactosemia, Tyrosinemia, Neonatal hemochromatosis, A1AT deficiency), PFIC type 2
Lobular and portal inflammation, giant-cell transformation, extramedullary hematopoiesis	Idiopathic neonatal hepatitis, TORCH infections, PFIC type 2, MLD
Ductal paucity	Alagille's syndrome, Non-syndromic PILBD (α 1AT deficiency, CF, Down's syndrome, Williams syndrome, Peroxisomal disorders, Prematurity, TORCH infections, hypopituitarism, PFIC types 1 and 2)
Steatosis	MLD (Galactosemia, Hereditary fructose intolerance, Tyrosinemia, α 1AT deficiency, CF, NICCD, Peroxisomal disorders, FATMO defects)
PAS-positive diastase resistant globules in periportal hepatocytes	α 1AT deficiency

PFIC = Progressive familial intrahepatic cholestasis, A1AT = Alpha-1 antitrypsin deficiency, TORCH = Toxoplasma, Rubella, Cytomegalovirus, Herpes, Others, MLD = Metabolic liver disease, PILBD = Paucity of intralobular bile ducts, CF = Cystic fibrosis, NICCD = Neonatal intrahepatic cholestasis caused by citrin deficiency, FATMO = Fatty-acid transport and mitochondrial oxidation.

fibrosis, cirrhosis and variable steatosis. The characteristic histopathological hallmark in the form of PAS positive, diastase resistant eosinophilic inclusions comprised of retained A1AT globules in periportal hepatocytes and bile duct epithelial cells are usually seen in infants older than 3 months, which increase in number subsequently [8].

Liver pathology in CF in young infants usually includes steatosis, inflammation, paucity of intralobular bile ducts, ductular proliferation, portal inflammation, portal expansion, fibrosis, cirrhosis and cholestasis [7, 9-11]. The pathognomonic lesion of CF-related liver disease CFLD is focal biliary cirrhosis, which develops due to blockage of biliary ductules secondary to viscid secretions [7]. Focal changes are seen in 11% of infants, 26% of those dying at one year; and in more than 70% of adults, and they later on progress to multilobular biliary cirrhosis with subsequent portal hypertension. Steatosis is seen in 23-67% and is panlobular macrovesicular type and may occur without focal biliary cirrhosis [7, 9, 12].

Final diagnosis: Cystic fibrosis with lung and liver involvement (pneumonia, bronchieactasis, cholestasis with liver dysfunction); Severe malnutrition, anemia.

OPEN FORUM

Cystic fibrosis (CF) is a rare cause of neonatal cholestasis (0.6-0.7%) [10, 11]. Suggestive phenotype and genotype with high sweat chloride levels in our infant fulfilled the diagnostic criteria [6]. Neonatal or infantile cholestasis is a known but unusual manifestation of CF [9]. Overall, prevalence of CF in the West is ~1 in 3500 newborns [6]. In India, the estimated prevalence is low, but the diagnosis is now getting increasingly recognized due to awareness and availability of diagnostic tests [13].

Cystic fibrosis-related liver disease (CFLD) is seen in 55-70% of cases with CF with median age at diagnosis of 12 years and is associated with severe malnutrition, early death and risk for lung transplantation [9, 14]. Portal hypertension is predicted by presence of fibrosis, and occurs at a young age with severe fibrosis [12]. Risk of CFLD in CF is around 1.8% per 100 person-years and is more with male gender, younger age, history of meconium ileus, or presence of severe mutations [15].

Infants with CF have evidence of biochemical CFLD in more than 50% of cases, but such mild biochemical abnormalities revert to normal in most of them [9]. Presentation as neonatal cholestasis is rare as per two

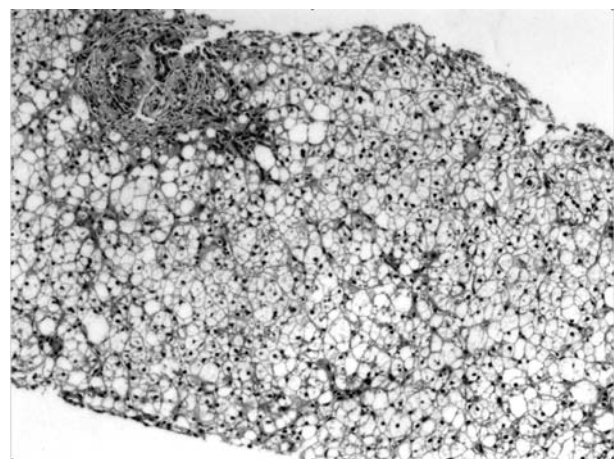


FIG. 1 Liver biopsy (Hematoxylin and Eosin stain, 100X) showing acinar disarray, distended hepatocytes with marked macrovesicular steatosis. Portal tract reveals portal fibrosis with periportal extension, and absence of bile duct.

older series describing 21 cases; three of which mimicked biliary atresia. Jaundice, hepatomegaly, hypoalbuminemia, meconium ileus, acholic stools, and chest symptoms were the presenting features. Jaundice cleared within a median duration of 7.4 months. Clinical or biochemical CFLD and cirrhosis developed in 13 and 4 cases, respectively [10, 11]. One Indian series has reported one CF among 410 neonatal cholestasis cases (0.002%) from a tertiary referral centre, but the exact details are lacking [16].

Management of CFLD is aimed at nutritional support and UDCA, with subsequent focus on management of cirrhosis and its complications [17]. Liver transplantation is done either alone or combined with lung and is shown to have comparable outcomes [18]. Indications for transplantation are decided on basis of model for end-stage liver disease (MELD) or pediatric end-stage liver disease (PELD) score, giving additional points if forced expiratory volume in 1 second is less than 40% [19]. An algorithm for consideration of patients for LT or LLT in CFLD has been proposed [18].

In conclusion, cystic fibrosis, CF, although a rare cause of neonatal cholestasis, should be considered in the work-up of an infant with cholestasis after the common etiologies have been excluded.

Contributors: RK and SA designed the format of clinicopathological conference and revised the manuscript for intellectual content. RK will act as the guarantor. AR and CBS conducted pathology protocol and provided pathology discussion. SA and AR drafted the final clinical and pathology discussion. All authors participated in open forum.

Funding: None; *Competing interests:* None stated.

REFERENCES

1. Bruyne RD, Biervliet SV, Velde SV, Winckel MV. Clinical practice - Neonatal cholestasis. *Eur J Pediatr.* 2011;170:279-84.
2. Guideline for the Evaluation of Cholestatic Jaundice in Infants: Recommendations of the North American Society for Pediatric Gastroenterology, Hepatology and Nutrition. *J Pediatr Gastroenterol Nutr.* 2004;39:115-28.
3. Suchy FJ. Anatomy, histology, embryology, developmental anomalies, and pediatric disorders of the biliary tract. In: Feldman M, Friedman LS, Brandt LJ (eds). *Sleisenger and Fordtran's Gastrointestinal and Liver Disease, Pathophysiology/Diagnosis/Management*, Ninth edition. Saunders, an imprint of Elsevier Inc., Philadelphia, 2010; p 1045-66.
4. Sinha J, Magid M S, VanHuse C, Thung S N, Suchy F, Kerkar N. Bile duct paucity in infancy. *Semin Liver Dis.* 2007;27:319-23.
5. Hansen K, Horslen S. Metabolic liver disease in children. *Liver transplantation.* 2008;14:713-33.
6. Farrell PM, Rosenstein BJ, White TB, Accurso FJ, Castellani C, Cutting GR, *et al.* Guidelines for Diagnosis of Cystic Fibrosis in Newborns Through Older Adults: Cystic Fibrosis Foundation Consensus Report. *J Pediatr.* 2008;153:S4-S14.
7. Russo P, Rand EB, Haber BA, Loomes KM. Diseases of the biliary tree in infancy and childhood. In: Russo P, Ruchelli ED, Picolli DA (eds). *Pathology of Pediatric Gastroentero-intestinal and Liver disease 2004*, Springer-Verlag New York, Inc., p 203-36.
8. Teckman JH. Alpha-1 antitrypsin deficiency in childhood. *Semin Liver Dis.* 2007;27:274-81.
9. Lindblad A, Glaumann H, Strandvik B. Natural history of liver disease in cystic fibrosis. *Hepatology.* 1999;30:1151-8.
10. Lykavieris P, Bernard O, Hadchouel M. Neonatal cholestasis as the presenting feature in cystic fibrosis. *Arch Dis Child.* 1996;75:67-70.
11. Shapira R, Hadzic N, Francavilla R, Koukulis G, Price JF, Mieli-Vergani G. Retrospective review of cystic fibrosis presenting as infantile liver disease. *Arch Dis Child.* 1999;81:125-8.
12. Lewindon PJ, Shepherd RW, Walsh MJ, Greer RM, Williamson R, Pereira TN, *et al.* Importance of hepatic fibrosis in cystic fibrosis and the predictive value of liver biopsy. *Hepatology.* 2011;53:193-201.
13. Kabra SK, Kabra M, Lodha R, Shastri S, Ghosh M, Pandey RM, *et al.* Clinical profile and frequency of delta F 508 mutation in Indian children with cystic fibrosis. *Indian Pediatr.* 2003;40:612-9.
14. Chrysostalis A, Hubert D, Coste J, Kanaan R, Burgel PR, Desmazes-Dufeu N, *et al.* Liver disease in adult patients with cystic fibrosis: A frequent and independent prognostic factor associated with death or lung transplantation. *J Hepatol.* 2011;55:1377-82.
15. Bhardwaj S, Canlas K, Kahli C, Temkit M, Molleston J, Ober M, *et al.* Hepatobiliary abnormalities and disease in cystic fibrosis: epidemiology and outcomes through adulthood. *J Clin Gastroenterol.* 2009;43:858-64.
16. Arora NK, Arora S, Ahuja A, Mathur P, Maheshwari M, Das MK, *et al.* Alpha-1 antitrypsin deficiency in children with chronic liver disease in North India. *Indian Pediatr.* 2010;47:1015-23.
17. Debray D, Kelly D, Houwen R, Strandvik B, Colombo C. Best practice guidance for the diagnosis and management of cystic fibrosis-associated liver disease. *J Cyst Fibros.* 2011;10:S29-S36.
18. Arnon R, Annunziato RA, Miloh T, Padilla M, Sogawa H, Batemarco L, *et al.* Liver and combined lung and liver transplantation for cystic fibrosis: Analysis of the UNOS database. *Pediatr Transplantation.* 2011;15:254-64.
19. Horslen S, Sweet S, Gish RG, Shepherd R. Model for end-stage liver disease (MELD) exception for cystic fibrosis. *Liver Transplantation.* 2006;12:S98-S99.