

## **Systemic Lupus Erythematosus With Aortoarteritis**

**J. Menon  
S.C. Karande  
K.P. Khambekar  
S.G. Lalwani  
U.B. Nadkarni  
M.K. Jain**

Systemic lupus erythematosus (SLE) is a multisystem autoimmune disorder, the incidence of which, in prepubertal children is quite rare(1). The diagnostic clinical criteria as suggested by the American Rheumatology Association (ARA) are well known(2). The most specific diagnostic laboratory finding is the presence of antibody to double-stranded DNA (ds DNA)(3). We report a child with SLE and idiopathic aortoarteritis an hitherto unreported association.

### **Case Report**

A 6-year-old girl presented to us with a history of two episodes of focal seizures (first right-sided and then left-sided) within a period of 24 h. On examination, she had a normal sensorium, Cushingoid fades, tachycardia, absent peripheral pulses (except for the carotids) and good peripheral perfusion. The blood pressure was not recordable in all four limbs. She also had muffled heart sounds with no murmur and a transient right-sided hemiparesis. The fundi were normal.

The child was hospitalized 2 months earlier in another hospital with complaints of chest pain and an episode of generalized seizures. She was treated with decongestive measures and discharged

after a week, on digoxin and prednisolone, with a diagnosis of rheumatic carditis with seizures of an unknown etiology. Her birth history and developmental milestones were normal.

Laboratory investigations showed a total leucocyte count of  $16.9 \times 10^9/L$  with 65% polymorphs and 35% lymphocytes and ESR 40 mm in the first hr.. The urine examination was normal. The blood level of urea nitrogen was 20 mg/dl and creatinine 0.6 mg/dl. VDRL was non-reactive. Mantoux test was negative and chest X-ray showed no evidence of tuberculosis. She had significant titers of antinuclear antibody (1:20) and anti ds DNA (1:32), with a low serum  $C_3$  level (50 mg/dl; normal 60-110 mg/dl), inspite of having been on daily prednisolone for almost two months.

A 2-D Echo examination revealed impaired LV function with an ejection fraction of 35%. CT scan of the brain showed bilateral cortical venous infarcts. Ultrasonographic examination of the abdomen showed normal sized kidneys. Aortogram showed arteritis involving both subclavian arteries, the descending thoracic aorta, the superior mesenteric artery and both femoral arteries with no involvement of the renal arteries (*Figs.1 &2*).

A diagnosis of SLE with associated idiopathic obstructive aortoarteritis was made and the child treated with prednisolone 2 mg/kg/day. After one month when serum  $C_3$

---

*From the Department of Pediatrics, Seth G.S. Medical College and KEM Hospital, Parel, Bombay 400 012.*

*Reprint requests; Dr. M.K. Jain, Honorary Professor of Pediatrics, Department of Pediatrics, Seth G.S. Medical College and KEM Hospital, Parel, Bombay 400 012.*

*Received for publication: December 30, 1994;*

*Accepted: April 1, 1995*

---

level returned to normal and anti ds DNA antibody was negative, maintenance therapy with alternate day steroids was continued. Four months later surgical intervention for aortitis, with a side to side aorto-aortic shunt, was successfully undertaken. On follow up 9 months later, the blood pressure in the lower limbs was normal (110/ 70 mm Hg). Urine examination, serum C<sub>3</sub> and ESR were within normal limits. The patient is on maintenance alternate-day prednisolone (0.5 mg/kg/dose).

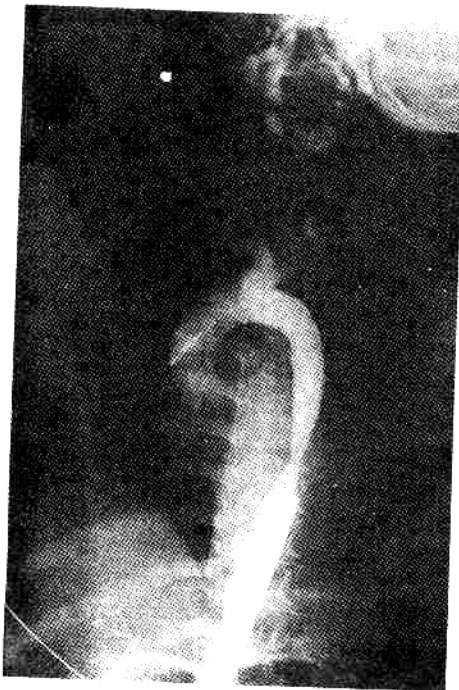**Discussion**

The diagnosis of SLE was based on the clinical and laboratory findings as outlined by the revised ARA criteria(2). This child had central nervous system and cardiac involvement with significant titers of antinuclear antibody and anti ds DNA antibody to confirm the diagnosis of SLE.

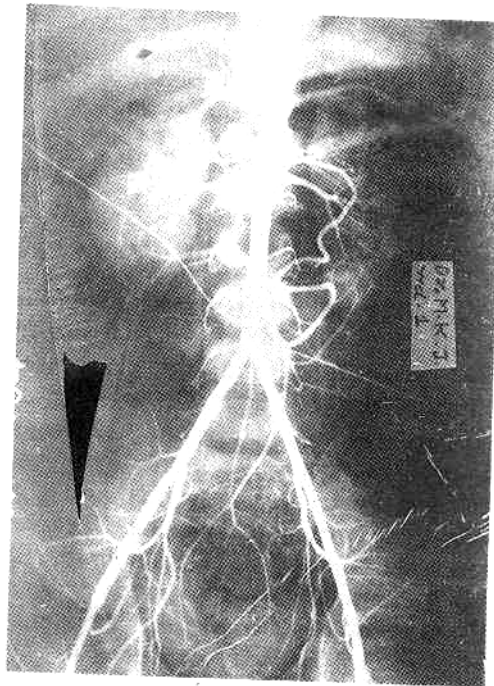
Involvement of large vessels in SLE is exceedingly rare(4). In the reported series

of SLE in Indian children, this manifestation has not been mentioned(1,5). The commoner causes for aortoarteritis are syphilis, non-specific aortoarteritis, Takayasu's disease, sarcoidosis, tuberculosis, giant cell arteritis, Marfan's syndrome, ankylosing spondylitis, Reiter's syndrome, Behcet's disease and relapsing polychondritis(4,6). In none of these conditions is anti ds DNA antibody detected

In Indian studies of idiopathic obstructive aortoarteritis(6,7), no association with positive titers of antibody to ds DNA was reported. However, there are isolated case reports of the occurrence of aortoarteritis with autoimmune disease(8,9). Ascending aortitis has been reported in some patients with SLE(4,10,11). To our knowledge, no association of descending aortitis with SLE is previously reported. The possibility that the association of SLE and aortitis was incidental cannot be, however, ruled out.



*Fig.1. Aortogram showing narrowing of the descending aorta at D6-7 level with absent filling of subclavian arteries*



*Fig.2. Aortogram showing absent filling of the superior mesenteric artery, normal renal arteries and narrowed internal iliac and femoral arteries*

**Acknowledgements**

We thank our Dean, Dr. P.M. Pai, for granting us permission to publish this case report. We also thank the Director, Institute of Immunohematology, KEM Hospital for permitting us to publish the reports of ANA and anti ds DNA.

**REFERENCES**

1. Ali US, Dalvi RB, Merchant RH, *et al.* Systemic lupus erythematosus in Indian children. *Indian Pediatr* 1989, 26: 868-873.
2. Tan EM, Cohen AS, Fries I, *et al.* The 1982 revised criteria for the classification of systemic lupus erythematosus. *Arthritis Rheum* 1982, 25: 1276-1277.
3. Schaller JG. Systemic lupus erythematosus. *In: Nelson Textbook of Pediatrics*, 14 edn. Eds. Behrman RE, Kliegman RM, Nelson WE, Vaughan VC III. Philadelphia WB Savnders Co., 1992, pp 624-627.
4. MacLeod CB, Johnson D, Frable WJ. "Tree-barking" of the ascending aorta: syphilis or systemic lupus erythematosus? *Am J Clin Path* 1992, 97: 58-62.
5. Chandrasekaran AN, Rajendran CP, Ramakrishnan S, Madhavan R, Parthiban M. Childhood systemic lupus erythematosus in South India. *Indian J Pediatr* 1994, 61: 223-229.
6. Kinare SG, Iyer I, Murthy A, Dave KH, Kelkar MD. Non-specific aortoarteritis-immunological studies. *Indian Heart J* 1983, 35: 337-340.
7. Shrivastava S, Srivastava RN, Tandon R. Idiopathic obstructive aortoarteritis in children. *Indian Pediatr* 1986, 23: 403-410.
8. Folicov RE, Cooney DF. Takayasu's arteritis and rheumatoid arthritis. *Arch Int Med* 1964, 114: 594-600.
9. Swallow D. A case of aortic arch syndrome of Takayasu due to SLE. *Post graduate Med J* 1967, 43: 503-505.
10. Shulman HJ, Christian CL. Aortic insufficiency in systemic lupus erythematosus. *Arthritis Rheum* 1969, 2: 138-145.
11. El-Ghobarey A, Grennan DM, Hadidi T, El-Bodawy S. Aortic incompetence in systemic lupus erythematosus. *Br Med J* 1976, 2: 915-916.

