

Noonan syndrome have been suggested by Levy and associates, who reported the first case of male to male transmission of this condition and postulated that in some families it may be transmitted in an autosomal dominant manner with variable expressivity(9). Baird and Dejong have subsequently reported a family in which the syndrome was transmitted through three generations in a dominant manner(10). The four cases reported by us, in three, generations from one family, also follow the dominant mode of transmission.

### Acknowledgements

We express our sincere thanks to Dr. M. Viswanathan, Cardiologist for advice and Mrs. S.C. Shetty for preparing the manuscript.

### REFERENCES.

1. Noonan JA, Ehmke DA. Associated non cardiac malformation in children with congenital heart disease. *J Pediatr* 1963, 63: 468-470.
2. Noonan JA. Hypertelorism with Turner phenotype—A new syndrome with associated congenital heart disease. *Am J Dis Child* 1968,116: 373-380.
3. Mendez HMM, Opitz JM. Noonan syndrome: A review. *Am J Med Genet* 1985, 21: 493-506.
4. Collins E, Turner G. The Noonan syndrome-A review of the clinical and genetic features of 27 cases. *J Pediatr* 1973, 83: 941-950.
5. Sharland M, Burch M, McKenna WM, Paton MA. A clinical study of Noonan Syndrome. *Arch Dis Child* 1992, 67: 178-183.
6. Money J, Klaus ME. Noonan's syndrome: IQ and specific disabilities. *Am J Dis Child* 1979,133: 846-850.
7. Schon F, Bowler J, Baraitser M. Cerebral arteriovenous malformation in Noonan's syndrome. *Post Grad Med J* 1992, 68: 37-40.
8. Duncan WJ, Fowler RS, Farkas LG, *et al.* A comprehensive scoring system for evaluating Noonan syndrome. *Am J Med Genet* 1981,10: 37-50.
9. Levy EP, Pashayan H, Fraser FC, Pinsky L. XX and XY Turner phenotypes in a family. *Am J Dis Child* 1970, 120: 36-43.
10. Baird PA, De Jong BP. Noonan's syndrome (XX and XY Turner phenotype) in three generations of a family. *J Pediatr* 1972, 80:110-114.

## Conjoined Twins with Jugular Lymphatic Obstruction Sequence

**K. Balakumar**

Antenatal ultrasonographic diagno-

sis of conjoined twins and associated anomalies have been well documented in the past few years. We are reporting an unusual combination of conjoined twins with jugular lymphatic obstruc-

---

*Reprint requests: Dr. K. Balakumar, P.V.S. Hospital (P) Ltd., Railway Station Road, Calicut 673 002.*

*Received for publication: July 19,1994;  
Accepted: November 4,1994*

tion sequence diagnosed *in utero*. The recognition of these conditions together can predict an invariably lethal outcome.

### Case Report

A 22-year-old second gravida was referred for ultrasound scanning because of previous intrauterine death of unidentified cause. She was otherwise normal and the uterine size was corresponding to the gestational age of 20 weeks.

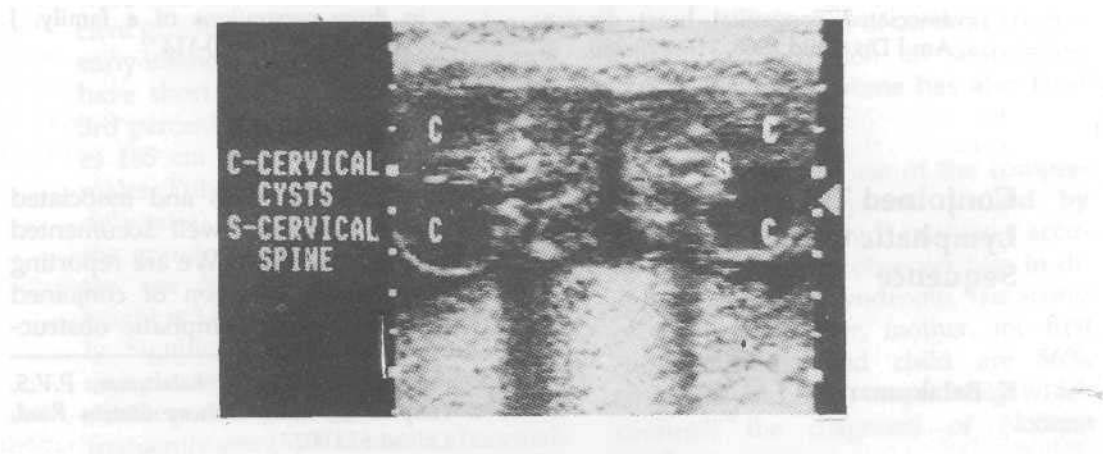
Scanning showed a bulky placenta of 6.6 cm thickness and adequate volume of liquor. Two fetuses were seen facing each other with their heads separated. The thoraces and abdominal walls were joined ventrally so that the spines were on opposite sides. Skeletal growth was normal. Thoracic sections showed a common heart in the central region. The shared massive liver was occupying upper abdomen and the bowel loops were lying crowded. Skull bones and spines were of normal appearance.

The fetuses showed cervical cysts partitioned in the median plane by the nuchal ligaments (*Fig. 1*) and there was associated scalp edema. Tense ascites filled the common abdominal cavity (*Fig. 2*). The *v*-diagnosis of conjoined twins (thoraco-omphalopagus) with the possibility of jugular lymphatic obstruction sequence was made depending on these findings.

This pregnancy was terminated by Caesarian section and the autopsy confirmed the presence of lymphatic cysts in the cervical regions. Fetal ascites was of moderate volume and there was subcutaneous lymphangiectasis.

### Discussion

The incidence of conjoined twins has been reported as 1 in 50,000 to 100,000 live births(1,2). Conjoined twinning is only seen among monochorionic monoamniotic twins resulting from incomplete separation of the embryonic disc between 13 and 21 days of gestation. The condition is sporadic and sur-



*Fig. 1. Axial section of fetal heads showing the cervical lymph cysts partitioned by the nuchal ligaments.*

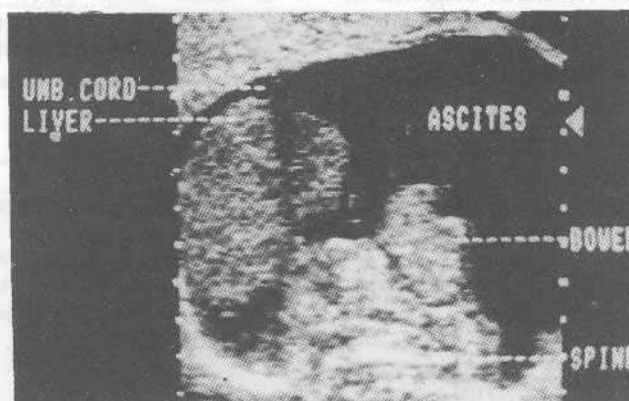


Fig. 2. Transverse section of the common abdomen filled with ascites.

vival depends on features such as the extent of fusion, nature of major shared organs, associated anomalies and threat to existence of one fetus by the co-twin.

The antenatal diagnosis is of great importance in the management of these cases which will help to prevent maternal complications, predict viability and, in determining the mode of delivery or early termination. Antenatal diagnostic features of conjoined twins are: (i) absence of interamniotic membrane; (ii) confluence of the body surface; (iii) simultaneous gross trunk movements; (iv) constant relative position of the fetuses to each other; (v) umbilical cord containing more than three vessels; (vi) unusual spinal or limb postures and (vii) associated anomalies(3). Commonly associated anomalies are cardiac (biventricular multiatrial single heart, septal defects, fused pericardial sacs)(4,5), gastrointestinal (common liver, omphalocele)(6) and genitourinary tract anomalies (common colon, bladder, urethra and rectovaginal anomalies)(7) depending on

the site of fusion.

Jugular lymphatic obstruction sequence is a recently described major anomaly resulting from the failure of establishment of communication between the paired jugular lymph sacs and internal jugular veins which normally occurs by 41 day of gestation. The ultrasound diagnostic features are: (i) presence of cervical cysts separated by nuchal ligament; (ii) extensive subcutaneous lymphangiectasis involving the scalp and other regions; and (iii) effusions in serous cavities(8). The association of this sequence with conjoined twins as above has not been reported so far.

#### REFERENCES

1. Hanson JW. Incidence of conjoined twins. *Lancet* 1975, 2:1257.
2. Mariona FG. Anomalies specific to multiple gestations. *In: Ultrasound in Obstetrics and Gynecology* Eds. Chervenak FA, Issacson GC, Campbell S. Toronto, Little Brown and Company, 1993, pp 1051-1063.

BRIEF REPORTS

3. Balakumar K. Antenatal diagnosis of conjoined twins with multiple malformations. *Indian Pediatr* 1993, 30: 545-547.
  4. Patel R, Fox K, Dawson J, Tailor JF, Graham GR. Cardiovascular anomalies in thoracopagus twins and the importance of preoperative cardiac evaluation. *Br Heart J* 1977, 39:1254-1258.
  5. Noonan JA. Twins, conjoined twins and cardiac defects. *Am J Dis Child* 1978, 132: 17-18.
  6. Gore RM, Filly RA, Parer JT. Sonographic antepartum diagnosis of conjoined twins and its impact on obstetrical management, *JAMA* 1982, 247: 3351-3353.
  7. Somasundaram K, Wong KS. Ischiopagus terapus conjoined twins. *Br J Surg* 1986, 73: 38-741.
  8. Balakumar K. Jugular lymphatic obstruction sequence: Antenatal diagnosis and its incidence in Kerala. *Indian J Radiol Imaging* 1993, 3: 89-91.
-