LETTERS TO THE EDITOR

Polysplenia Syndrome

The polysplenia and asplenia syndromes are well documented congenital entities associated with a high incidence of various visceral and cardiorespiratory anomalies and a strong tendency for normally asymmetric organs or pair of organs to develop symmetrically, *i.e.*, isomerism(1,2). We describe a case of polysplemia syndrome which had, in addition, association of genetically transmitted disease (thalassemia major) and unusual gastrointestinal anomaly (Meckel's diverticulum containing ectopic pancreatic and gastric mucosa) both of which have not been described previously with this syndrome.

A 5-year-old male child, known case of thalassemia major, developed massive splenomegaly (28 cm) and severe hypersplenism with increased requirement of blood transfusions and was referred to us for splenectomy. There were no external anomalies. At exploration, deeply multilobulated spleen, levoisomeric liver, a mobile cecum, multiple accessory spleens (total 15 at splenic hilum, splenic pedicle, peritoneal ligaments, in the tail and body of pancreas and along the posterior abdominal wall) and a Meckel's diverticulum containing ectopic pancreatic tissue at the tip and ectopic gastric mucosa at the base were found. Splenectomy with removal of all spenules and wedge resection of Meckle's diverticulum (*Fig.*) were performed and recovery was uneventful.

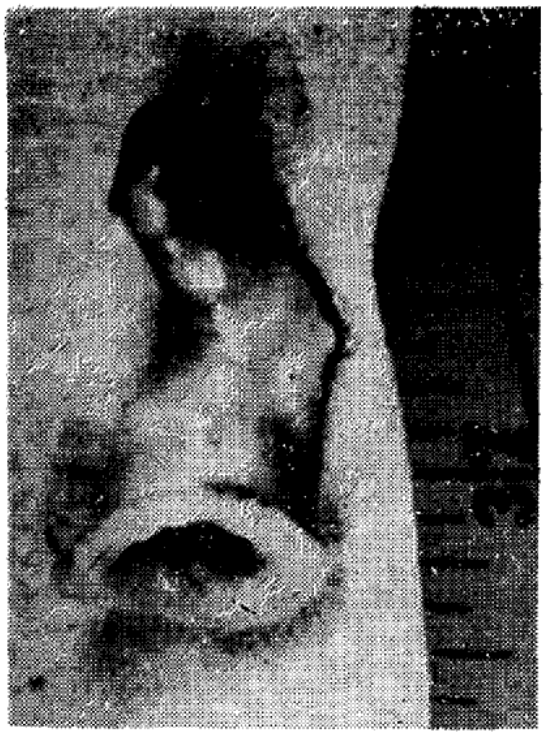

Fig. Excised specimen showing ectopic tissue mass at the tip and thickened base.

In polysplenia syndrome there is a strong preponderance of bilateral "left sidedness", *i.e.*, levoisomerism. The diagnosis and differentiation between asplenia and polysplenia syndromes is sometimes difficult, yet important in terms of patient prognosis. While bilateral superior vena cava, malrotation, other gastrointestinal anomalies, abdominal heteroataxia and sinus ambiguous may be present in both, the polysplenia syndrome is associated with equal sex distribution, 60% mortality within 1 year, bilobe lung, eparterial bronchi, mild or absent cardiac anomalies, total anomalous pulmonary venous return and biliary atresia. The asplenia syndrome is characterized by male predominance, 95% mortality within 1 year, trilobe lung, hyparterial bronchi, severe cardiac anomalies

and separate pulmonary veins entering into separate corresponding atria.

Because of levoisomeric liver, hepatomegaly was out of proportion and abdominal protruberance persisted significantly even after removal of the giant spleen. A meticulous search must be made to remove all spenules in such cases of hemolytic anemia with polysplenia syndrome. Abdominal wall closure should be done accurately to avoid problems of wound dehisence or incisional hernia because of enlarged levoisomeric liver.

M.H. Mehta,
R.V. Patel,
K.T. Children Government Hospital,
Rajkot 360 001.

REFERENCES

1. Paddock RJ, Arensman RM. Polysplenia syndrome: Specturm of gastrointestinal congenital anomalies. J Pediatr Surg 1982, 17: 563-566.
2. Vaughan TJ, Hawkins IF, Elliott LP. Diagnosis of polysplenia syndrome. Birth Defects 1972, 8: 621-624.

Celphos Poisoning

Recently aluminium phosphide (Celphos) taken by persons accidentally or with suicidal intent has resulted in large number of deaths. We are reporting one such case.

A six-year-old boy was admitted with complaint of ingesting aluminium phosphide (Celphos) tablet, pain in epigastrium 6 hours prior to admission, vomiting and altered sensorium two hours after the ingestion. There was no history of bleeding from any site, chest pain, breathlessness and diarrhea. The patient was brought to the hospital by his father who revealed that the mother along with 4 children (aged between 3 to 10 years) had taken Celphos tablets after an altercation with him. The exact number of tablets consumed by each child and mother was not known. While three children died after half an hour of ingestion, the mother succummbed eight hour later.

On examination, the pulse was 128/min regular, respiratory rate 46/min and blood pressure 80/60 mm Hg. He was drowsy, restless and pupils were semidilated but reacting to light. Cardiovascular examination showed no abnormality except tachycardia. Rest of the systems were normal.

Treatment included gastric lavage with 1 : 5000 solution of potassium permanganate, intravenous fluids, magnesium sulphate as antidote and oxygen inhalation. The condition of the patient deteriorated further in the form of fast and feeble radial pulse, blood pressure 56 mm Hg systolic and irregular respiration. At this time, the patient was put on intravenous dopamine infusion and hydrocortisone. This therapy also failed and the patient expired after 3 hours.

Celphos is used as a grain preservative and on exposure to moisture, liberates phosphine gas causing severe gastrointestinal irritation, cardiovascular collapse and death(1). Recent reports suggest a steady increase in cases of aluminium phosphide poisoning in our country. Chugh *et al.*(2) described 228 cases of Celphos poisoning in a 6 years period. Majority of cases belonged to younger generation and the intention was suicidal in 60% of cases with