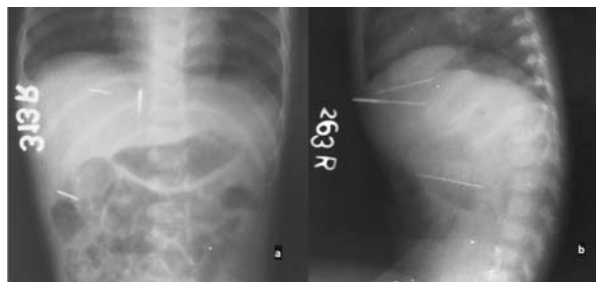


## Life-threatening Child Abuse: Penetrating Injury of Abdomen with Sewing Needles

Until the publication of Kempe, *et al.* [1] paper in 1962, child abuse was an under-recognized and under-reported entity. Now, more than half a century later, there is clear evidence that child abuse, also known as non-accidental trauma (NAT), is a global problem.

A 14-month-old girl weighing 5 kg was brought to the casualty services of our hospital by her mother with complaints of pain in the abdomen and persistent crying. The mother informed the physicians of her suspicion of rodent-bite while she was away doing household chores. A careful examination revealed a single pin-head sized puncture mark in the epigastric region. A sharp tip of a single foreign body was palpable just below the puncture mark. There were no external injuries over rest of the abdomen. A plain abdominal radiograph showed three linear foreign bodies (*Fig. 1a*). On lateral films, the objects appeared to be intra-abdominal, traversing more than half of the depth of the abdomen (*Fig. 1b*). It then became clear that all three linear objects were inserted one after the other, through a single puncture site in epigastrium. A medicolegal case was registered. An exploratory laparotomy was undertaken and the first foreign body, identified as rusted sewing needle, was retrieved from the sub-hepatic region, entangled within the omentum. The other two, which were embedded deep within the liver parenchyma with just the tips on liver surface, were retrieved through a separate incision. Rest of the solid organs and bowel were normal. Postoperative period was uneventful and patient was discharged after completing medicolegal procedures.



**FIG. 1** Plain abdominal antero-posterior (a) and lateral (b) abdominal radiograph showing needles in abdominal cavity.

Although it is generally believed that child abuse is mainly a social issue, with heavy involvement of social workers and child protective services, these children often need to be primarily treated as trauma cases, as a large proportion of them have severe and life-threatening injuries [2]. Not only do they need complete evaluation of the presenting acute injury, but also the subtle underlying sub-acute and chronic injuries, which may increase the morbidity during their treatment. As often the injuries may be life threatening and hidden, it requires high degree of suspicion and timely intervention. Out-of-the-box thinking is required in order to tackle a peculiar clinical situation.

**\*MANISH KUMAR GAUR AND SANJAY GUPTA**

*Department of Surgery, University College of Medical Sciences  
and Guru Teg Bahadur Hospital, Delhi, India  
\*manish.gr1@gmail.com*

### REFERENCES

1. Kempe CH, Silverman FN, Steele BF, Droegemueller W, Silver HK. The battered-child syndrome. *JAMA*. 1962; 181:17-24.
2. Naik-Mathuria B, Akinkuotu A, Wesson D. Role of the surgeon in non-accidental trauma. *Pediatr Surg Int*. 2015;31:605-10.

## Hepatitis A with Superadded *Salmonella paratyphi A* Infection Presenting with Exudative Pleural Effusion and Acalculous Cholecystitis

Both hepatitis A and enteric fever are major public health problems in developing countries [1,2]. Transudative pleural effusion and ascites have been reported in hepatitis A but rare in enteric fever [3-5].

A 4-year-old girl presented to us with fever for 15 days along with jaundice, cough and dyspnea. Since day-8 of fever, child had multiple petechial rashes all over the body. There was no history of blood transfusion, intravenous drug use, tick bite, or contact with tuberculosis. There was no history of MMR, Hepatitis A, Hepatitis B or Typhoid vaccination. Chest examination revealed stony dull percussion note anteriorly over right side of chest starting from 2<sup>nd</sup> intercostal space downwards in mid clavicular line with absent breath sounds. Abdomen was distended, and there was tender hepatomegaly and mild splenomegaly. Other system examination was normal.