

Right Atrial Diverticulosis and Early-onset Arrhythmia: Rare Cause of Incessant Neonatal Arrhythmia

NEERAJ AGGARWAL, *RAJA JOSHI, *REENA K JOSHI AND MRIDUL AGARWAL

From Department of Pediatric Cardiology and *Pediatric Cardiac Sciences, Sir Ganga Ram Hospital, New Delhi, India.

Correspondence to:

Dr Neeraj Aggarwal, Consultant Pediatric Cardiology, Sir Ganga Ram Hospital, Rajender Nagar, New Delhi 110 060, India. drneeraj_12@yahoo.co.in.

Received: June 16, 2016;

Initial review: October 14, 2016;

Accepted: March 29, 2017.

Background: Atrial flutter not responding to medications could be secondary to structural malformations of heart. **Case characteristics:** A 5-year-old child with resistant arrhythmia, with onset in neonatal period. **Outcome:** Multiple right atrial diverticuli were detected on CT angiography and cardiac catheterization. Patient reverted to sinus rhythm following surgical excision of diverticuli. **Message:** In cases of intractable supraventricular tachycardia, structural anomalies of atrium should be suspected.

Keywords: Atrial Diverticulosis, Neonatal arrhythmia, Palpitation.

Right atrial diverticulum (RAD) is a rare structural abnormality with varied presentations from incidental cardiomegaly on chest X-ray/echocardiography to incessant arrhythmias. We present a child presenting with atrial flutter from neonatal age that was eventually diagnosed as due to right atrial diverticulosis, and was successfully treated by surgical resection of the diverticuli.

CASE REPORT

A 5-year-old boy presented to our facility as an outpatient with recurrent palpitations. Examination revealed a well-oriented, anxious looking child with a regular heart rate of 210/min and a blood pressure of 95/45(52) mm Hg. Electrocardiogram (ECG) showed typical saw tooth appearance suggestive of atrial flutter with fast ventricular rate. Past history revealed that he has been having such episodes dating back from the neonatal period. The first episode of supraventricular tachycardia was documented at 4 hours after birth. It was reverted with intravenous adenosine. Thereafter, there have been many similar episodes necessitating multiple visits to the emergency and outdoor departments of the local area. He had received various anti-arrhythmic medications for paroxysmal, intractable flutter with limited control. Trans-thoracic echo reported previously was normal.

During the present episode, there was no response to adenosine, therefore cardio version was planned. Preparatory to cardio-version, Trans-esophageal echo (TEE) was performed to rule out intracardiac thrombus. TEE revealed an abnormal septation in the right atrium (RA) communicating freely with the cavity without any intracardiac clots. At this point of time, differential

diagnosis of cor triatriatum dexter, RA aneurysm or RA diverticulum was entertained. CT angiogram showed finger like projections originating from RA suggesting the possibility of RA diverticuli. Cardiac catheterization was done with contrast injection showing multiple out-pouching from RA free wall suggestive of diverticulosis of RA (**Fig. 1**). After an informed consent from the parents, child was taken up for surgery. Prophylactic amiodarone was started in the operating room. Intra-operatively multiple diverticuli were seen in the right atrial free wall and appendage. Diverticuli were excised including RA appendage and surgical ablation of arrhythmogenic focus was performed. The rhythm reverted to sinus immediately after resection and stayed sinus thereafter. Child had uneventful postoperative period and got discharged on 4th post-operative day. Oral

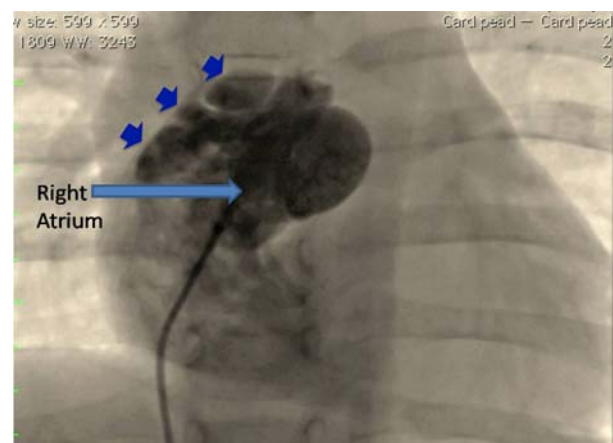


FIG.1 Catheterization image showing multiple out pouches (small arrows) from right atrium suggestive of diverticuli.

amiodarone was prescribed at the time of discharge which was weaned off over the next 6 weeks. After 18 months follow up, child is asymptomatic, and has a normal 24-hour Holter evaluation.

DISCUSSION

RA diverticulum is a rare anatomical abnormality and neonatal presentation of multiple RA diverticuli has not been described often. The etiology of these diverticuli is not clearly understood. There is a single case report of familial occurrence, although genetic preponderance is not established [1]. Shah, *et al.* [2] reported a neonate presenting with SVT and Wolff-Parkinson-White syndrome associated with a single RA diverticulum where the patient was managed medically [2]. Neonatal SVT is usually associated with a structurally normal heart. Incessant supraventricular tachycardia has been found to be associated with some of the structural malformations; the commonest being Ebstein's anomaly followed by cor-triatriatum dexter, congenital enlargement or aneurysm of right atrium and diverticuli of atria. These malformations present as cardiomegaly and atrial enlargement. Echocardiography usually can differentiate these anomalies, although in some instances further radiological investigation like MRI, CT angio, or cardiac angiography are required.

Binder, *et al.* [3] reviewed 103 cases of congenital malformations of RA and coronary sinus including four cases of multiple RA diverticuli, with three of these presenting with SVT. Minimum age at presentation of these patients was 5 months [3]. RA diverticuli causes SVT either by providing surface area for circus movements (Atrial re-entrant tachycardias) or by directly stimulating the cardiac surface (Ectopic atrial tachycardia). Surgical excision of diverticuli removes the substrate and cures the SVT. Patients usually do not have recurrence of arrhythmias after surgery.

It has been suggested that surgery should be offered to symptomatic patients and asymptomatic patients should be managed conservatively [3]. However, others feel that as there is a high risk of thrombus formation, arrhythmia and rupture of diverticuli in these patients, and also considering low operative mortality, asymptomatic patients should also be offered surgical treatment [4]. This is especially more true for diverticuli of coronary sinus and multiple diverticuli of RA who have high incidence of arrhythmias compared to RA aneurysm.

In cases of intractable SVT in neonates and infants, structural anomalies of atrium should be suspected and adequately evaluated with echocardiography and other radiologic modalities. Therapeutic outcomes are good in cases of RA diverticulum.

Contributors: NA: data acquisition and clinical study was performed; NA, RJ: manuscript preparation, editing, review and literature search; RKJ, MA: concept and design of study was done; NA, RJ: guarantor and take full responsibility and confirm the originality of the work performed. The manuscript has been read and approved by all the authors.

Funding: None stated. *Competing interest:* None stated.

REFERENCES

1. Jenni R, Goebel N, Schneider L, Krayenbuhl HP. Familial idiopathic dilatation des rechten Vorhofs. *Schweiz Med Wochenschr.* 1981;111:1565-72.
2. Shah K, Walsh K. Giant right atrial diverticulum: an unusual cause of Wolff-Parkinson-White syndrome. *Br Heart J.* 1992;17:874-82.
3. Binder TM, Rosenhek R, Frank H, Gwechenberger M, Maurer G, Baumgartner H. Congenital malformations of the right atrium and the coronary sinus. *Chest.* 2000; 117:1740-8.
4. Agematsu K, Okamura T, Ishihara K and Kurosawa H. Remarkable giant right atrial diverticulum in asymptomatic patient. *Interact Cardiovasc Thorac Surg.* 2009;8:705-7.