

Hair Thread Tourniquet Syndrome of Penis Causing Urethral Fistula

We report a six-year-old boy, who presented to the Emergency Department with history of poor urine stream and dysuria for one week. There was no history of fever or urinary retention. General physical and abdominal examination was normal. Local examination showed a tight band of hair around the shaft of penis in coronal sulcus causing a tourniquet-like compression (**Fig. 1**). The glans was engorged and the band of hair seemed to be buried into urethra ventrally.

The child was taken up for an emergency surgery under general anesthesia. The band of hair was identified and transected dorsally. A coronal urethral fistula was seen ventrally where tourniquet had eroded through (**Fig. 2**). Edges of the urethra were mobilised and closed in transverse fashion. Since the area at coronal sulcus was narrow, a soft tissue and penile skin advancement flap was fashioned from the lateral penile skin and advanced medially. A two layer suturing of the flap was done to cover the area of urethral repair and coronal sulcus to prevent the recurrence of fistula. An indwelling 8fr urethral catheter was left that was removed post-operatively after 7 days. At one year follow-up, the child was passing urine well without any complaints. No explanation could be offered by parents as to how the child developed hair thread tourniquet syndrome (HTTS). HTTS, described first in 1832, is a very rare entity [1,2].

Human hair is thin and supple and stretch in a wet state, but on drying up becomes tight and can lead to a constriction band. This constriction band causes ischemia in parts distal to the tourniquet thus formed [3]. HTTS may involve external appendages or external genital organs. Digital involvement is seen more frequently in infants [4] while genitalia are often involved in age group of 4-11 years. When HTTS involves the genitalia, the associated embarrassment may delay the clinic visit and may lead to complications such as urethral fistula, urethral transection, and penile gangrene or amputation

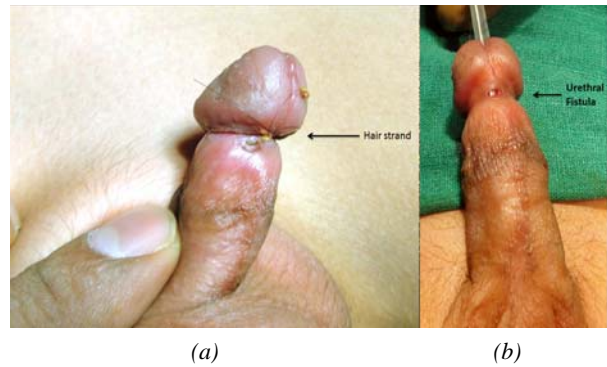


FIG. 1 Tourniquet-like compression of penis by hair (a); urethral fistula (b).

[5]. HTTS in penis is more commonly seen in circumcised boys [6], and they should be evaluated for HTTS if they present with penile or glanular swelling, gangrenous glans, or discharge from coronal sulcus. Removing the tourniquet with scissors or forceps under magnification or soaking body part in depilatory cream to weaken the fiber may release the tourniquet effect. Emergency surgery is needed in those with complications or failure of conservative treatment.

***ZARINE A GAZALI AND ARBINDER K SINGAL**
Rowhouse D1 Goldmine, Plot no. 138, Sector- 21,
Nerul east, Navi-Mumbai, Maharashtra, India.
*zarinegazali@gmail.com

REFERENCES

1. Abel MF, McFarland R. Hair and thread constriction of the digits in infants: A case report. *J Bone Joint Surg.* 1993; 75:915-6.
2. Claudet I, Pasian N, Debuissou C, Salanne S, Rekhroukh H. Tourniquet syndrome: Interest of a systematic analysis of families' social conditions to detect neglect situations. *Child Abuse Neglect.* 2009;33:569-72.
3. Bangroo AK, Smita C. Hair tourniquet syndrome. *J Indian Assoc Pediatr Surg.* 2005;10:55-6.
4. Golshevsky J, Chuen J, Tung PH. Hair-thread tourniquet syndrome. *J Pediatr Child Health.* 2005;41:154-5.
5. Badawy H, Soliman A, Ouf A, Hammad A, Orabi S, Hanno A. Progressive hair coil penile tourniquet syndrome: multicenter experience with 25 cases. *J Pediatr Surg.* 2010;45:1514-8.
6. Kirtane JM, Samuel KV. Hair coil strangulation of the penis. *J Pediatr Surg.* 1994;29:1317-8.