

Acalvaria

V.V. Khadilkar
A.V. Khadilkar
A.A. Nimbalkar
A.S. Kinnare*

Acalvaria is a rare congenital malformation in which the flat bones of the cranial vault, duramater and associated muscles are absent but the central nervous system is usually unaffected. Acalvaria has usually been described as a fatal anomaly and reports are rare in the Indian literature. We report a living case of acalvaria.

Key words: Acalvaria, Skull defect, Congenital malformations.

Acalvaria is a rare congenital anomaly of unknown pathogenesis in which the flat bones of the cranial vault, duramater and associated muscles are absent and the facial bones and the base of the skull are normally present with normal cranial contents(1). To date, acalvaria has been described as a fatal anomaly(2,3). We report an infant detected to have acalvaria.

Case Report

A 2-month-old full term boy, delivered normally, first issue of consanguineous marriage, was referred for an abnormally soft skull. Prenatal ultrasounds done at 12, 18, 32

From the Growth and the Pediatric Endocrine Unit, Hirabai Cowasji Jehangir Medical Research Institute, Jehangir Hospital, 32, Sassoon Road, Pune 411 001.

**Ultrasoundologist.*

Correspondence to: Dr. Vaman Khadilkar, Consultant Pediatric Endocrinologist, Hirabai Cowasji Jehangir Medical Research Institute, Jehangir Hospital, 32, Sassoon Road, Pune 411 001.

*Manuscript received: April 28, 2003;
Initial review completed: June 30, 2003;
Revision accepted: November 12, 2003.*

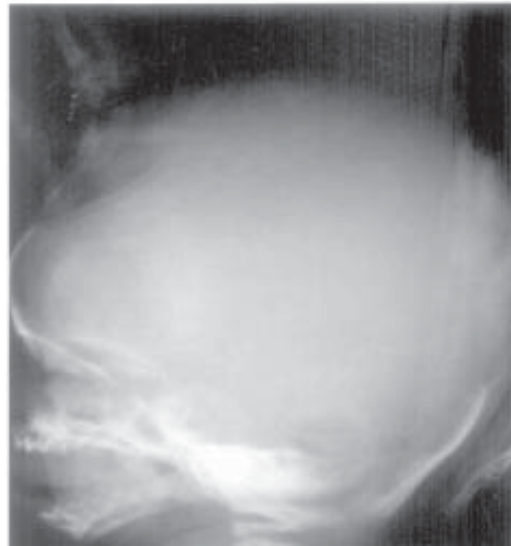


Fig. 1. Skull with absent parietal bones.

and 36 weeks were reported as normal. There was no history of ingestion of angiotensin converting enzyme (ACE) inhibitors during pregnancy. The baby was breast feeding well, had a social smile and normal milestones. On examination he weighed 5.25 kg and was 58 cm long; head circumference was 40 cm. On inspection the skull and face appeared normal but on palpation there was absence of the parietal bones. The facial bones were normal and extended to the supraorbital ridges; the frontal, temporal and occipital bones were well felt. The entire bony defect was covered with normal scalp and skin (Fig. 1). The rest of the physical examination was normal. An X-ray of the skull showed absence of the parietal bones with normal facial, frontal, temporal and occipital bones; the infantogram was normal. A CT scan of the brain showed normal intracranial structures, no ventricular dilatation and absence of the parietal bones. The serum calcium was 8.9 mg/dL (9-11 mg/dL), phosphorus was 4.5 mg/dL (3.5-5.5 mg/dL) and alkaline phosphatase was 265 IU/L (50-350 IU/L).

Discussion

Acalvaria is a rare congenital malformation distinguished by absence of the calvarium. The cranial contents are usually complete(1), as was seen in our case, though some neuropathological abnormality is often reported. Hypocalvaria is a condition in which the cranial bones are hypoplastic(4). Acalvaria may be associated with holoprosencephaly, hydrocephalus and micropolygyria. Cardiac anomalies, omphalocele, hypertelorism, cleft lip and palate, renal tubular dysgenesis, hexadactyly, club foot and congenital medulloblastoma have been reported(1,5).

The pathogenesis of acalvaria is not exactly known. Normally during embryological development, after the closure of the anterior neural pore around the fourth week, migration of the mesenchymal tissue under the ectoderm underlying the future cerebral hemispheres takes place. The ectoderm forms the skin and scalp, while the mesenchyma gives rise to the muscle and bone(6). The most accepted theory suggests that acalvaria is a postneurulation defect, that is, it results due to faulty migration of the mesenchyme with normal placement of the embryonic ectoderm. There is, thus, an absence of the calvarium but an intact layer of skin over the brain parenchyma(1). Other theories suggest that it results because of the primary non-closure of the neural tube or may be a part of a spectrum of anencephaly(7). Acalvaria has also been described with amniotic bands(8). The disorder is etiologically and pathogenetically heterogeneous and its prevention by ingestion of folic acid has not been described. Epidemiological survey suggest a female predilection. Though one mother has been reported with two consecutive pregnancies with fetal acalvaria, the condition is not believed to have a specific risk of recurrence(1). The diagnosis can be made by

the 12th week of gestation by high-resolution transvaginal ultrasonography(3). The sonographic differential diagnosis includes anencephaly, cephalocele, osteogenesis imperfecta and hypophosphatasia(1). During pregnancy the alpha-fetoprotein levels are reported to be very high, while the unconjugated estriol is undetectable.

Though our patient was born normally by spontaneous vaginal delivery, pressure on the head during labor and delivery may cause trauma. To date acalvaria has been described as a fatal anomaly. Ours is the second reported living case, the first being in Japan(9). As per our recent communication with the authors, the child reported from Japan is now 11 year old, and going to a special elementary school for disabled children. He is severely retarded and disabled.

No surgical procedures to correct the skull defect have been reported in the newborn period and infancy. Spontaneous bone growth has been seen in some newborns with scalp defects such as in cutis aplasia. Conservative management with a careful follow-up and bone grafting at school age have been recommended(10).

Contributors: VVK and AAN carried out the clinical workup. AVK, ASK and AAN collected the data and drafted the manuscript. VVK will act as guarantor of the study.

Funding: HCJMRI, Jehangir Hospital, Pune.

Competing interests: None stated.

REFERENCES

1. Harris CP, Townsend JJ, Carey JC. Acalvaria: a unique congenital anomaly. *Am J Med Genet* 1993; 46: 694-699.
2. Ekici E, Gulmezoglu AM. Sonographic diagnosis of fetal acrania. *J Clin Ultrasound* 1991; 19: 363-366.
3. Yang YC, Wu CH, Chang FM, Liu CH, Chien CH. Early prenatal diagnosis of acrania by

CASE REPORTS

- transvaginal ultrasonography. *J Clin Ultrasound* 1992; 20: 343-345.
4. Barr M, Coher MM. ACE inhibitor fetopathy and hypocalvaria. *Tetrolgy* 1991; 44: 485-495.
 5. Asai M, Kitamura H, yanagibashi T, Asukai K, Katagiri N. Case of acrania associated with congenital medulloblastoma. *Eur J Obstet Gynecol Reprod Biol* 1998; 81: 115-117.
 6. Singh I. *Human Embryology*, 6th edn. New Delhi, Macmillan India Limited, 1996; pp 128-130.
 7. Bar-Hava I, Bronshtein M, Ornoy A, ben-Rafael Z. First trimester sonographic diagnosis of acrania. *Harefuah* 1993; 124: 685-687.
 8. Chandra S, Lim MC, Yu VY. Fetal acrania with amniotic band syndrome. *Arch Dis Child* 2000; 82: F11-F13.
 9. Kurata H, Tamaki N, sawa H, Oi S, Katayama K, Mochizuki M, *et al.* Acrania: report of the first surviving case. *Pediatr Neurosurg* 1996; 24: 52-54.
 10. Bang RL, Ghoneim IE, Gang RK, Najjadah IA. Treatment dilemma: Conservative versus surgery in cutis aplasia congenita. *Eur J Pediatr Surg* 2003; 13: 125-129.
-