

- Unilateral pulmonary agenesis with esophageal atresia and distal tracheoesophageal fistula Report of two cases *J Pediatr Surg* 1989; 24: 1084-1086.
4. Sarin YK. Esophageal atresia and tracheoesophageal fistula with right pulmonary agenesis *Indian Pediatr* 1996; 33: 595-597.
  5. Stern R, Congenital anomalies. *In: Nelson Text Book of Pediatrics*, 15th edn. Eds. Behrman RE, Kliegman RM, Arvin AM. Philadelphia, W.B. Saunders Company, 1996, pp 1199.
  6. Herbst JJ. The esophagus *In Nelson Text Book of Pediatrics*, 15th edn. Eds. Behrman RE, Kliegman RM, Arvin AM. Philadelphia, W.B. Saunders Company, 1996, pp 1052-1053.
  7. Mackinlay GA. Neonatal surgery *In: ForFar and Arneils Text Book of Pediatrics*, 4th edn. Eds. Campbell AGM, McIntosh N. Edinburgh, Churchill Livingstone, 1992, pp 1850-1852.

## Paravertebral Extraosseous Ewing's Sarcoma

**T.P. Yadav**  
**R.P. Singh**  
**V.K. Gupta**  
**N.K. Chaturvedi\***  
**C. Vittal Prasad<sup>†</sup>**

Extra Osseous Ewing's Sarcoma (EES) has been considered a distinct clinicopathological entity despite its striking ultrastructural similarity to Ewing's Sarcoma of Bone (ESB) and same translocation involving band ql2 of chromosome 22(1,2) Today more than 150 cases of EES in different locations have been described, for example, larynx, scalp, nasal fossa, neck, chest wall, lung, perineum, finger, arm, lip and toe(3) Paravertebral location of EES

---

*From the Departments of Pediatrics, Pathology\* and Radiology\*, Dr. Ram Manohai Lohia Hospital New Delhi*

*Reprint Requests: Dr. T.P. Yadav, 16 LF Tansen Marg, Bengali Market, New Delhi 110 001.*

*Manuscript Received July 19, 1997  
 Initial review completed October 13, 1997,  
 Revision Accepted November 22, 1997*

have been extremely rare To the best of our knowledge EES located in paravertebral area has not been reported in Indian literature We report one such case

### Case Report

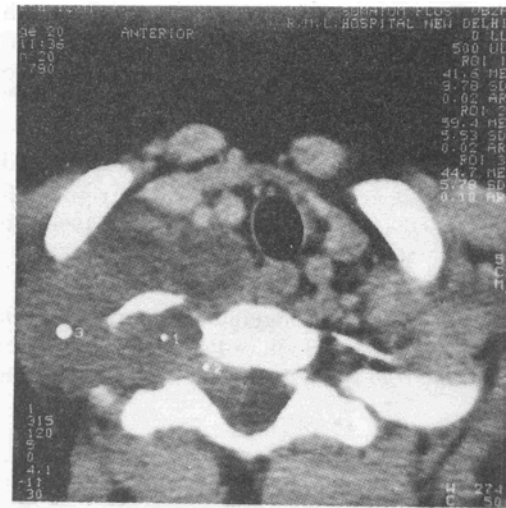A 12-year-old male child was admitted with the complaints of progressively increasing dull aching pain in the upper back and right shoulder, radiating to the right hand since last two months and progressive weakness of his right upper limb since last one month Around the same time he noticed a painless swelling in the right side of neck which was slowly increasing in size There was history of loss of appetite and weight, however, he did not suffer from headache, vomiting, visual disturbance, dysphagia, dyspnea or disturbance of gait He was a thin built pale child Examination of central nervous system revealed weakness (power 3/5) and hypotonia of right upper limb The biceps, the triceps, and supinator reflexes in right upper limb were elicitable with difficulty The thenar and hypothenar eminences were significantly wasted and there was no sensory loss Rest of the systemic examination did not reveal any abnormality There was

restriction of anterior flexion and lateral bending of neck. A soft noncystic, nontender swelling was palpable in the right supraclavicular region measuring 2 x 2 cm. It was fixed to the underlying structures. The skin over the swelling was freely mobile. There were no signs of inflammation. No bruit was heard over the swelling.

Investigation revealed a haemoglobin of 12 g/dl, total leukocyte count of 9500 cells/cu mm with 63% polymorphs and 32% lymphocytes and ESR of 65 mm in the first hour. The urine examination for albumin, sugar, VMA and HVA did not reveal any abnormality. There was no reaction to 5TU of PPD. The skiagram of chest and cervical spine revealed a soft tissue shadow on right side in the apical area without any area of bone destruction.

The ultrasonographic examination of abdomen did not reveal any abnormality. The examination of bone marrow aspirate also did not show any abnormal cells. The CT scan of neck and upper thorax showed a large soft tissue mass with sharp margin and some degree of contrast enhancement inside the mass, anterolateral to the seventh cervical vertebral body, encroaching through the thoracic inlet and extending upto the body of second thoracic vertebra. There was destruction of right transverse process of seventh cervical and second thoracic vertebrae. The mass was extending into the intraspinal area pressing the spinal cord at the level of seventh cervical vertebra. Some amount of tracheal shift toward the left was also seen (*Fig. 1*). MRI of cervical and upper thoracic area substantiated the finding of CT scan.

Fine needle aspiration cytology and histopathology of the mass in the neck revealed tissue composed of densely packed small cells with round nuclei, scanty to



*Fig. 1. The CT Scan of neck and upper thorax showing a mass encroaching through the thoracic inlet and shifting trachea to the left. The same mass is extending into the intraspinal area.*

clear cytoplasm with occasional mitosis at places (*Fig. 2*). Fibrous band was seen dividing tumor tissue in irregular planes. Vascularization was prominent and occasional pseudorosettes were seen. Reaction to PAS was highly positive. The picture was highly suggestive of Ewing's sarcoma.

A diagnosis of Extra Osseous Paravertebral Ewing's Sarcoma with intraspinal extension with no lymph node involvement or distant metastasis (G3 T3 No Mo), *i.e.*, stage IV of TNMG classification was made.

The patient was given chemotherapy followed by radiotherapy. The chemotherapy consisted of VACA regimen which comprised of injection Vincristine (1 mg/dose), Injection Cyclophosphamide (200 mg/dose) given on day 1 of every week and injection Adriamycin (30 mg/dose) and Injection Actinomycin-D (0.5 mg/dose) given on day one of alternate week.

The total duration of this regimen was 30 weeks after which 20 sittings of radiotherapy were given in dose of 20 cGY per sitting (total dose 400 cGY). The patient tolerated chemotherapy and radiotherapy well without any untoward happening. The patient became asymptomatic, the swelling was not visible and features of cord compression disappeared completely. Repeat CT showed a decrease in the soft tissue mass. After a five month symptom free period, he developed fullness in right supraclavicular region again. CT scan and MRI repeated, revealed a lobulated soft tissue mass extending from seventh cervical vertebra to the third thoracic vertebra and extending intraspinally at level of sixth and seventh cervical vertebrae. The transverse process and upper half of lamina of C 6, 7 and T1 were destroyed partially by mass lesion. The chemotherapy (VACA regimen)

was started again. After receiving two cycles, he did not report back.

### Discussion

EES like ESB is a poorly differentiated, highly malignant round cell tumor without cellular structural differentiation, with early and high degree of metastasis and has an aggressive clinical behavior with high rate of local recurrence and distant metastasis(1-4). It has been reported to originate from different sites, namely, trunk (32%), extremity (26%), head and neck (18%), retroperitoneum and pelvis (16%) and others (10%)(4,5). Paravertebral origin of EES has been extremely rare. To the best of our knowledge no such case has been reported from Indian literature and only few cases have been reported world wide(6,7).

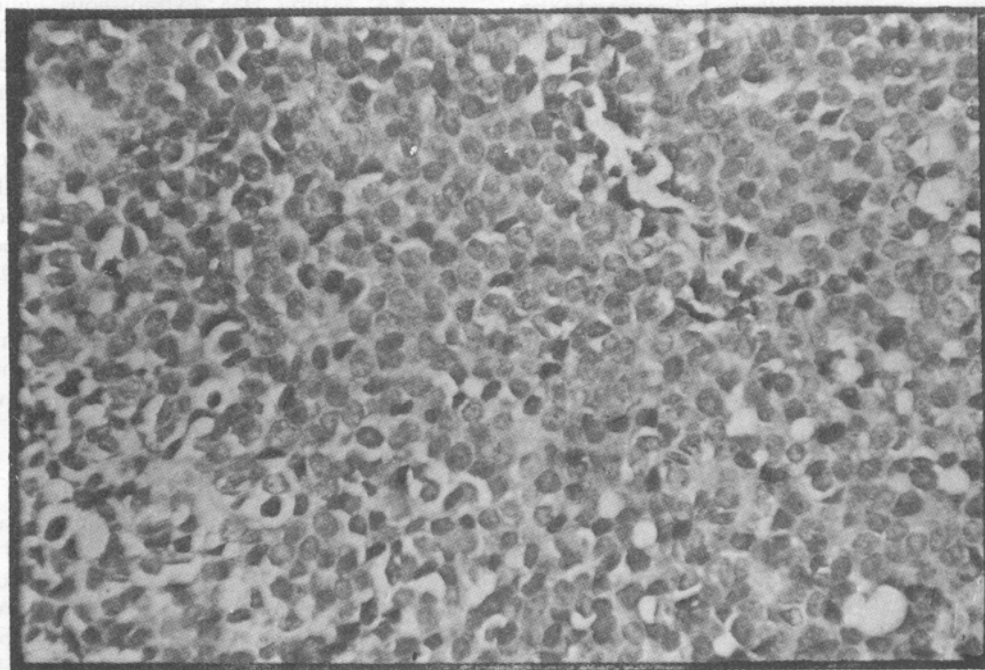


Fig. 2. Microphotograph showing round monomorphic tumor cells with scanty cytoplasm, indistinct borders and hyperchromatic nuclei (H & E -x400).

The clinical features in such cases are mainly local swelling, radicular pain and features of cord compression. In such patients other causes of compression of spinal cord/nerve root need to be ruled out, for example, benign extra and intradural tumor like neurenteric cyst, lipoma, angioma, meningioma, neurofibroma, dermoid cyst, abscess, acute leukemia, lymphoma, metastasis, malignant tumor of vertebrae and disc protrusion. Differentiation between all these causes is possible by careful history taking, examination, imaging studies and histopathology.

The origin of EES and EEB has been a matter of research since the time James Ewing described the first case of ESB in 1921. The recent findings like presence of Homer-Wright like rosette, neurosecretory granules, microtubules, positive staining with neural markers, same chromosomal translocation t(11;22) (q 24; q12) suggest the possibility of these belonging to the same group of peripheral primitive neuroectodermal tumors (6,7).

The aim of treatment in such patients is complete removal/destruction of tumor tissue, complete restoration of function of part without recurrence. Multi-modal treatment strategies including surgery, radiotherapy and chemotherapy have been the main-stay of treatment depending on the stage and site of tumor with variable response and relapse rates(3,4,5,8). Our patient was subjected to chemotherapy and radiotherapy. He had complete neurological recovery but local recurrence occurred within 5 months. Although studies using VACA regimen along with radiotherapy in treatment of EES have shown a complete response in 80% of cases, the relapse rates have been high (42%) which are still higher in para vertebral EES (55%)(4,5,8).

Paravertebral EES carries a poor prognosis and may require more extensive field radiation and more intensive chemotherapy to achieve better local and systemic tumor control(8).

#### REFERENCES

1. Tefft M, Vawter GF, Mitus A. Paravertebral "round cell" tumors in children. *Radiology* 1969; 92:1501-1509.
2. Angervall L, Enzinger FM. Extra skeletal neoplasm resembling Ewing's Sarcoma. *Cancer* 1975; 36: 240-251.
3. Kasper GJL, Kamphorst W, Van de Graaff M, Van Alphen AM, Veerman AJP. Primary spinal epidural extra osseous Ewing's Sarcoma. *Cancer* 1991; 68: 648-654.
4. Rud NP, Reiman HM, Pritchard DJ, Frassica FJ, Smithson WA. Extrasosseous Ewing's Sarcoma-A study of 42 cases. *Cancer* 1989; 64:1548-1553.
5. Raney RB, Asmar L, Newton WA, Gehan EA, Maurer HM. Extrasosseous Ewing's Sarcoma (EOE) in childhood: The Intergroup Rhabdomyosarcoma study experience. *Proc Ann Meet Am Soc Clin Oncol* 1994; 13:1418.
6. Ambros IM, Ambros PF, Strehl S, Kovar H, Gadner H, Salzn-Kuntoschil M. MIC-2 is a specific marker for Ewing's Sarcoma and Peripheral Primitive Neuroectodermal tumors. *Cancer* 1991; 67:1886-1893.
7. Ladany M, Heinemann FS, Huvos AG, Hanumantha Rao P, Chen Q and Jhanwar SC. Neural differentiation in small round cell tumor of bone and soft tissue with the translocation t(11;22) (q 24; q12): An immunohistochemical study of 11 cases. *Human Pathology* 1990; 21:1245-1251.
8. Ortega JA, Wharam M, Gehan EA, Ragab AH, Crist W, Webber B, *et al.* Clinical features and results of therapy for children with paraspinal soft tissue sarcoma: A report of the Intergroup Rhabdomyosarcoma Study. *J Clin Oncol* 1991; 9: 796-801.