

---

**Brief Reports**

---

**Adreno-Cortical Tumors: Clinico-Pathological Profile of Five Cases**

**Gaurav Agarwal**  
**S.K. Mishra**  
**Amit Agarwal**  
**Vijayalakshmi Bhatia**

In children, upto two-thirds of all adreno-cortical neoplasms present with virilization with or without hypercortisolism(1). These tumors may however remain non-functioning or may present with varying symptom complexes including feminization and hyperaldosteronism(2). The clinical and biochemical features of five children with adreno-cortical neoplasms presenting over a period of five years (1991-1995) and a brief review of literature are presented here.

**Patients and Methods**

Five children with adreno-cortical tumors treated at our center during 1991 to 1995 were the subjects of this study. Plasma cortisol was measured by commercial radio-immuno assay (RIA) with the normal AM range being 138-698 nmol/L (5-24 µg/

dl). Serum testosterone was measured by RIA and its normal values were <0.3 nmol/L (<10 µg/dl) for pre-pubertal age groups and 10-34 nmol/L (300-1000 µg/dl) for adult males. Non-suppression of plasma cortisol to <5 µg/dl by low-dose Dexamethasone Suppression Test (DST) (20 µg/kg/day) was considered confirmatory of hypercortisolism(3). Suppression of plasma cortisol to <50% of baseline by high-dose DST (80 µg/kg/24) was considered indicative of Cushing's disease of pituitary origin(4). Abdominal USG and CT were used for imaging of the adrenal glands. The diagnosis of Cushing's syndrome due to adreno-cortical tumor was based on non-suppressible low and high-dose DST together with visualization of unilateral adrenal mass. Patients were subjected to unilateral adrenalectomy with perioperative cortico-steroid and prophylactic antibiotic coverage.

On the day of surgery, a total of 150 mg/m<sup>2</sup> hydrocortisone was given, partly as continuous intravenous infusion and partly as intramuscular injections. This was tapered over 3-4 days. Oral prednisolone 7.5 mg/m<sup>2</sup>/day was started from 2nd postoperative (PO) day and tapered to 2.5 mg/m<sup>2</sup>/24 h by 15th PO day, and was continued till the recovery of suppressed hypothalamic-pituitary-adrenal (HPA) axis. This was tested at the end of 3 months and 3 months thereafter by short ACTH stimulation test(4).

One of the male patients presented with iso-sexual precocious puberty due to untreated congenital adrenal hyperplasia (CAH, 21-hydroxylase deficiency). Abdominal USG and CT detected bilaterally enlarged adrenal glands and a left adrenal

---

*From the Departments of Surgical and Medical Endocrinology, Sanjay Gandhi P.G.I.M.S., Raebareli Road, Lucknow 226 014.*

*Reprint requests: Dr. S.K. Mishra, Additional Professor and Head, Department of Surgical Endocrinology, Sanjay Gandhi P.G.I.M.S., Raebareli Road, Lucknow 226 014.*

*Manuscript received: July 2, 1996;*

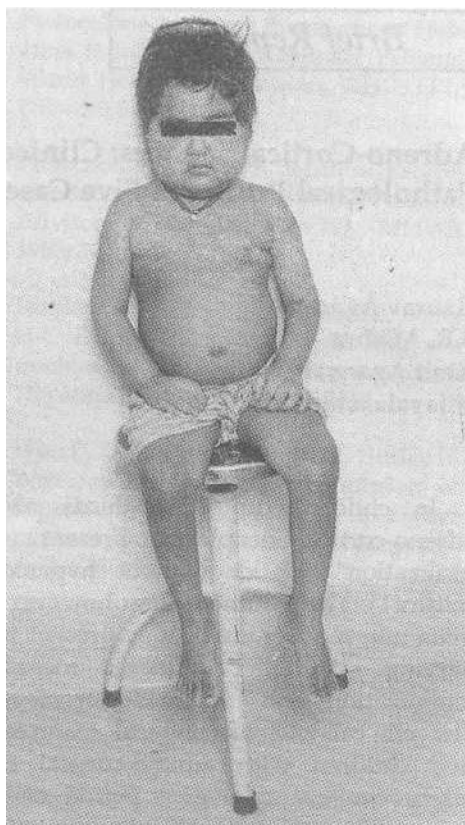
*Initial review completed: August 22, 1996;*

*Revision accepted: September 11, 1996*

tumor. The tumor was monitored for continuing growth by serial USG while the patient was being treated with suppressive doses of prednisolone (2.5 mg, twice daily) for CAH. At the end of 3 months, the tumor showed an increase of 0.5 cm in size, and hence a decision for left adrenalectomy was taken. Postoperatively, the patient is being treated with prednisolone and is on regular follow-up with periodic serum testosterone estimation.

### Results

During the five years period from 1991 to 1995, five pediatric patients of adrenocortical neoplasms were managed at our center. The age of patients at presentation ranged from 10 months to 16 years, male-female ratio being 2:3. All the five cases presented with features of virilization, and four had Cushing's syndrome. The duration between appearance of symptoms and diagnosis varied from two months to three years. *Table I* shows the clinical features of the patients. The typical appearance of a child is shown in *Fig. 1*. None of the patients had evidence of metastatic disease at presentation. The plasma cortisol and testosterone values, results of low and high-



*Fig. 1. Truncal obesity, moon facies and acne (case 1)*

**TABLE I**—*Summary of Clinical Features.*

Clinical Feature	Case 1	Case 2	Case 3	Case 4	Case 5
Age/sex	6yr/F	6yr/F	10mo/F	16yr/M	5yr6mo/M
Obesity	+	+	+	+	—
Weight gain	+	+	+	+	—
Facial plethora	—	+	+	—	—
Easy bruisability	+	+	+	+	—
Abdominal striae	—	+	+	+	—
Virilization	+	+	+	+	+
Growth-retardation	+	—	—	+	—
-acceleration	—	—	—	—	+
Hypertension	+	—	—	+	—
Glucose intolerance	—	—	—	—	—
Psychological changes	—	—	—	+	—
Proximal weakness	+	—	—	+	—

dose DST and adrenal imaging are given in *Table II*. All patients with Cushing's syndrome (cases 1 to 4) had non-suppressing low-dose and high-dose DST. One patient (case 5) had an adrenal adenoma complicating untreated 21-hydroxylase deficiency. He had raised serum 17 a OHP (186.6 nmol/L, normal <3 nmol/L) and serum testosterone (24.73 nmol/L) levels, which were suppressed partially after one week of prednisolone therapy. His overnight DST was normal. Abdominal USG and CT scan could successfully image the tumor in all five patients. A diagnosis of adreno-cortical carcinoma was suspected in three patients (Cases 1, 2 and 4) due to evidence of gluco-corticoid as well as androgen hypersecretion, and large tumor size with necrosis and calcifications (*Fig. 2*) as seen on CT scan.

Patient numbers 1 to 3 and 5 underwent successful unilateral adrenalectomy using a transperitoneal approach, while one patient refused surgery. The operative and histological findings, and the outcome of surgery are summarized in *Table III*. Patients 1 to 3 showed good clinical improve-

ment and regression in serum cortisol and testosterone levels in early postoperative period. No adjuvant chemotherapy or radiotherapy were given to patients with adreno-cortical carcinomas. Patients 1 and 2 with carcinoma presented with metastatic disease 12 and 14 months after surgery and died soon-after. Neither of them were given o,p'DDD (mitotane) due to non-affordability and high toxicity of this drug. They were started on ketoconazole for amelioration of features of glucocorticoid excess, which had re-appeared.

### Discussion

The first case of adreno-cortical tumor in a child was reported in 1865. A review of literature in 1966 revealed 222 cases of adreno-cortical tumors in children(1) and a review of about 300 cases was reported in 1985(2). The incidence of functioning adreno-cortical tumors in children is low in most parts of world, except in southern Brazil(5). Majority of adrenal tumors in children are neuroblastomas, and cortical tumors constitute only a small proportion(6). Female preponderance has been observed by most authors(1). Three of the

**TABLE II -Biochemical and Radiological Observations.**

SI. No.	S. Cortisol (nmol/L)	S. Testo (nmol/L)	Low dose DST	High dose DST	Abdominal USG	Abdominal CT
1.	1027.86	17.36	non-suppressed	non-suppressed	Lt. adrenal mass 5x4.5x3.7 cm	Lt. adrenal mass with necrosis
2.	987.6	—	non-suppressed	non-suppressed	Lt. adrenal mass 3.7x4.9 cm	Lt. adrenal mass with necrosis, calcification
3.	1104	19.08	non-suppressed	non-suppressed	Lt. adrenal mass mass 3x4 cm.	—
4.	916.4	32.8	non-suppressed	non-suppressed	Rt. adrenal mass 5x6 cm + LN	CT of head normal
5.	—	24.73	—	—	Lt. adrenal mass 2.8x2.5 x 2.6 cm	Lt. adrenal mass+B/L adrenal hyperplasia

Testo=testosterone; Lt.= left; Rt= right; LN- lymph node.

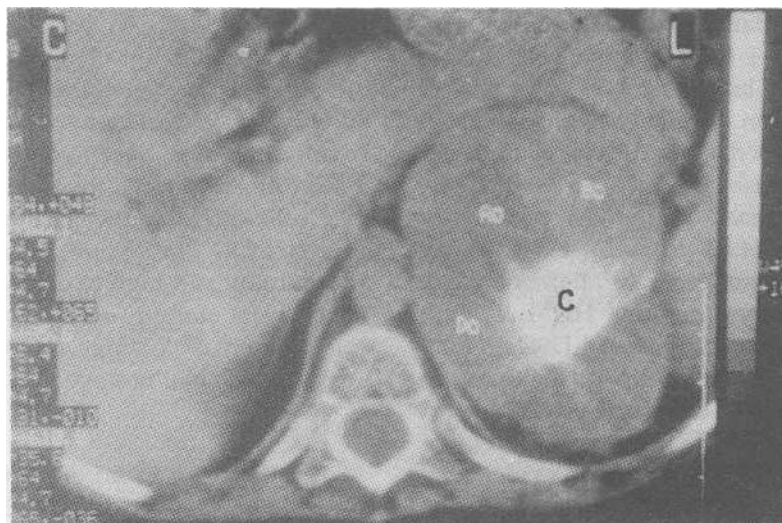

Fig. 2. Abdominal CT scan showing left adrenal tumor with calcification(C), suggestive of malignancy (Case 2).

TABLE III—Operative Findings, Histopathology, and Outcome of Operated Patients.

	Operative findings	Histopathology	Outcome
Case 1.	6x5x5cm Lt. adrenal, 32g, contiguous invasion/LN	Pleomorphism, vascular and capsular invasion, carcinoma.	Died 12 months post-op, no liver and lung metastases.
Case 2.	4x5 cm left adrenal, 35 g, unclear margins.	Pleomorphism, vascular and capsular invasion, carcinoma.	Died 14 months post-op, liver metastases.
Case 3.	2.2x3.8 cm, 12 g, well-circumscribed tumor in left adrenal gland.	Pleomorphism, no vascular or capsular invasion, adenoma.	Alive and well at 18 mo post-op, no evidence of disease, normal serum cortisol.
Case 5	6x4x2 cm left adrenal, 25g.	Minimal pleomorphism & mitotic figures, no vascular or capsular invasion. Hyperplasia of adjacent adrenal cortex.	Alive and well at 60 mo post-op, normal serum testosterone,

five patients in our study were females. In the pediatric age group, most patient of functioning adreno-cortical neoplasms present below the age of 5 years(2), though in the present group only one was less than 5 years of age.

Adreno-cortical neoplasms in child-

hood usually manifest as virilization with or without hypercortisolism. Patients presenting with abdominal masses only or with feminization, gynecomastia or hyperaldo-steronism have been reported occasionally. Cushing's syndrome in childhood is uncommon, and its commonest

cause is an adreno-cortical tumor(2). All our patients of Cushing's syndrome showed classical features such as truncal obesity, moon facies and skin lesions. Growth retardation was the presenting complaint in case 4 and was also seen in Case 1. Growth arrest could have been masked by androgen induced growth stimulation in others. Clinical suspicion of Cushing's syndrome merits careful clinical and hormonal evaluation. Overnight DST and 24 hour urinary free cortisol are useful screening tests. Lack of suppression by low-dose DST for confirmation of hypercortisolism has a sensitivity of 100% using urine free cortisol and 81% using plasma cortisol measurements(7). High dose DST has been the standard test for distinguishing Cushing's disease from ectopic ACTH syndrome and non ACTH dependent causes of Cushing's syndrome, with a sensitivity and specificity of approximately 90%(7). Serum DHA, DHAS, 17a OHP and testosterone are useful in the evaluation of virilization.

The fifth patient in this series had an adrenal tumor consequent to untreated CAH at an early age. Both adenomas and carcinomas have been reported with untreated CAH, hence it is important not to miss underlying CAH in some of the patients with adreno-cortical tumors. Presence of hyperplasia in contralateral adrenal may be helpful in diagnosing CAH. Adrenalectomy is indicated if serial imaging shows growth in tumor size, or if there is suspicion of carcinoma based on size of >6 cm, presence of calcification, necrosis, or enlarged lymph nodes(8).

Imaging studies help in confirming the diagnosis and in localizing an adrenal tumor. Abdominal USG can be useful for imaging of large tumors. MRI of adrenals offers no advantage over CT(9). Arterio and venographic studies are not always indicat-

ed. More than 92% of symptomatic adrenal carcinomas are larger than 6 cm in size(10). Several recent articles have reported that adrenal carcinomas may have specific biochemical profiles that distinguish them from adenomas. Most studies address the problem of incidentally diagnosed adrenal masses in patients with CAH, which is probably the commonest cause of adrenal tumors in children(8).

The only effective definitive therapy for adrenal neoplasms is surgical resection. In the presence of a hyperfunctioning adrenal gland or neoplasm, the contralateral gland is suppressed, making peri- and postoperative replacement with corticosteroids essential, till the time the suppressed adrenal resumes its function. Mineralo-corticoid replacement is seldom required in patients undergoing unilateral adrenalectomy. Recovery of the HPA axis is tested for by short ACTH stimulation test at 3 months and periodically as indicated. As is true for all endocrine tumors, the differentiation of adreno-cortical adenoma from carcinoma is difficult. Large tumor size, presence of calcification, necrosis and metastases to lymph nodes and distant sites are suggestive of malignancy. Histologically, cellular pleomorphism and capsular invasion may be found even in benign tumors(11). Carcinomas of the adrenal cortex usually spread by contiguous invasion into kidney or by metastatic spread to lymph nodes, lungs and liver. Both our patients with adreno-cortical carcinoma did not have invasive or metastatic disease at primary surgery, yet, both developed multiple hepatic metastases, while one also developed bilateral pulmonary metastases in the following year, indicating the generally poor prognosis. Radiotherapy has its limitations in these cases(2). Chemotherapy using o,p DDD (mitotane) alone or along with streptozotocin, has been advocated by many and

has been shown in some patients to result in tumor regression(12). However, high incidence of side effects, poor tolerance and high cost often preclude its use.

The results of surgery in terms of reversal of the virilizing and Cushingoid features seem to be good, and all operated patients in this series improved in the postoperative period. There is paucity of literature commenting on the prognosis. In a review of 222 cases, out of 127 children with known outcome, only 23 survived more than 2 years, though only 34 died of tumor recurrence(1). Many of the deaths in the older literature are reported due to postoperative complications or inadequate steroid supplementation. Most tumors which recur, do so within the first two years of surgery, as seen in our patients. In view of the malignant potential of adrenal tumors, and the significant metabolic consequences of gluco-corticoid hypersecretion, early recognition and management of adrenal tumor seem to be of importance for a favorable outcome.

#### REFERENCES

1. Hayles AB, Hanh HB, Sprague RG, Bahn RC, Prestley JT. Hormone secreting tumors of the adrenal cortex in children. *Pediatrics* 1996; 37:19-25.
2. Lee PDK, Winter RJ, Green OC. Virilizing adreno-cortical tumors in childhood: Eight cases and a review of the literature. *Pediatrics* 1985; 76: 437-444.
3. Liddle GW. Tests of pituitary-adrenal suppressibility in the diagnosis of Cushing's syndrome. *J Clin Endocrinol Metab* 1960; 20:1539-1560.
4. May ME, Carey RM. Rapid adrenocorticotrophic hormone test in practice. *Am J Med* 1985; 79: 679-684.
5. Sabbaga CC, AVilla SG, Schulz C, Garbers JC, Blucher D. Adreno-cortical darcinoma in children: Clinical aspects and prognosis. *J Pediatr Surg* 1993; 841-843.
6. Stewart DR, Moris Jones PH, Jolleys A. Carcinoma of the adrenal gland in children. *J Pediatr Surg* 1974; 9: 59-67.
7. Leinung MQ Zimmerman D. Cushing's disease in children. *Endocrinol Metab Clin North Am* 1994; 23: 629-639.
8. Lightner ES, Levine LS. The adrenal incidentaloma- A pediatric perspective. *Am J Dis Child* 1993; 147:1274-1276.
9. Findling JW, Doppman JL. Biochemical and radiologic diagnosis of Cushing's syndrome. *Endocrinol Metab Clin North Am* 1994; 23: 511-537.
10. Ross NS, Aron DC. Hormonal evaluation of the patient with an incidentally discovered adrenal mass. *N Engl J Med* 1990; 323:1401-1405.
11. Hough AJ, Hollified JW, Page DL, Hartmann WH. Prognostic factors in adrenal cortical tumors. *Am J Clin Pathol* 1979; 72: 390-399.
12. Eriksson B, Oberg K, Curstedt T, Hemmingsson A, Johansson H, Lindh E, *et al.* Treatment of hormone producing adreno-cortical cancer with o,p, DDD and streptozocin. *Cancer* 1987; 59:1398-1403.