

## EXPERIENCE WITH BRAIN ABSCESSSES

---

S. Malik  
S.M. Joshi  
P.W. Kandoth  
U.S. Vengsarkar

### ABSTRACT

*Brain abscesses were studied in 47 patients. Thirty-four (72%) of them were between 5-15 years and 9 were infants. Orogenic source (34%) was the commonest predisposing factor, followed by scalp and face infection (21.3%) and congenital cyanotic heart disease (12.8%). Twenty (42%) patients had multiple abscesses. Supratentorial abscesses were commonest (75.9%). Predominant clinical features were fever (87.2%), raised intracranial tension (78.7%) and altered sensorium (53.2%). A total of 38.3% presented with focal neurological deficit and 34% were admitted in Grade III or IV coma. Diagnosis of abscess and monitoring of its evolution was done principally by CT scanning. Causative organisms were isolated in 54.8% of cases and Staphylococci, Proteus and Pseudomonas were the common pathogens. Therapy was most often a combination of surgical aspiration with or without excision in addition to antimicrobial therapy. The overall mortality in our series was 44.7%. Bad prognostic factors were Grade III/IV of coma at admission, age below 2 years and multiple abscesses.*

**Key words:** Brain abscess, Aspiration, Excision, Computed tomography.

---

*From the Departments of Pediatrics and Neurosurgery, T.N. Medical College and B.Y.L. Nair Hospital, Bombay 400 008.*

*Reprint requests: Dr. Sushma Malik, 3/7 Brady's Flats, Colaba, Bombay 400 005.*

*Received for publication: February 4, 1993;*

*Accepted: December 12, 1993*

Despite many advances in diagnostic and neurosurgical techniques and the advent of newer antibiotics, the mortality and morbidity associated with brain abscess remains distressingly high. It is a potentially curable condition, but the outcome is often poor due to difficulty in early diagnosis and ability of the abscess to act as a space occupying lesion. We present our 5 year experience of 47 consecutive cases of brain abscesses.

### Material and Methods

At our institution between 1987-1991 we had 47 cases of brain abscesses. The clinical data including neurological status were noted carefully and assessed throughout hospital stay. Management included appropriate antibiotics, anti-convulsants, measures to reduce cerebral edema and surgical drainage.

Besides factors like size, location, multiplicity of abscesses and the clinical course of patient, the neurological status was the most important determinant for selecting the surgical mode. In well encapsulated and less fulminant abscesses, excision was preferred. Prior aspiration was necessary in those abscesses with intense surrounding edema. Aspiration alone was done in abscesses located in sensorimotor or speech cortex, thin walled abscesses and in cases with congenital cyanotic heart disease.

### Results

We observed a slight preponderance of males with M : F ratio of 3 : 2. A majority of the children 34/47 (72%) were above 5 years but as many as 9 cases (19%) were infants, the youngest being 2 months old.

The primary focus of infection could be established in 37 cases (78.7%) and otogenic source was the commonest seen in 34% (Fig. 1).

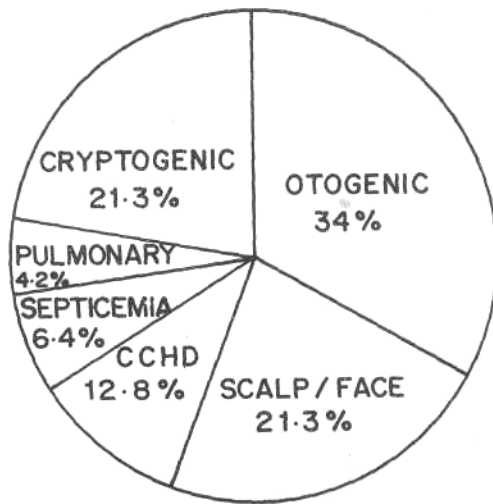


Fig. 1. Depicts primary source of infection. Oto-genic 34%; Scalp/face infections 21.3%; CCHD (Congenital cyanotic heart disease) 12.8%; Septicemia 6.4%; Pulmonary 4.2%; Cryptogenic 21.3%.

The three most common presenting features were fever in 40 cases (87.2%), raised intracranial tension in 37 cases (78.7%) and altered sensorium in 25 cases (53.2%). The other features were as depicted in Fig. 2.

Solitary abscesses were present in 27 (57.5%) patients and 20 (42.5%) had abscesses at multiple sites. Three fourths (75.9%) of abscesses were supratentorial and the temporal lobe was most frequently involved. Cerebellum was involved in 13 patients and in 66.7% of these it was following an otogenic source.

CT scan was a very sensitive diagnostic tool and was positive in 36/37 patients. The findings ranged from cerebritis/cerebellitis in 6 cases (16.6%) to well defined ring enhancing lesions in 31 (86.5%) and subdural

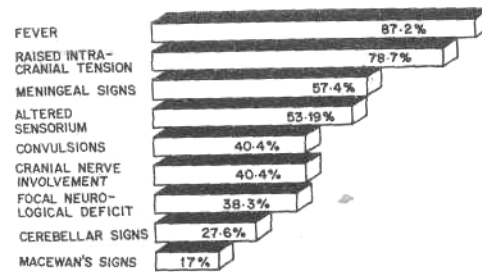


Fig. 2. Depicts major symptoms and signs on admission. Fever 87.2%; Raised intracranial tension 78.7%; Meningeal signs 57.4%; Altered sensorium 53.2%; Convulsions 40.4%; Cranial nerve involvement 40.4%; Focal neurological deficit 38.3%; Cerebellar signs 27.6%; Macewan's signs 17%.

empyema in 4 (10.8%). Hydrocephalus, cerebral edema and periventricular lucencies were additional findings on CT scan. In one case, CT revealed only meningitis and mastoiditis and diagnosis of abscess was confirmed at postmortem. Carotid angiography was used to delineate the abscesses in 2 patients. In the remaining 8 patients who were clinically suspected to have brain abscesses and had been receiving vigorous antibiotic and supportive therapy but could not be transported for CT scan due to their moribund state, the diagnosis was subsequently confirmed at postmortem.

Follow-up CT scan was possible only in 15 patients. Resolving abscesses were seen in 7, increase in size/new lesion in 4 and static lesion in another 4. The latter group required surgical excision in view of their clinical status. Lumbar puncture confirmed meningitis in 15 out of 30 patients and the procedure proved fatal in one case. Isolates from the pus aspirated in 31 patients were

positive in 17 (54.8%). The common organisms isolated were *Staphylococci* (35.3%), *Proteus* (29.4%) and *Pseudomonas* (23.5%).

Surgical drainage remained the mainstay of management though conservative medical therapy alone was successful in 5 patients (Table I). The mortality was higher in patients with aspiration alone (36.4%) as compared to those who underwent excision (15%). Eleven patients could not be subjected to surgery in view of their poor general condition, and died shortly after.

The overall mortality in our series was 44.7%, and was related to the grade of coma on admission (Table II). Presence of

multiple abscesses and age below 2 years were also associated with a higher mortality. In addition presence of septicemia and bronchopneumonia in 3 patients proved fatal.

**Discussion**

Brain abscess is a common form of intracranial purulent collection(1) and its early diagnosis and successful treatment in children still remains a clinical challenge. Although the incidence of brain abscesses in India is not well documented, studies reported in Indian literature(2,3) and the present one have noted an average incidence of 8-9 cases/year in hospitalized children. This incidence is much higher than that noted in developed countries(4,5).

Children of all age groups are vulnerable to brain abscess, but in infants the diagnosis is often either delayed or missed(6-8). Our study had 19.1% infants and the largest number of cases were between 5-15 years. Prakash and Mehta have also reported similar figures(2). Male preponderance reported in other series(4,9) was only marginally observed in our study group.

It is reported that 4-30% of brain

**TABLE I—Outcome of various modes of therapy**

Treatment	No. of patients	Deaths
<b>I. Surgical</b>		
(a) Aspiration	11	4 (36.4%)
(b) Excision		
Primary	6	1 (16.7%)
Secondary	14	2 (14.3%)
		] 15%
<b>II. Conservative</b>	5	0 (0)

**TABLE II—Mortality in Relation to Neurological Status (On Admission)\***

Grade	Total patients	Mortality	
		Number	%
Grade I	Conscious and oriented	22	6 27.2
Grade II	Drowsy, responding to commands	9	4 44.4
Grade III	Responding to painful stimuli only	10	6 60.0
Grade IV	Comatosed	6	5 83.3

\* Classification according to Garfield(11).

abscesses in children are cryptogenic(1,4,10). Prakash and Mehta(2) have noted a higher incidence (33%) and in our series it was 21.3%. The commonest source reported in most series including ours was otogenic in origin(2,4,11-18). However, in developed countries congenital cyanotic heart disease (CCHD) is emerging as the major predisposing factor(1,8,9,12).

The classical clinical triad of fever, headache and focal neurological deficit is usually observed in older children(4). Infants usually present with an enlarging head(6,7,8,13). Changes in sensorium, seizures, meningeal signs and cranial nerve palsies are other common symptoms. Ataxia and nystagmus are features of cerebellar abscesses.

The location and number of abscesses depends on the predisposing cause. The temporal lobe and the cerebellum are the common sites following otogenic source. Common causative organisms are *Staphylococcus aureus*, *Streptococcus pneumoniae*, *H. influenza*, *E. coli*, *Proteus* and *Pseudomonas*(1,2,4,12,13). Specific organisms are isolated in children with sickle cell disease (*Salmonella*), in CCHD (*Hemophilus aphrophilus*) and in the presence of prosthesis like heart valves or VP/VA shunts (*Staphylococci aureus*)(1,4). Recently anaerobic organisms as well as fungi and parasites are being isolated more commonly(1,4,12,14). As many as 25% of patients may have infection due to mixed organisms(15).

Lumbar puncture should be carried out cautiously in view of the possibility of catastrophic herniation(1,10,12,14) and moreover, it is often inconclusive. Although radionuclide scans, ventriculography and EEG are helpful in detecting brain

abscesses, CT scan is a very sensitive and noninvasive tool. The detection of other pathological changes and monitoring progress of the abscess is also possible with CT. Indeed CT scan has contributed significantly in reducing mortality(1,4,5,8,10) both by way of early detection as well as by permitting precise CT guided stereotactic aspiration in selected cases(4,13). In order to differentiate brain abscess from other closely resembling lesions on CT scan like tumors, infarcts and hematoma, simple laboratory evidence of acute phase reactant, e.g. CRP can be helpful(19). Recently, new neuroimaging technique incorporating  $^{99m}\text{Tc}$  HMPAO leucocyte scintigraphy has been used to clinch the diagnosis of intracranial inflammation in patients with ring lesions on CT scan(1,19).

Superiority of MRI over CT scan for early diagnosis of brain abscesses is well established(4,20) though some workers feel this diagnostic benefit has not reflected in the clinical outcome of patients(1,5). Moreover, its use is restricted owing to its prohibitive cost and limited availability.

Surgical drainage and/or incision along with aggressive antibiotic therapy remains the definitive treatment for brain abscesses(16-18). Some recent studies utilizing aspiration as the only surgical intervention have shown excellent results and this has been advocated as the first line of treatment(1,4). In fact this benefit has been very aptly extended to previously inaccessible sites like brainstem using microsurgical techniques(21). Early aspiration of an abscess located at paraventricular site is warranted to prevent disastrous events like shock and death following its rupture into ventricle(12,15). Conservative therapy alone is recommended in selected patients in the early stages of cerebritis, in

abscesses less than 2 cm, surgically inaccessible or multiple abscesses and in patients who are high surgical risk(4). Even our results with this mode have been very good but their small number (5 patients) does not permit a definite recommendation.

It is not possible to compare the mortality rates in relation to the different surgical modes employed in view of differing criteria used for selection of patients as well as the variation in the time of intervention in different series(4,5,H)- The same holds true for our series though aspiration alone had a higher mortality as compared to excision of abscess.

The mortality documented in various series has ranged from 7-53% (1,2,4,5,12,15). The substantial mortality of 44.7% at our hospital could be attributed to factors like a large number of patients admitted in Grade III/IV coma (34%), many cases with multiple abscesses (42%) and a significant proportion of infants (19.1%). In short the representation of large number of patients with bad prognostic factors in our series. The neurological status at admission was the major determinant of outcome and increasing mortality was noted with rapid decline of neurological status as also observed by other authors(1,4,5,11,13).

We would like to stress that a high index of suspicion, timely surgical intervention and vigorous antimicrobial therapy are crucial for better outcome.

#### REFERENCES

1. Patrick CC, Kaplan SL. Current concepts in the pathogenesis and management of brain abscesses in children. *Pediatr Clin North Am* 1988,35: 625-636.
2. Prakash B, Mehta G. Brain abscess in children. *Indian J Pediatr* 1988, 55: 246-250.
3. Balkrishnan D, Natrajan M. Intracranial brain abscess. *J Ind Med Assoc* 1971, 57: 87-89.
4. S'aez-Worens XJ, Umana MA, Odio CM, McCracken GH, Nelson JD. Brain abscess in infants and children. *Pediatr Infect Dis J* 1989, 8: 449-458.
5. Seydoux CH, Francioli P. Bacterial brain abscesses: Factors influencing mortality and sequelae. *Clin Infect Dis* 1992, 15: 394-401.
6. Fenichel GM. Increased intracranial pressure. *In: Clinical Pediatric Neurology-A Sign and Symptom Approach. Ed. Fenichel GM. Philadelphia, WB Saunders Co, 1988, pp 111-112.*
7. Sutton DL, Ouvrier RA. Cerebral abscess in the under-six month age group. *Arch Dis Child* 1988, 58: 901-905.
8. Fischer EG, McLennan JE, Suzuk Y. Cerebral abscess in children. *Am J Dis Child* 1981,135: 746-749.
9. Basit AS, Bhatia R, Banerjee AK, Tandon TS. Multiple pyogenic brain abscesses: An analysis of 21 patients. *J Neurol Neurosurg Psychiatry* 1989, 52: 591-594.
10. Kratimenos G, Crockard HA. Multiple brain abscess: A review of fourteen cases. *Br J Neurosurg* 1991, 5: 153-161.
11. Richards J, Sisson PR, Hickman JE, Ingham HR, Selkon JB. Microbiology, chemotherapy and mortality of brain abscess in Newcastle upon Tyne between 1979 and 1988. *Scand J Infect Dis* 1990, 22: 511-518.
12. Carmel PW. Nervous System. *In: Pediatrics, 19th edn. Ed Rudolph AM. Norwalk, Appleton and Lange, 1991, pp 1843-1848.*
13. Gupta SK, Mahantye S, Tandon SC, Asthana S. Brain abscess with special reference to infection by pseudomonas. *Br J Neurosurg* 1990, 4: 279-285.

14. Donald FE, Firth JL, Holland IM, Hope DT, Ispahani P, Purt JA. Brain abscess in the 1980's. *Br J Neurosurg* 1990, 4: 265-271.
  15. Haslam RH. The nervous system. *In: Nelson Textbook of Pediatrics*, 14th edn. Eds Behrman RE, Vaughan VC. Philadelphia, WB Saunders Co, 1992, pp 1530-1531.
  16. Bell WE, Chun RW, Jabbour JT, Meloff KL. Infections of the brain and spinal cord. *In: The Practice of Pediatric Neurology*, Vol 2, 2nd edn. Eds Swaiman KF, Wright FS. St Louis, CV Mosby Co, 1982, pp 678-683.
  17. Gulati DR. Infection: Pyogenic infections of nervous system. *In: Textbook of Neurosurgery*. Vol 1. Eds Ramamurthi B, Tandon PN. New Delhi, National Book Trust of India, 1980, pp 406-432.
  18. Goodman SJ, Stern WE. Cranial and intracranial bacterial infections. *In: Neurological Surgery*. Vol 6, 2nd edn. Ed Youman JR. Philadelphia, WB Saunders Co, 1990, pp 3343-3355.
  19. Grimstad IA, Hirschberg H, Rootwell K.  $^{99m}\text{Tc}$ -hexamethyl, propyleneamine oxime leucocyte scintigraphy and C-reactive protein levels in the differential diagnosis of brain abscesses. *J Neurosurg* 1992, 77: 732-736.
  20. Grossman CB. Infections and inflammatory Diseases. *In: Magnetic Resonance Imaging and Computed Tomography of Head and Spine*. Ed Grossman CB. Baltimore, Williams and Williams and Wilkins, 1990, pp 202-209.
  21. Alabedeen JZ. Solitary brainstem abscess successfully treated by microsurgical aspiration. *Br J Neurosurg* 1992, 6: 249-254.
-