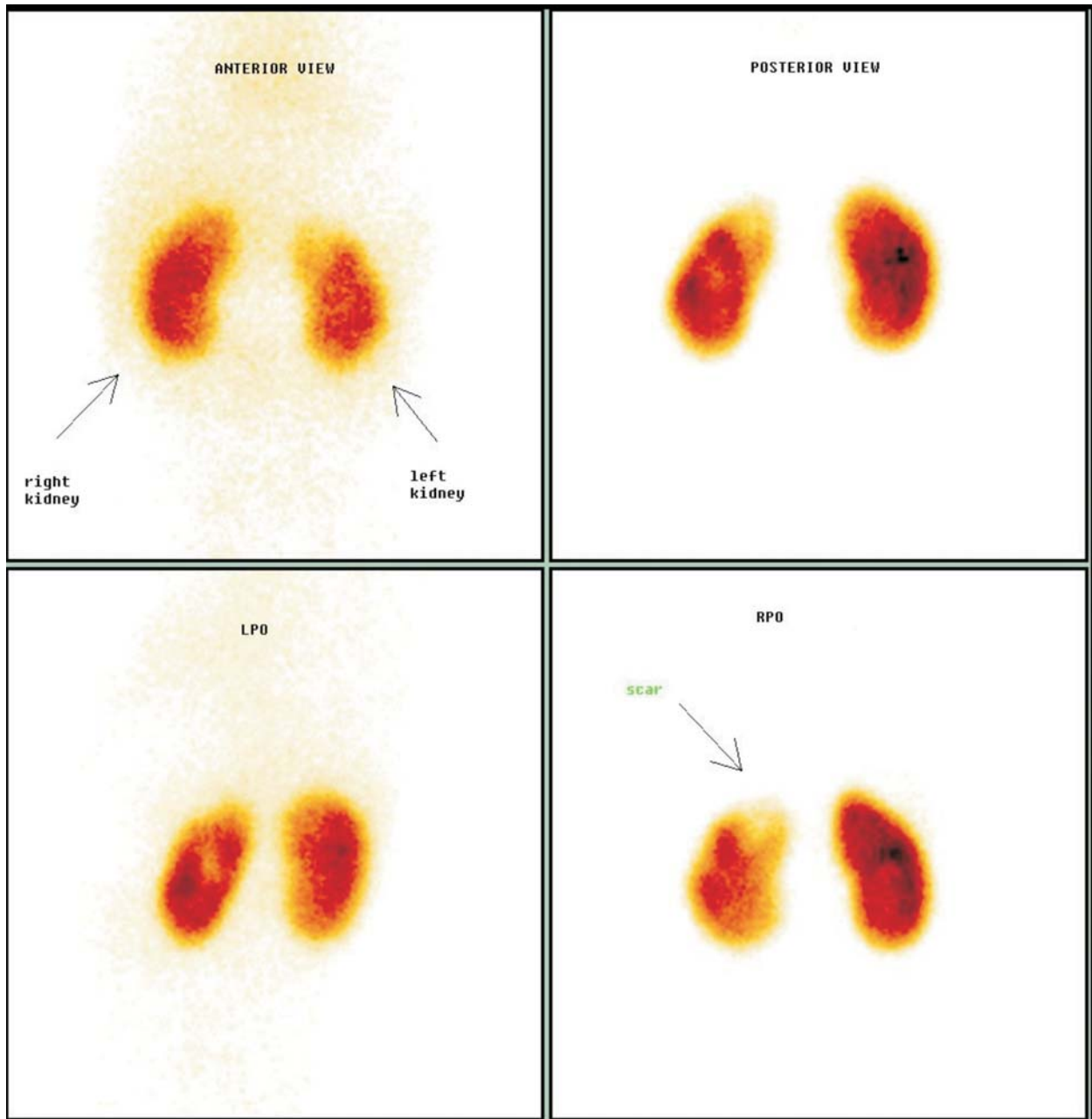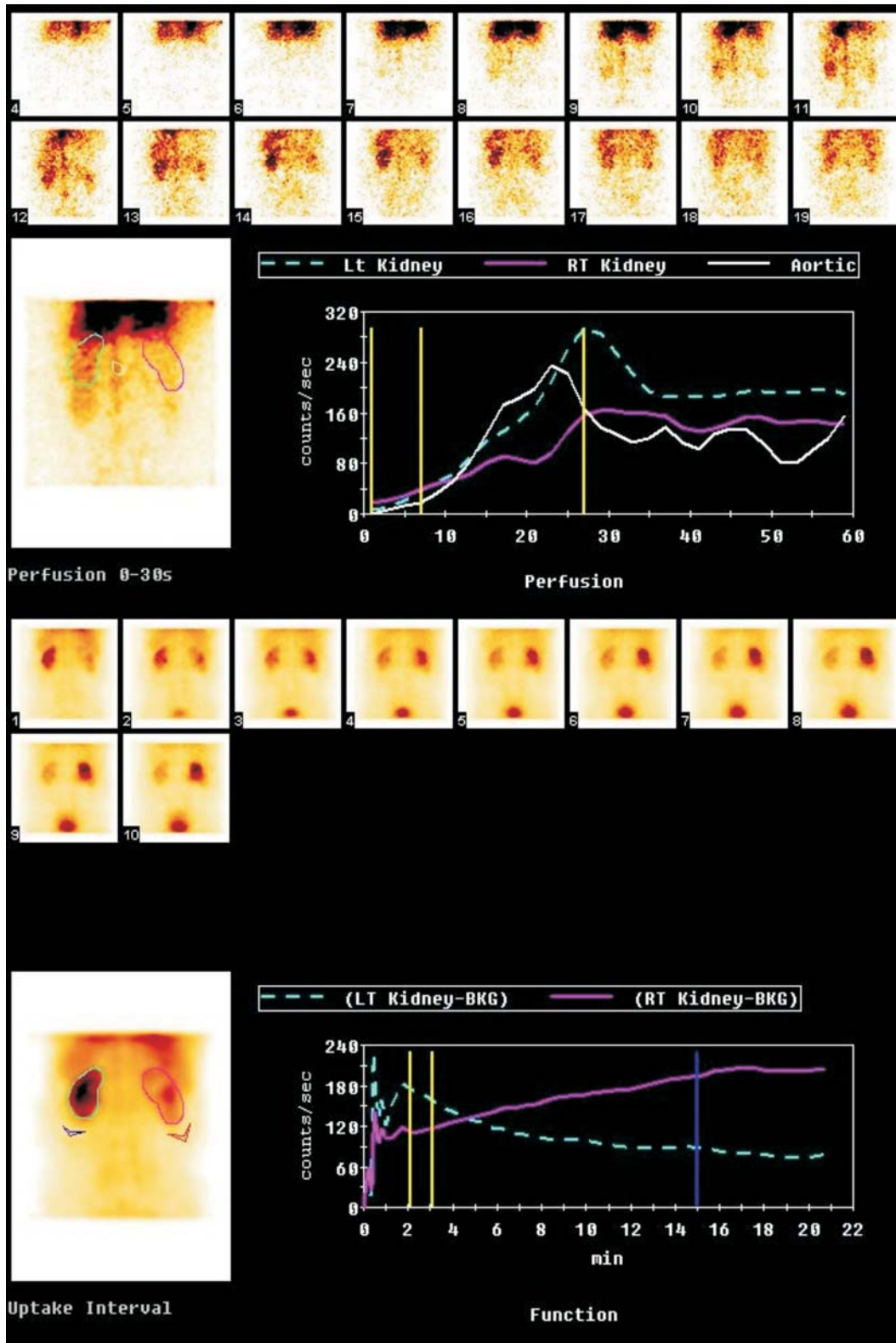


WEB FIG. 1 Right kidney: Normal sized right kidney with normal cortical function and no definite scan evidence of cortical scar; Left kidney: Normal sized left kidney with preserved cortical function and photopenic area in upper polar region suggestive of cortical



WEB FIG. 2 Right kidney: Hydronephrotic with mildly impaired function and features of obstructive PCS clearance suggestive of PUJO. (Differential function 40%); Left kidney: Normal function with non-obstructive upper outflow tract (Differential function 60%).