

Brucella Causing Liver Abscess in a Child with Selective IgA Deficiency

DEVDEEP MUKHERJEE, PRIYANKAR PAL AND RITABRATA KUNDU

From Department of Pediatric Medicine, Institute of Child Health, Kolkata, West Bengal, India.

Correspondence to:

*Dr Devdeep Mukherjee,
Uttara Cooperative Housing Society,
13, Broad Street, Kolkata 700 019,
West Bengal, India.*

devdeep_dm@rediffmail.com

Received: August 07, 2016;

Initial review: November 09, 2016;

Accepted: April 13, 2017.

Background: Brucella has been known to cause pyrexia of unknown origin. **Case Characteristics:** 9-year-old boy with fever and abdominal pain; multiple abscesses within the liver on ultrasonography. **Observations:** IgM Antibodies against Brucella were raised in his serum sample, and Brucella serum agglutination test was positive. Immunological work-up suggested selective IgA deficiency. Reduction in size following treatment with trimethoprim-sulphamethoxazole, amikacin and doxycycline. **Message:** Brucellosis should be considered as an etiology of liver abscess in patients not responding to conventional antibiotics.

Keywords: *Brucellosis, Immunodeficiency, Management.*

Liver abscess due to Staphylococcus, Streptococcus and Gram-negative organisms like *E.coli*, Klebsiella and Salmonella have been commonly reported in children. We report liver abscess caused by Brucella in a 9-year-old child with selective IgA deficiency.

CASE REPORT

A 9-year-old boy presented to us with a history of low grade fever for 3 weeks with intermittent abdominal pain localized to the epigastric region. Pain was not related with food intake and there was no history of vomiting, diarrhea, passage of worm or blood in stool, or oral ulceration. He had received oral Cefixime and Ofloxacin prior to admission, without any remission of symptoms.

At the time of hospitalization, the child was febrile and there was no jaundice or pallor. Liver and spleen were palpable 4 cm and 2 cm below the costal margin, respectively. He also had generalized lymphadenopathy. Hemoglobin (Hb) was 12.2g/dL, total leukocyte count (TLC) $9.2 \times 10^9/L$ with neutrophil 69% and lymphocyte 24%. C-reactive protein (CRP) was 37.3 mg/L (Normal <5 mg/L). Blood and urine cultures were sterile. Liver and renal function tests were normal. Widal and Mantoux test were also negative. Ultrasonography (USG) of abdomen revealed few iso- and hyper-echoic lesions in the right lobe. Lesion in segment IV measured 17×28 mm, and lesion in segment VI showed liquefactive component (**WebFig. 1a**). Fever and pain persisted even after treatment with Ceftriaxone, Cloxacillin and Metronidazole for 14 days. Repeat USG after two weeks showed lesions to be of same size with decreased echogenicity, suggestive of increased liquefaction. Computed

tomography (CT) scan revealed multiple thick walled, septated, hypodense space occupying lesions with peripheral and septal post-contrast enhancement. They were close to the biliary tree, and were communicating with each other within the liver (**WebFig. 1b**). CT-guided percutaneous aspirate did not show any organism on Gram stain and Ziehl Neelsen stain; bacterial and fungal cultures were also negative.

Brucella IgM antibodies were reactive – 27.8 (significant >12). Brucella serum agglutination test titer was 1:320. On questioning, the parents revealed a history of the child consuming unpasteurized cow milk. HIV serology, CD4:CD8 ratio and chronic granulomatous screening were normal. Serum Immunoglobulin A (IgA) level was 22 mg/100 mL (Normal 34-305 mg/100 mL). Serum levels of IgG, IgM and IgE were normal. We changed the antibiotics to Trimethoprim-Sulphamethoxazole (TMP-SMZ), Doxycycline and Amikacin. Gradually over the next three days, the fever reduced in intensity, and abdominal pain subsided. He was finally discharged after 10 days of this treatment.

At two weeks follow up, he developed deranged liver enzymes for which Doxycycline was discontinued. TMP-SMZ was continued for a total duration of 6 weeks. Largest lesion at 3 months follow-up measured 12×10 mm. Serial USG done over the next 6 months showed a gradual reduction in size of the abscess, with no further recurrence of fever or abdominal pain.

DISCUSSION

Brucellosis is transmitted to humans following intake of unpasteurized milk or milk products of infected animals. It may also spread following handling of infected tissue

samples [1]. *Brucella melitensis*, *B. suis*, *B. canis* and *B. abortus* are the commonest species known to be pathogenic to human beings [1-3]. Though we were not able to isolate brucella in this child, our diagnosis was based on history (consumption of unpasteurized milk), clinical findings and positive brucella serology. Isolation of brucella by blood culture is difficult in long-standing cases. It is a slow-growing organism, often needing 7 to 30 days for incubation with random blind subcultures [4,5]. Serology is the most useful diagnostic test in the absence of bacteriological confirmation, although false-positive reactions can occur.

Hepatic involvement in brucellosis is usually characterized by elevated transaminases [1,6]. Liver abscesses have been rarely reported, especially in children [1,2]. Patients infected with brucella may develop liver abscess as a result of caseation necrosis of granulomatous tissue. It may manifest acutely or may remain latent for a long period to manifest later [7]. USG and CT scan used to confirm the diagnosis usually reveal a hypoechoic or hypodense area. Calcifications are classical in brucella liver abscess, which were not documented in this child [7,8].

Despite being susceptible to multiple antibiotics, treatment failure is often seen because of the intracellular location of brucella, delayed diagnosis, and inappropriate dosage and duration of antibiotics. Combination of medical therapy with surgical drainage/percutaneous aspiration is the treatment of choice for localized abscesses caused by brucella [1,9]. TMP-SMZ for 4-6 weeks in combination with Rifampicin or aminoglycosides for 7-14 days or Doxycycline have been documented to reduce the relapse rates considerably [1,2,6,7,9]. As patients with complicated brucellosis often need prolonged course of antibiotics, we treated this child with three drugs and later discharged him on two oral antibiotics once clinical improvement was noted.

This child was also diagnosed with IgA deficiency, which happens to be the most common primary immunodeficiency in children. Infections of the respiratory tract (with *Haemophilus influenzae* and *Streptococcus pneumoniae*) and gastrointestinal (GI) tract are common. Secretory IgA has an essential role in

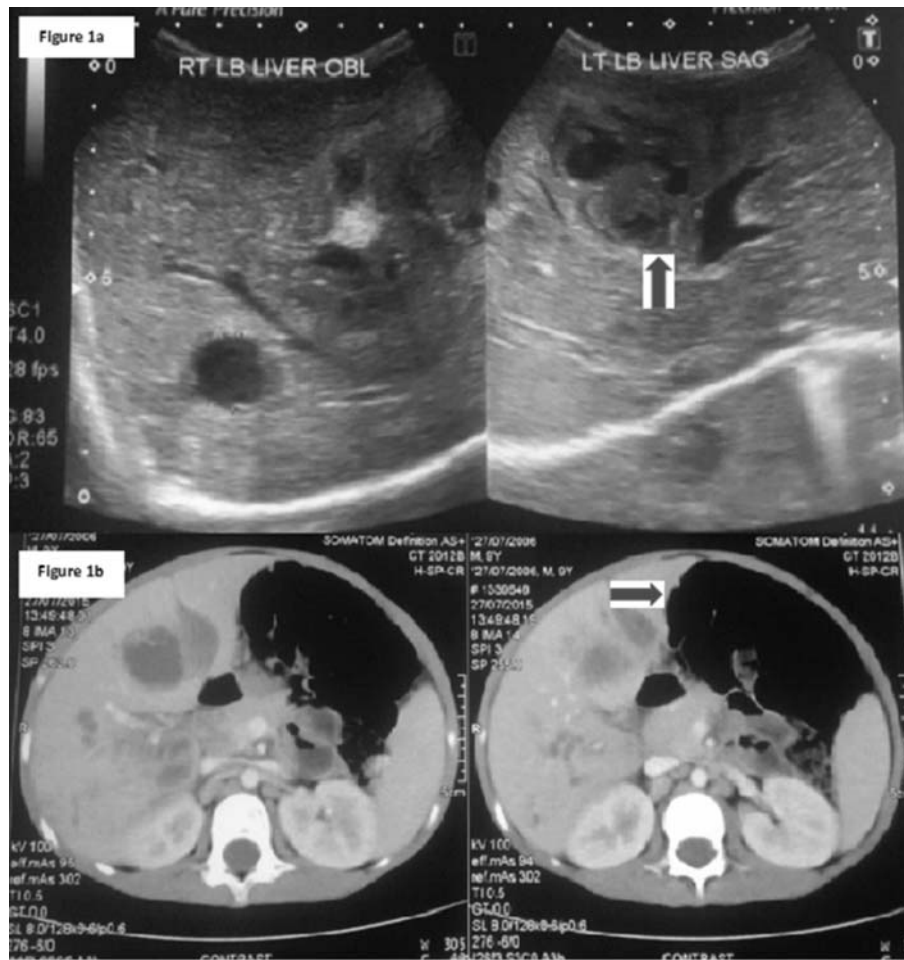
intestinal homeostasis as most of the commensal bacteria are located in the GI tract [10]. We could not find any earlier reported occurrence of liver abscess with brucella in a patient with selective IgA deficiency.

Non-response to conventional antibiotics in a case of liver abscess should prompt us to consider other atypical organisms such as brucella. Prolonged treatment with combination antibiotics may reduce the requirement of surgery and result in complete recovery. Patients with deep seated abscess with atypical organisms should also be screened for associated immunodeficiency.

Contributions: DM, PP, RK: were involved in interpretation of investigations, diagnosis and patient management; DM: drafted the manuscript which was verified and approved by PP and RK. *Funding:* None; *Competing Interest:* None stated.

REFERENCES

1. Vallejo JG, Stevens AM, Dutton RV, Kaplan SL. Hepatosplenic abscesses due to *Brucella melitensis*: Report of a case involving a child and review of the literature; *Clin Infect Dis.* 1996;22:485-9.
2. Kilicaslan B, Cengiz N, Pourbagher MA, Cemil T. Hepatic abscess: a rare manifestation of brucellosis in children; *Eur J Pediatr.* 2008;167:699-700.
3. Young EJ. An overview of human brucellosis. *Clin Infect Dis.* 1995;21:283-9.
4. Corbel MJ. Brucellosis: An overview. *Emerg Infect Dis.* 1997;3:213-21.
5. Al Dahouk S, Tomaso H, Nöckler K, Neubauer H, Frangoulidis D. Laboratory-based diagnosis of brucellosis—a review of the literature. Part II: serological tests for brucellosis. *Clin Lab.* 2003;49:577-89.
6. Paton NI, Tee NW, Vu CK, Teo TP. Visceral abscesses due to *Brucella suis* infection in a retired pig farmer. *Clin Infect Dis.* 2001;32:E129-30.
7. Chourmouzi D, Boulogianni G, Kalomenopoulou M, Kanellos I, Drevelgas A. *Brucella* liver abscess; imaging approach, differential diagnosis, and therapeutic management: a case report. *Cases J.* 2009;2:7143.
8. Sisteron O, Souci J, Chevallerier P, Cua E, Bruneton JN. Hepatic abscess caused by *Brucella* US, CT and MRI findings: case report and review of the literature. *Clin Imaging.* 2002;26:414-7.
9. Corbel MJ. *Brucellosis in Humans and Animals.* Geneva (Switzerland): World Health Organisation; 2006.
10. Yel L. Selective IgA deficiency. *J Clin Immunol.* 2010;30:10-6.



Web Fig. 1 (a) Ultrasonography (USG) of abdomen revealed few iso- and hyper-echoic lesions in the right lobe. (b) CT scan revealed multiple thick-walled, septated, hypodense space-occupying lesions with peripheral and septal post-contrast enhancement. They were close to the biliary tree and were communicating with each other within the liver.