

Delayed Presentation of Traumatic Diaphragmatic Hernia

A 10-year-old boy presented with abdominal pain around the umbilicus since 8 hours, 4 episodes of non-bilious vomiting and pain in the left shoulder since 5 hours. There was no history of fever or bowel disturbances. On examination his general condition was stable. Per abdomen examination revealed tenderness around the umbilicus. Examination of other systems was unremarkable. He had history of chest trauma 7 months back. At that time examination revealed wound measuring 4×2 cm below and lateral to left nipple with normal vitals. Respiratory and abdominal examination was unremarkable. Chest X-ray, sonography and CT scan were normal. Debridement and suture of the wound was done and child discharged after 5 days. During the second admission, his blood counts, urine examination, serum amylase, kidney function test and liver enzymes were within normal limits. Chest X-ray revealed non-visualization of left diaphragm and presence of distended bowel loops. CT scan showed disrupted left hemidiaphragm with herniation of bowel loops (**Fig.1**). On laparoscopy, left diaphragm opening was noticed with colon and omentum as contents. Surgeon tried to pull the contents back to abdomen but could not. Therefore laparotomy was performed, contents were reduced (colon was healthy) and closure of diaphragm opening was done. Child was discharged after 5 days.

Traumatic diaphragmatic hernia due to blunt trauma is rare in children and initial diagnosis is usually difficult because the early clinical and radiological findings are not clear [1,2]. Delayed presentation of rupture of the diaphragm is well recognized in adults but exceptionally rare in children [1]. Grimes [3] described the three phases of the rupture of the diaphragm. The first acute phase is at the time of the injury to the diaphragm, the second delayed phase is because of transient herniation of the viscera accounting for absence or intermittent non specific symptoms and the third obstruction phase due to complication of a long standing herniation, manifesting as obstruction and strangulation [3]. Despite technological advances, 30-50% of traumatic diaphragmatic ruptures are missed on initial presentation, as in our case [4]. Only 25% to 50% of cases will be detected by initial

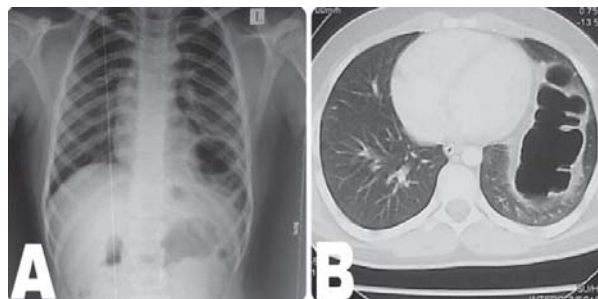


Fig.1 (a) The chest X-ray shows non-visualization of left diaphragm and presence of distended bowel loops; (b) Axial post-IV contrast CT through the lower chest showing herniated bowel loops in the left lung field.

chest radiograph, with an additional 25% with subsequent films [5]. Chest X-ray findings include distortion of diaphragmatic margin, elevated hemidiaphragm (>4 cm higher on left vs. right) and bowel loops in the lung space [4, 5]. Conventional CT scan has been reported to have a sensitivity of 14%-82% with a specificity of 87% [5]. Consistent CT findings include the “collar sign” which is a focal constriction of abdominal viscera (most common), intrathoracic herniation of abdominal contents, and discontinuity in the diaphragm [4]. During the first admission of this child with trauma, both chest X-ray and CT scan were normal. On the second admission, he had typical gastrointestinal symptoms with left shoulder pain and X-ray showed classical picture of diaphragmatic hernia which was confirmed on CT. To conclude, even though diaphragmatic hernia is uncommon, high index of suspicion should be kept in mind whenever there is a history of trauma. Prompt diagnosis and treatment prevents complications such as gangrene and perforation of herniated organs.

K JAGADISH KUMAR AND *MGANIL KUMAR,
*Department of Pediatrics and *Pediatric Surgery,*
JSS Medical College, JSS University, Mysore, India.
jagdishmandya@gmail.com

REFERENCES

1. Ninan G, Puri P. Late presentation of traumatic rupture of the diaphragm in a child. *BMJ.* 1993;306:643-4.
2. Okan I, Bas G, Ziyade S, Alimoglu O, Eryilmaz R, Guzey D, *et al.* Delayed presentation of posttraumatic diaphragmatic hernia. *Ulus Travma Acil Cerrahi Derg.* 2011;17:435-9.
3. Grimes OF. Traumatic injuries of the diaphragm. Diaphragmatic hernia. *Am J Surg.* 1974;128:175-81.
4. Walchalk LR, Stanfield SC. Delayed presentation of

traumatic diaphragmatic rupture. *J Emerg Medi.* 2010;39:21-4.

5. Lal S, Kailasia Y, Chouhan S, Gaharwar APS, Shrivastava GP. Delayed presentation of post traumatic diaphragmatic hernia. *J Surg Case Rep.* 2011;7:6.

Synthetic Apple Juice Masquerading as Low-osmolar ORS

A 3-year-old child was admitted with profuse watery diarrhea. A pediatrician elsewhere had advised low-osmolar ORS and even prescribed five packs (200 mL each) of "ORS-L" by Jagdale Industries Limited, Bangalore (**Fig. 1**). While the tetrapac is named 'ORS-L'

TABLE I COMPARISON OF THE APPLE DRINK WITH ORS-L

Contents (L)	Apple drink	Low-osmolar ORS
NaCl	1.25 g	2.6 g
KCl	1.5 g	1.5 g
Sod Citrate	2.9 g	2.9 g
Vitamin C	500 mg	–
Glucose	27 g	13.5 mg
Sugar	80 g	–
Carbohydrate	40 g	–
Osmolarity	585	245

in large letters, below that in smaller letters is inscribed 'Apple Drink' and 'enriched with electrolytes and Vitamin C'. **Table I** offers a comparison of the contents of the tetrapac with low-osmolar ORS. The total osmolarity of ORS-L is 585 mmol/L and is guaranteed to cause a severe osmotic diarrhea if ingested in adequate quantity.

It is unfortunate that in our country apple juice can be openly mislabelled and sold as ORS. All pediatricians



FIG. 1 Apple drink mislabelled as 'ORS-L'.

should be alert to this fraud, which requires knowledge of the formula of ORS-L. Perhaps the IAP through its Medico-legal Group should lodge an official complaint with the Ministry of Food Processing Industries and the Central Drugs Standard Control Organization.

NEWTON LUIZ
Consultant Pediatrician,
Dhanya Mission Hospital,
Potta PO, Thrissur Dt.,
Kerala 680 722, India.
newtonluz@gmail.com