

Calcinosis Cutis

A 21-day-old male infant presented with swelling over left upper limb for 3 days. Examination revealed a firm swelling of 3×4 cms over the proximal ventral aspect of left forearm and linear swellings over the medial aspect of left upper arm (**Fig. 1(a)**). Systemic examination and routine blood workup was normal. Ultrasound and X-ray of the swelling revealed subcutaneous calcification (**Fig. 1(b)**). This baby had asphyxia at birth, developed seizures and hypocalcemia on 2nd day of age, hence was treated with 10% calcium gluconate intravenously for 4 days and discharged with oral calcium supplementation. A diagnosis of iatrogenic calcinosis cutis was made.

Calcinosis cutis is characterized by abnormal deposits of calcium salts in the dermis and/or hypodermis due to transient elevation of the local calcium concentration after intravenous administration and local trauma. The differential diagnosis includes cellulitis, osteomyelitis, arthritis, abscess, periostitis, thrombophlebitis and myositis ossificans. Calcinosis cutis is differentiated from cellulitis and abscess by absence of signs of inflammation and characteristic roentgenographic findings. Myositis ossificans usually appears within the first decade of life as

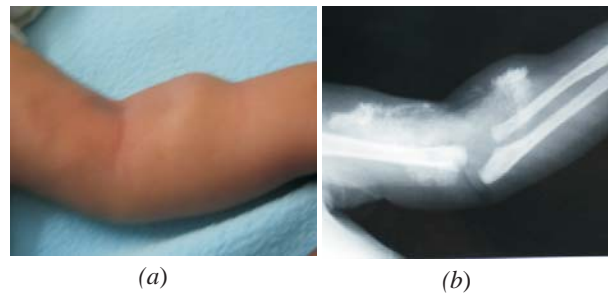


FIG. 1 (a) Showing swelling in the upper part of the left forearm, (b) X-ray limb showing subcutaneous calcification.

spontaneous or injury-induced exacerbations. The lesions are characterized by painful swellings in soft connective tissue, including tendons, ligaments, fascia, and skeletal muscle. No specific treatment is required for iatrogenic calcinosis cutis as it resolves spontaneously within three months.

AM VIJAYALAKSHMI AND S DEVAPRASATH
Department of Pediatrics,
PSG Institute of Medical Sciences and Research
Peelamedu, Coimbatore, TN, India.
narendeva@gmail.com

Multiple Discharging Sinuses with Disseminated Dactylitis

A 10-year-old male presented with fever, cough, poor oral acceptance, weight loss, and multiple painless swellings associated with serosanguineous discharge for last six weeks. He had already received multiple courses of antibiotics before presenting to us. On examination, four spindle shaped swellings with discharging sinuses were present over right index, middle and ring fingers. There were two discharging sinuses present over the dorsum of left hand and on the medial aspect of left thigh. An ulcer with discharging sinus was present over lateral aspect of left ankle (**Fig. 1**). He was severely wasted. Hands X-ray revealed multiple lytic lesions with little periosteal reaction in underlying respective phalanges and metacarpal bones. Chest X-ray showed nodular miliary shadows. The Ziehl-

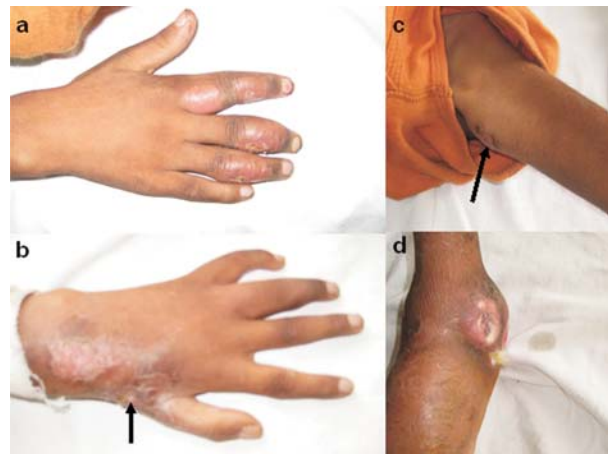


FIG. 1 (a) Spindle shaped swellings with discharging sinuses over index, middle and ring fingers of right hand, (b) Discharging sinus present over the dorsum of left hand, (c) Discharging sinus present over left thigh, (d) An ulcer with discharging sinus over left ankle.

Neelsen staining of the discharges taken separately from all discharging sinuses, demonstrated acid fast bacilli. After one month of antitubercular treatment, all discharging sinuses completely healed.

Tuberculosis (TB) of metatarsals, metacarpals and phalanges is usually associated with active pulmonary involvement, as observed in present case. TB of phalanges results in characteristic spindle shaped swelling of fingers, a condition known as spina ventosa. Spina is a latin word for “short bone” and ventosa is a latin word for “inflated with air”. The differential diagnosis of such a swelling includes syphilis and sickle cell dactylitis. Disseminated tubercular dactylitis, as seen in this case has been reported very rarely. Differentials for multiple discharging sinuses in children include staphylococcal infection and mucormycosis, both are rapidly progressive in nature, and

later is associated with necrosis of skin and subcutaneous tissue leading to eschar formation. Other gradually progressive diseases presenting as discharging sinuses in children are actinomycosis, botryomycosis, nocardiosis, and sporotrichosis. Sinus tracts of actinomycosis and nocardiosis usually discharge granules; botryomycosis is associated with subcutaneous nodules and large verrucous (wart-like) lesions; and in sporotrichosis an ascending chain of nodules develops along skin lymphatic channels (nodular angitis).

VISHAL KUMAR AND MANISH KUMAR

*Department of Pediatrics,
Maulana Azad Medical College &
Associated Chacha Nehru Bal Chikitsalya,
Geeta Colony, Delhi, India.
vmpd05@yahoo.co.in*

Erythema Nodosum as the Presenting Feature of Rheumatic Heart Disease

A nine-year-old boy presented with multiple painful nodular lesions on the extensor aspect of bilateral elbow and knee joints since 15 days (**Fig. 1**). There was no sore throat, pyoderma, arthralgia, abdominal pain, drug intake or Koch's contact. On enquiry, fever and exertional dyspnea were present since 5 days. Grade III/VI pansystolic murmur was present in the mitral area. Chest x-ray and ultrasonography of abdomen were normal.

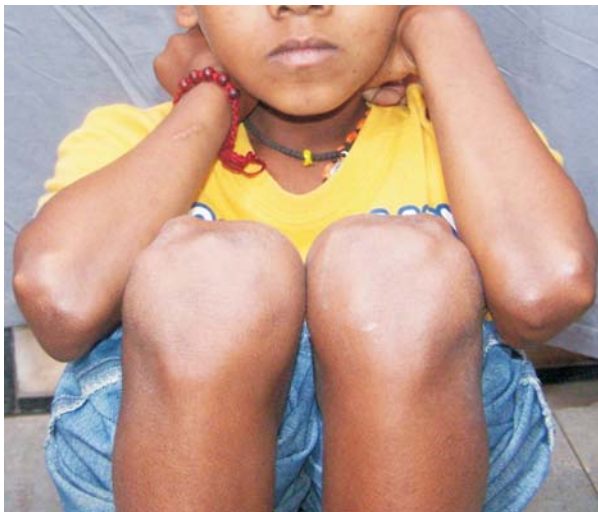

FIG. 1 Nodular lesions on the extensor aspect of bilateral elbow and knee joints.

Mantoux test was negative. Antistreptolysin titre, erythrocyte sedimentation rate and C-reactive protein were elevated. Echocardiography showed moderate mitral regurgitation. Histopathology of the nodular lesions was consistent with erythema nodosum (EN). With a diagnosis of rheumatic heart disease and active carditis, benzathine penicillin prophylaxis and aspirin were started. On follow up after 3 weeks, the nodules had disappeared.

EN is a symmetric inflammatory process involving the subcutaneous fat that causes tender, erythematous nodules. Sites involved are pretibial (most common), extensor surfaces of forearm, legs, thighs, and trunk. The lesions do not ulcerate and resolve without atrophy or scarring in one to two months. EN is a cutaneous immune-mediated (type IV delayed hypersensitivity) reaction to a variety of antigens. Commonly associated conditions include streptococcal infection, tuberculosis, sarcoidosis, sulphonamides, amoxicillin, inflammatory bowel disease, lymphoma, amoebiasis, giardiasis and viral infections (hepatitis B & C, herpes simplex, HIV and EBV). Common differential diagnoses include infectious panniculitis, lupus panniculitis, cold panniculitis, leukemic infiltrates, necrobiosis lipoidica, lipodystrophies and scleroderma. Management includes treatment of underlying disorders and supportive care i.e. bed rest, avoiding contact irritation of affected areas, non-steroidal anti-inflammatory drugs for pain and systemic steroids.

SYED AHMED ZAKI AND PREETI SHANBAG,

*Department of Pediatrics,
Lokmanya Tilak Municipal General Hospital and
Medical College, Sion, Mumbai, India.
drzakisyed@gmail.com*