

Cartilage-hair Hypoplasia Caused by Novel Compound Heterozygous *RMRP* Mutations

KERSTIN REICHERTER, AMITHKUMAR IYNAPILLAI VEERAMANI* AND SUJATHA JAGADEESH*

From Center for Pediatrics and Adolescent Medicine and Faculty of Biology, University of Freiburg, D-79106 Freiburg, Germany; and* Department of Clinical Genetics, Fetal Care Research Foundation, Chennai, India.

Correspondence to:
Dr Sujatha Jagadeesh,
Consultant and Head,
Department of Clinical Genetics, Fetal
Care Research Foundation, Chennai,
India. fcrfchennai@yahoo.com
Received: June 23, 2009;
Review Completed: January 11, 2010;
Accepted: March 22, 2010.

Cartilage-hair hypoplasia is a rare, autosomal recessive skeletal dysplasia, caused by mutations in the *RMRP* gene. The skeletal abnormalities include irregular metaphyses and cone shaped epiphyses of the hands. Molecular diagnosis confirmed two novel *RMRP* mutations in a compound heterozygous state in two siblings with this condition.

Key words: India, Metaphyseal chondrodysplasia, *RMRP* mutation, Skeletal dysplasia.

Cartilaginous hair hypoplasia (CHH) or metaphyseal chondrodysplasia McKusick type (OMIM #250250) is an autosomal recessive disorder [1]. It is a type of skeletal dysplasia resulting in short-limbed dwarfism with shortening and sometimes bowing of the tubular bones and brachydactyly, with radiographs showing disorganized metaphyses as well as cone shaped epiphyses of the fingers [2]. The *RMRP* gene was identified as the disease causing gene in CHH [3,4]. We report two patients with CHH caused by the two novel *RMRP* mutations c.94_96dupAGT and c.99C>T.

CASE REPORT

Two children born to a third degree consanguineously married South Indian couple were referred for evaluation of short stature. The elder sibling was a 15-year-old girl with short fingers at birth. Later a delay in all motor milestones and a gradual loss of scalp hair were noticed. She was attending school and was an average performer. When clinically evaluated at the age of 15-yr, the weight was 21 kg (<5th percentile) and height was 108 cm (<3rd percentile). The upper and lower segment ratios were infantile with upper segment measuring 57 cm while the lower segment measured

51 cm; the arm span (118 cm) was greater than her height. Other skeletal abnormalities included pectus carinatum, exaggerated lumbar lordosis, genu valgum and pes planus. The extension of elbows was restricted. Brachydactyly with broad finger tips and a single crease in the thumbs were identified. There was no axillary hair and she had not yet attained menarche. There was no history suggestive of immunodeficiency or malabsorption. Radiographs revealed cone shaped epiphyses of the hands, metaphyseal irregularities of femoral heads and phalanges, and brachydactyly of the phalanges.

The younger sibling was a 9-year-old boy whose height (99 cm) and weight (18 kg) were below the 5th percentile. His phenotype was similar to that of his sister, except for less pronounced scalp hair loss. Radiographs revealed similar changes; metaphyseal dysplasia and platyspondyly of the thoracolumbar vertebra was also seen. The patient's radiographs were submitted to the European Skeletal Dysplasia Network (ESDN) clinical-radiographic review panel. As the features were suggestive of CHH, analysis of the *RMRP* gene was proposed.

Following extraction of DNA from blood of the sibs and their parents, the *RMRP* gene was amplified by polymerase chain reaction (PCR) [1]. The

complete transcript of the *RMRP* gene as well as 200 base pairs of the promoter region was sequenced. Thereby the novel *RMRP* mutations c.94_96dupAGT and c.99C>T (Fig. 1) as well as the previously described polymorphisms g. 58T>C; g.-48C>A and g.+7T>C (all homozygous), were identified in both patients. Both siblings were compound heterozygous for the mutations. The correct segregation of the mutations was proven by subcloning and sequencing of the PCR products. Analysis of the parents confirmed their carrier status. The father had a c.99C>T mutation whereas the mother had the duplication (c.94_96dupAGT). The father was homozygous for the polymorphisms and the mother was heterozygous.

DISCUSSION

CHH is a rare disease with known carrier frequencies of 1:19 among the Amish and 1:76 among the Finnish population [3]. The phenotype of CHH is variable. Laxity of ligaments, incomplete extension at the elbows, cone shaped epiphyses of the phalanges [1], rounded distal epiphyses, prominent sternum, chest deformity [5], mild scoliosis, increased lumbar lordosis and bowing of the lower limbs are described. The affected siblings reported in this study, had most of the clinico-radiographic findings suggestive of CHH.

The *RMRP* gene encodes the untranslated RNA component of the RNase MRP complex. This ribonucleoprotein complex cleaves RNAs and is thereby involved in the replication of mitochondrial DNA [6], processing of the 5.8 S ribosomal RNA [7] and control of cell cycle progression at the end of mitosis [8]. Mutations in the *RMRP* gene lead to a wide spectrum of recessive skeletal dysplasias with different degrees of short stature. The molecular analysis of the *RMRP* gene in the affected siblings identified two novel mutations, c.94_96dupAGT and c.99C>T. We conclude that these were pathogenic as they were inherited from unaffected parents, both carrying one of the mutations. In addition, the mutations were not identified in 100 controls [9]. The functional importance could be explained by the localization of both mutations in an evolutionary conserved part of the transcript [9]. They might alter a very important stem-loop structure [10].

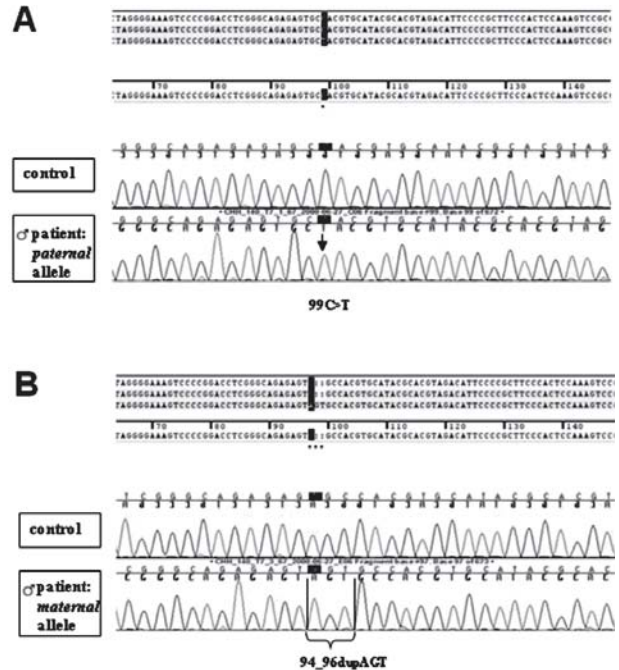


FIG 1. Sequencing of the *RMRP* gene after subcloning; results of the boy. (a) The paternal allele carries a c.99C>T nucleotide substitution within the *RMRP* gene. (b) The maternal allele carries a duplication of 3 nucleotides (c.94_96dupAGT) within the *RMRP* gene. Both patients were compound heterozygous for the novel *RMRP* mutations c.99C>T and c.94_96dupAGT.

After having confirmed the diagnosis by molecular analysis, the prospective treatment was discussed. Unlike most CHH patients, these sibs did not have a history of recurring infections or other signs of immunodeficiency. As the clinical outcome of CHH patients can only be poorly predicted, they should be carefully followed up because of the possibility of serious infections and malignancies.

Acknowledgments: We acknowledge the support of Dr Andreas Zankl, Dr Sheila Unger and the ESDN clinical-radiographic review panel (www.esdn.org). We thank Dr Pia Hermanns, who was involved in the *RMRP* mutation analysis and the interpretation of the data. We thank Dr Suresh S of the Fetal Care Research Foundation for his encouragement.

Contributors: KR: did the molecular analysis, was involved in the interpretation of the data, drafted the manuscript together with AIV and revised the manuscript; AIV: drafted the manuscript initially; SJ: managed the case and will act as the guarantor. The final manuscript was approved by all authors.

Funding: None.

Competing interests: None stated.

REFERENCES

1. Bonafé L, Schmitt K, Eich G, Giedion A, Superti-Furga A.

- RMRP gene sequence analysis confirms a cartilage-hair hypoplasia variant with only skeletal manifestations and reveals a high density of single-nucleotide polymorphisms. *Clin Genet.* 2002;61:146-51.
2. Polmar SH, Pierce GF. Cartilage hair hypoplasia: immunological aspects and their clinical implications. *Clin Immunol Immunopathol.* 1986;40:87-93.
 3. Ridanpää M, Sistonen P, Rockas S, Rimoin DL, Mäkitie O, Kaitila I. Worldwide mutation spectrum in cartilage-hair hypoplasia: ancient founder origin of the major 70A->G mutation of the untranslated RMRP. *Eur J Hum Genet.* 2002;10:439-47.
 4. Ridanpää, M, van Eenennaam H, Pelin K, Chadwick R, Johnson C, Yuan B, *et al.* Mutations in the RNA component of RNase MRP cause a pleiotropic human disease, cartilage-hair hypoplasia. *Cell.* 2001;104:195-203.
 5. McKusick VA, Eldridge R, Hostetler JA, Egeland JA, Ruangwit U. Dwarfism in the Amish. II Cartilage-hair hypoplasia. *Bull Johns Hopkins Hosp.* 1965;116:285-326.
 6. Chang DD, Clayton DA. Mouse RNAase MRP RNA is encoded by a nuclear gene and contains a decamer sequence complementary to a conserved region of mitochondrial RNA substrate. *Cell.* 1989;56:131-9.
 7. Schmitt ME, Clayton DA. Nuclear RNase MRP is required for correct processing of pre-5.8S rRNA in *Saccharomyces cerevisiae*. *Mol Cell Biol.* 1993;13:7935-41.
 8. Gill T, Cai T, Aulds J, Wierzbicki S, Schmitt ME. RNase MRP cleaves the CLB2 mRNA to promote cell cycle progression: novel method of mRNA degradation. *Mol Cell Biol.* 2004;24:945-53.
 9. Bonafé L, Dermizakis ET, Unger S, Greenberg CR, Campos-Xavier BA, Zankl A, *et al.* Evolutionary comparison provides evidence for pathogenicity of RMRP mutations. *PLoS Genet.* 2005;1:444-54.
 10. Welting TJ, van Venrooij WJ, Pruijn GJ. Mutual interactions between subunits of the human RNase MRP ribonucleoprotein complex. *Nucleic Acids Res.* 2004;32:2138-46.

Atypical Cogan Syndrome Mimicking Acute Rheumatic Fever

M JUNEJA, R JAIN AND B CHAKARBARTY

From Department of Pediatrics, Maulana Azad Medical College and Associated Lok Nayak Hospital, New Delhi, India.

Correspondence to:
Prof Monica Juneja,
C-77 South Extension II,
New Delhi 110049, India.
drmonicajuneja@gmail.com
Received: November 19, 2009;
Initial review: February 8, 2010;
Accepted: March 25, 2010.

Cogan syndrome is a syndrome of non-syphilitic interstitial keratitis associated with vestibuloauditory deficits. We report a 10 year-old male child who presented with fever, acute polyarthritis, and unilateral red eye and was diagnosed as acute rheumatic fever. Subsequently unilateral hearing loss was detected and the child was diagnosed to have atypical Cogan syndrome.

Key words: Acute rheumatic fever, Arthritis, Atypical Cogan's syndrome, Polyarthritis.

Cogan syndrome is a syndrome of non-syphilitic interstitial keratitis associated with vestibuloauditory deficits, that progresses to complete deafness within 2 years [1]. The term 'Atypical Cogan's syndrome' was suggested later for cases in which sensorineural hearing loss is associated with ocular inflammation distinct from interstitial keratitis, such as uveitis, scleritis, conjunctivitis or retinal vasculitis [2,3]. Patients in which the interval between the onset of ocular and audiovestibular manifestations is more than two years are also labeled as atypical Cogan's syndrome [2,3]. Majority of patients with this

syndrome develop significant systemic symptoms and often present a diagnostic challenge [3-6]. We describe a 10 year old male child who presented to us with acute polyarthritis and was later diagnosed as atypical Cogan syndrome.

CASE REPORT

A 10 years old male child was referred to our center as a case of acute rheumatic fever. There was history of low grade fever for 7 days, severe pain and swelling in multiple large joints for 4 days and redness of the right eye for 4 days. There was no history of any antecedent upper respiratory tract