

### Isolated Asternia

A 9-year-old boy presented with pectus excavatum associated with a complete congenital sternal cleft. The ends of the ribs were not palpable (**Fig. 1**). The defect was covered only by a layer of skin and pulsation of the heart and great vessels could be seen easily. Spiral computed tomography showed that sternum was absent but other intrathoracic structures were completely normal.

Asternia is a very rare condition and may occur as an isolated entity or as part of a syndrome such as Cantrell's pentalogy and Leiber's syndrome. Isolated asternia is a benign malformation with a good prognosis. In this anomaly, the heart and great vessels may easily be injured by external trauma. In addition, the deformity is cosmetically unpleasent. The management of this anomaly is challenging with respect to appropriate time for surgical reconstruction.

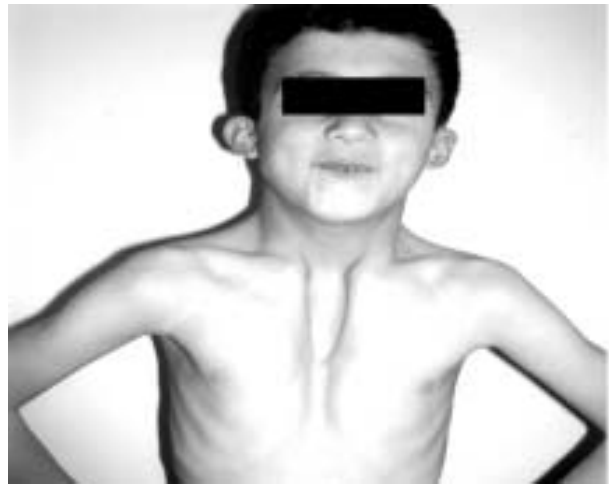

FIG. 1. Sternal cleft and pectus excavatum

**Canan Eren Dagli,  
Ekrem Guler,**

*Faculty of Medicine,  
Kahramanmaras Sutcu Imam University,  
Kahramanmaras, 46050,  
Turkey.*

### Ulcerative Traumatic Granuloma of the Oral Cavity

An 8 month-old infant boy with cerebral palsy presented with a large exophytic lesion under the tongue with erythema surrounding a removable, fibrinopurulent membrane and granulation tissue proliferation present for several weeks (**Fig. 1**). He was unable to suckle for feeding. Laboratory tests were normal. Biopsy was suggestive of distinctive ulcerative traumatic granuloma with stromal eosinophilia (Riga-Fede disease). Contact of the tongue with the sharp, newly erupted mandibular teeth was apparent. Grinding the teeth edges and covering with resin resulted in rapid resolution within 5-10 days.

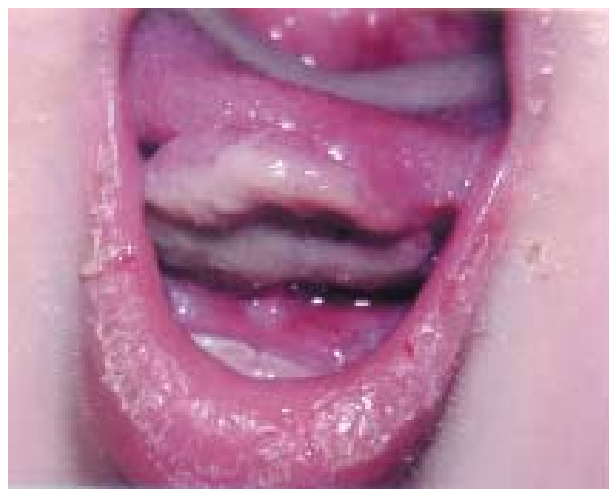

FIG. 1. Ulcerative traumatic granuloma on the anterior ventral part of the tongue; note sloughing necrotic pseudomembrane, and dry lips.

## BOOK REVIEW

Riga-Fede disease, a variation of the traumatic granuloma, may occur after acute injuries with sharp foodstuffs, biting, or mastication. This unique type of chronic granulomatous ulceration with stromal eosinophilia is a deep, pseudoinvasive, inflammatory reaction seen in infants following chronic trauma from neonatal or primary teeth. Differential diagnosis may include pyogenic granuloma, ulcerative carcinoma, and lymphoma. Biopsy provides definitive diagnosis. Removing the


source of trauma is sufficient. Failure to diagnose and treat RFD results in dehydration and inadequate intake for the infant.

**Taghi Azizi,**  
**Mohammad Hosein Kalantar Motamedi,**  
*Departments of Pathology and  
Trauma Research,  
Baqiyatallah University of Medical Sciences,  
Tehran, Iran.*

---

## B O O K R E V I E W S

---



**Essential Pediatric Nursing**  
PIYUSH GUPTA  
*New Delhi: CBS Publishers &  
Distributors; 2007.*  
Pages: 572, Price: Rs 375/-

Pediatric nursing has emerged as a specialty nursing in past few years. In coming years pediatric nurse practitioner is going to take up the independent role of providing comprehensive care to newborn, infant, toddler, preschool, school going and adolescents.


The second edition of the book is divided into nine units covering the newborn, healthy child, nursing procedures and care, common health problems, congenital malformations, systemic disorders, child disability and welfare with the last one on IMNCI.

The contributors are eminent pediatricians who have included the latest concepts and trends in

pediatrics. The book has been written in a very simple manner keeping in mind the syllabus prescribed for child health nursing by the Indian Nursing Council (INC). Important information is highlighted in boxes. Practical skills required by a pediatric nurse in procedures like nasogastric tube insertion, O<sub>2</sub> administration, photo therapy etc. have been appropriately covered. However, the surgical conditions covered need more depth giving due emphasis to pathophysiology, clinical manifestations and management etc.

I hope this book will provide an overview of essential pediatric nursing to the general nursing students and understanding of the modern approaches to child care including IMNCI.

**Manju Vatsa,**  
*Principal, College of Nursing,  
AIIMS, New Delhi 110029.*  
*E-mail: mvatsa2001@yahoo.co.in*



**Textbook of Community  
and Social Pediatrics**  
SR BANERJEE  
*New Delhi; Jaypee Brothers  
Medical Publishers; 2008.*  
Pages: 496,  
Price: Rs 495/-

Health status of a nation largely depends on quality of care provided to its children. Importance of social pediatrics in this regard cannot be overemphasized. However, for providing robust public health program clinical pediatrics needs to be strengthened. Thus, it is pleasant to see that in this multi-authored book large number of eminent pediatricians have contributed significantly.