

ULTRASONIC EVALUATION OF INTRA-ABDOMINAL ABSCESSSES

R. Kapoor
M.M. Saha
S. Talwar

ABSTRACT

This study describes the role of ultrasound in the evaluation of abdominal abscesses in children. A total of 41 abscesses were encountered in 36 patients (21 boys and 15 girls). The youngest patient was 1-month-old. Abscesses were localised at various sites (hepatic, renal, perirenal, paracolic, appendicular, pelvic, psoas, sub-phrenic, parietal), and of varied sonographic patterns (complex, anechoic, hypoechoic and containing uniform low level echoes). Most of them had irregular walls.

Key words: *Ultrasound, Abdominal abscess.*

From the Department of Radiology and Pediatric Surgery, Maulana Azad Medical and Associated Lok Nayak Jai Prakash Narain Hospital, New Delhi 110 002.

Reprint requests: Dr. Madan M. Saha, Type-VI, Qr. No. 9, Maulana Azad Medical College Campus, Kotla Road, New Delhi 110 002.

*Received for publication April 17, 1989;
Accepted March 11, 1991*

Abdominal abscesses in children are often not diagnosed on clinical grounds alone. Ultrasound being a non-invasive modality, is especially useful in differentiating abscesses from other fluid collections in the abdomen and also for follow up(1). We present our experience with 36 patients with intra-abdominal abscesses at various sites on ultrasound.

Material and Methods

Thirty six children ranging from 1 month-12 years in age (21 males and 15 females) comprise the material of this series. The study was conducted on Siemen's Sonoline SL II machine, using 3.5 and 5 MHz sector and 3.5 MHz linear transducers. The diagnosis of an abscess was confirmed in all cases (fine needle aspiration cytology, culture, surgery or therapeutic response to antibiotics and antiamebic treatment).

Results

The diagnosis of an abscess was suspected on clinical grounds in 25 cases. Out of the remaining 11 cases, 3 presented with pyrexia of unknown origin, 1 with recurrent urinary tract infection and 7 with abdominal lumps not thought to be abscesses. The site of the abscesses are given in *Table I*.

Of the ten liver abscesses, 6 were pyogenic and 4 amebic, with multiple abscesses occurring in 2 cases in each group. Ultrasound could not differentiate pyogenic from amebic abscess. Parietal abscesses characteristically appeared very superficially in the parieties and were better delineated with a linear transducer (*Fig. 1*). Three of them appeared anechoic and 2 hypoechoic with ill defined margins.

A total of 41 abscesses were encoun-

TABLE I—Abscesses at Various Sites

Site	Number (n=36)	%
Hepatic	10	27.8
Paracolic	6	16.7
Perinephric	5	13.9
Parietal	5	13.9
Psoas	3	8.3
Appendicular	3	8.3
Pelvic	2	5.5
Intrarenal	1	2.8
Subphrenic	1	2.8

tered in 36 patients. They presented varied sonographic patterns—mixed echo pattern in 26 (Fig. 2), anechoic in 5, hypoechoic in 5 and having uniform low level echoes inside in 5 (Fig. 3). X-ray of the spine was taken in cases of suspected psoas abscess; one or two carious lumbar vertebrae were found in each case. Of the three psoas abscesses, one was of mixed echo pattern, the other two had uniform low level echoes inside, and each had displaced the kidney anteriorly and laterally (Fig. 4). The patient with a subphrenic abscess showed a collection with shadowing (suggesting air inside) under the right dome of the diaphragm. This was later confirmed on X-ray chest in the erect position which showed an air-fluid level below the right dome. In our series, 38 abscesses had irregular walls and 3 well defined walls.

Discussion

The ability of ultrasound to predict the nature of fluid within a lesion is especially useful in avoiding the false-positive diagnosis of an abscess(2). Abscesses usually show a uniform distribution of echoes, but may also show band-like internal echoes

representing walls of loculi(1). Gas containing abscesses may appear as densely echogenic masses with acoustic shadowing, or merely as regions of acoustic shadowing(3). Subphrenic abscess in our series was correctly diagnosed as air in it produced acoustic shadowing. Abscesses usually have finely irregular walls and are generally elliptical in cross section. They tend to displace or indent all but the most resistant of structures, losing their elliptical configuration only when confined by strong barriers e.g., diaphragm, pelvic wall or adhesions(1).

The overall accuracy of sonographic diagnosis of intra-abdominal abscesses has been reported to be between 96-98%(4,5). Schwerk and Durr(6), in their study of 45 abscesses, observed three types of patterns of ultrasound—anechoic with occasional cyst like pattern (55.6%), fluid pattern with few scattered internal non-reverberatory echoes (33.3%), and complex or solid pattern (11.1%). We encountered four types of sonographic appearances—mixed echo pattern (63.4%), anechoic (12.2%), hypoechoic (12.2%) and with uniform low level echoes (12.2%). It is usually difficult to differentiate ultrasonically between amebic and pyogenic liver abscesses. Some authors feel that location in the liver may be a significant pointer to etiology, with amebic abscesses far more often peripheral and contiguous with the liver capsule compared to pyogenic ones(7,8). We did not find any characteristic features to differentiate amebic from pyogenic liver abscesses.

An appendiceal abscess is the most common gastrointestinal mass in older infants and children(9). Pelvic extension of such abscesses into the pouch of Douglas occurs frequently, presenting as a mass between the bladder and rectum. Puvanewary and David(10) reported 2 cases with

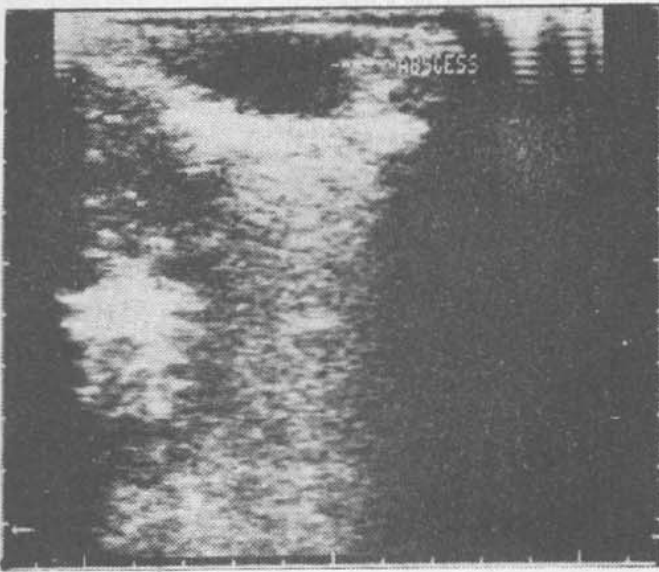


Fig. 1. Linear scan shows a hypoechoic parietal abscess.

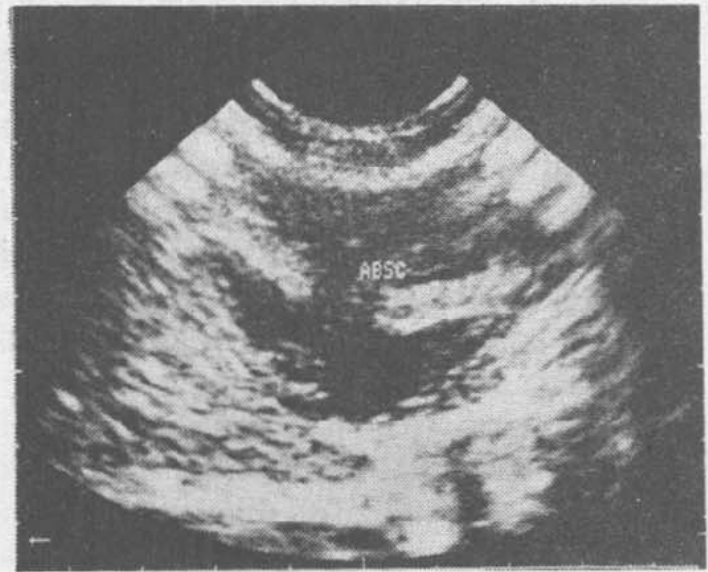


Fig. 2. Sector scan showing a mixed echo pattern paracolic abscess.

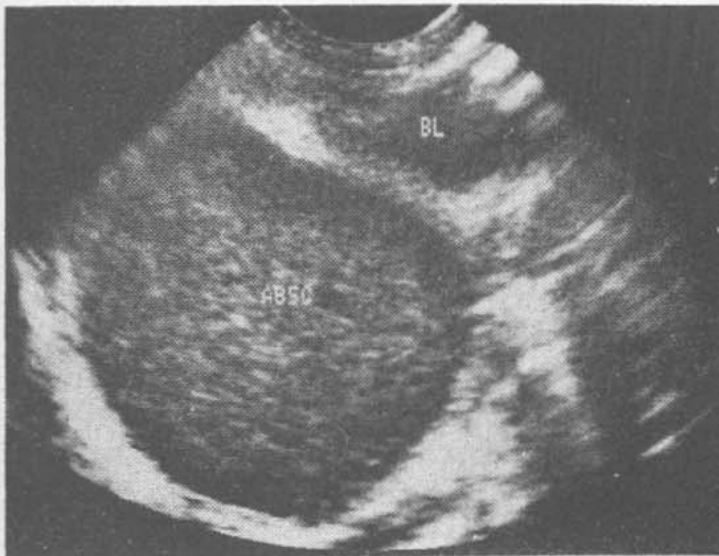


Fig. 3. Sector scan shows a thick walled pelvic abscess containing uniform low level echoes inside.

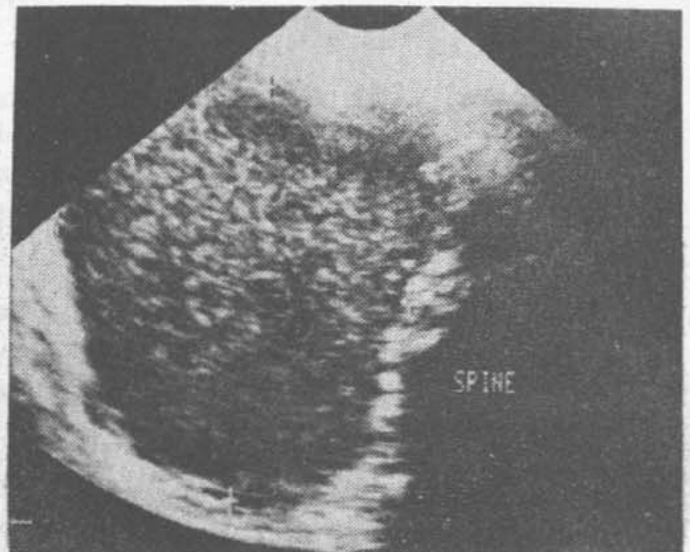


Fig. 4. Midline sector transverse scan shows a psoas abscess to the right side of the spine and containing low level echoes.

psoas abscess which was seen as a mass with complex echo pattern lying outside and posterior to the kidney and displacing the kidney anteriorly in the prone longitu-

dinal scan. All the three psoas abscesses in our series were correctly diagnosed because of their typical location. While in India most psoas abscesses are tubercular in

origin, in Western countries they are of pyogenic origin. All three psoas abscesses in our series were tubercular.

The differential diagnosis of an abscess (without air) include hematoma, loculated ascites, lymphocele, urinoma, *etc.* Abscess walls are finely irregular, the irregularity being less than that seen in the walls of chronic hematomas. Abscess walls lack the sharpness of the walls of fluid collections (lymphoceles, urinomas, loculated ascites or a hepatic cyst) which do not have any internal contents(1). The differential diagnosis of a gas containing abscess include calcified lesions and lesions with abundant fibrous stroma such as an angiomyolipoma or teratoma(3).

In conclusion, in a proper clinical setting and with specific ultrasound features, an intra-abdominal abscess can be reliably diagnosed and early treatment instituted.

REFERENCES

1. Doust BD, Quiroz F, Steward JM. Ultrasonic distinction of abscesses from other intra-abdominal fluid collections. *Radiology* 1977, 125: 213-218.
2. Kuligowska E, Mueller PR, Simeone JF, Fine C. Ultrasound in upper abdominal trauma. *Semin Roentgenol* 1984, 19: 281-295.
3. Kressel HY, Filly RA. Ultra-sonographic appearance of gas-containing abscesses in the abdomen. *Am J Roentgenol* 1978, 130: 71-73.
4. Maklad NF, Doust BD, Baum JK. Ultrasonic diagnosis of post-operative intra-abdominal abscess. *Radiology* 1974, 113: 417-420.
5. Taylor KJ, Sullivan DC, Wasson JF. Ultrasound and gallium for the diagnosis of abdominal and pelvic abscesses. *Gastroint Radiol* 1978, 3: 281-286.
6. Schwerk WB, Durr HK. Ultrasound, gray scale pattern and guided aspiration punctures of abdominal abscess. *J Clin Ultrasound* 1981, 9: 389-396.
7. Newlin N, Silver TM, Stuck KJ, Sandler MA. Ultrasonic features of pyogenic liver abscess. *Radiology* 1981, 139: 155-159.
8. Ralls PW, Colletti PM, Quinn MF, Halls J. Sonographic findings in hepatic amebic abscess. *Radiology* 1982, 145: 123-126.
9. Melicow MD, Usan AC. Palpable abdominal masses in infants and children. A report based on review of 653 cases. *J Urol* 1959, 81: 705-710.
10. Puvaneswary M, David CV. Psoas abscess, ultrasonic and computed tomographic appearance. *Australas Radiol* 1985, 29: 163-166.