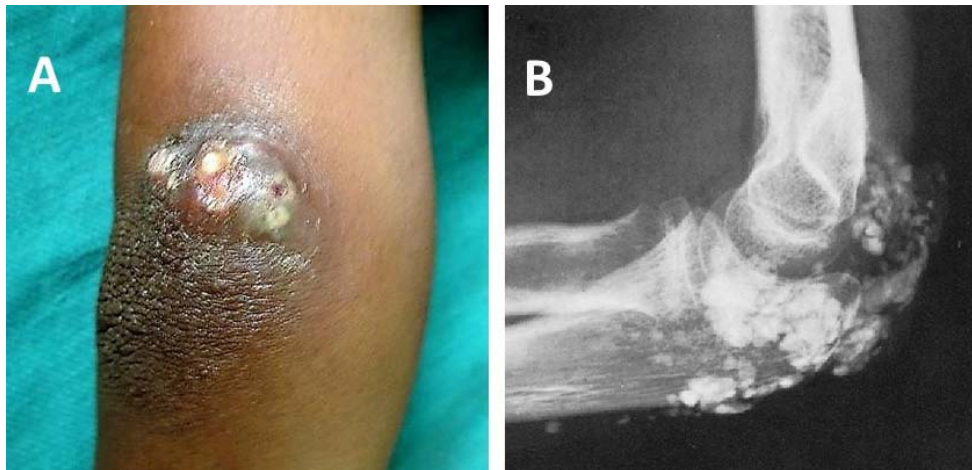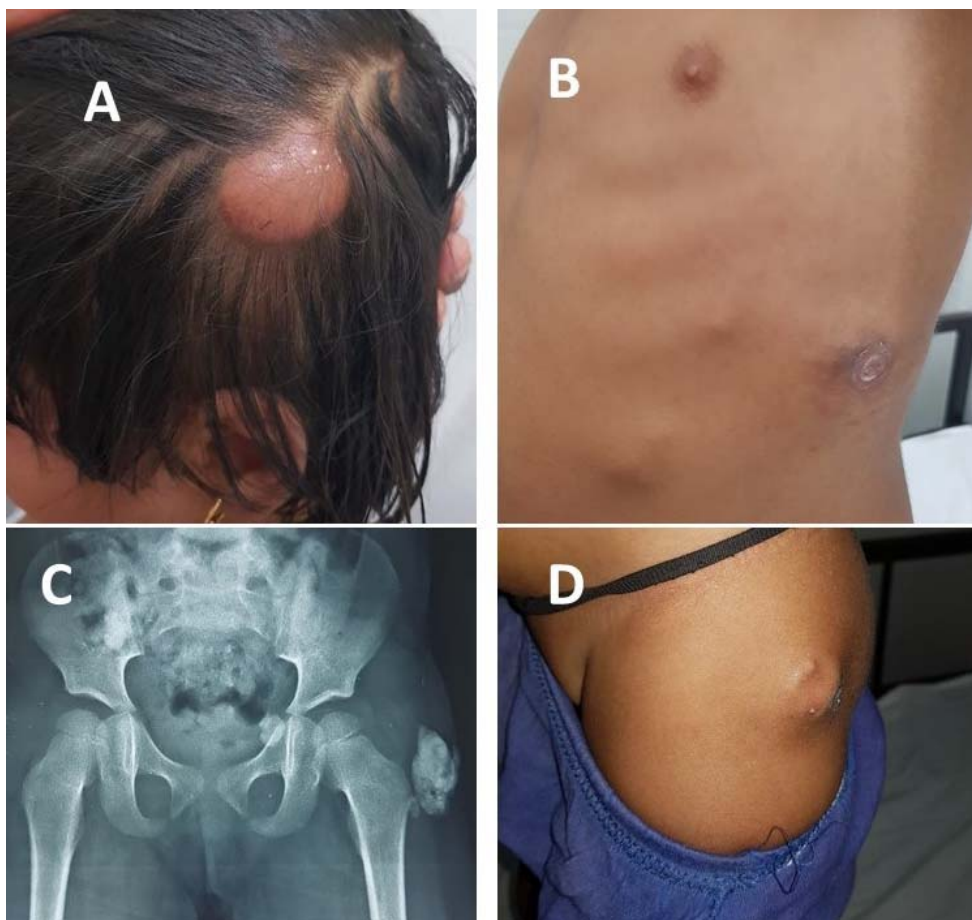


**WEB FIG. 1** (a) Calcinosis in the right elbow; and (b) X-ray elbow showing calcinosis before treatment.



**WEB FIG. 2** (a) Scalp calcinosis; (b) multiple nodular swelling in lateral chest with scar mark; (c) X-ray pelvis with calcinosis; and (d) calcinosis in lateral aspect of the hip.