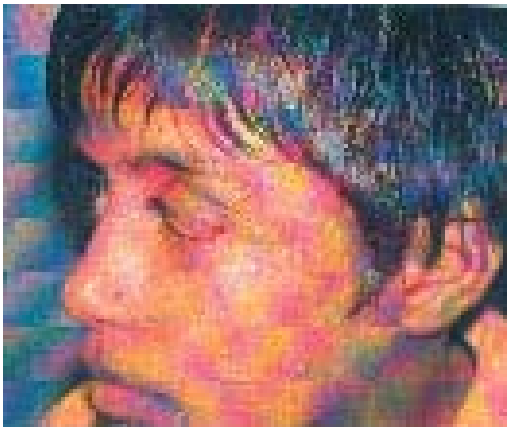

## Optic Nerve Glioma in Neurofibromatosis - I

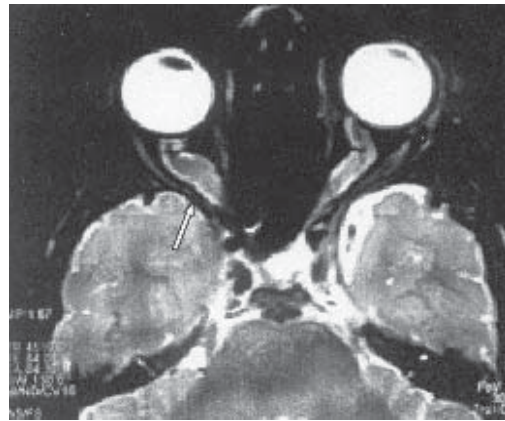
A ten-year-old girl presented with swelling on left upper eyelid, multiple hyper pigmented macules and small nodular swellings with hair growth all over the body since birth. Examination revealed hyper pigmented macules >1 cm in diameter, numerous in numbers on both legs. Hyper pigmented nodular lesion was noted in left temporofacial area and swelling on left upper eyelid with restricted upward movement (*Fig 1*). Computed tomography (CT) and Magnetic Resonance Imaging (MRI) of orbits revealed bilateral optic nerve glioma (*Fig 2*). MRI brain showed focal hyper intensities in right dentate nucleus, left cerebral peduncle and bilateral globus pallidus. Hyper intense lesions on T2-weighted MR images of the brain, predominantly located in the basal ganglia, the brainstem and cerebellum are a frequent finding in patients with Neurofibromatosis type-I. Thus, a diagnosis of Neurofibromatosis type-I was made.

Differential diagnosis of upper eyelid

swelling as seen in this patient includes tuberous sclerosis, hemangioma, nevus, xanthelasma, sudoriferous cyst and molluscum contagiosum. The differentiation can be made on the basis of history, clinical examination and associated symptoms. In tuberous sclerosis facial angiofibroma may involve the upper eyelid, is usually asymptomatic, may be associated with other dermal manifestations like shagreen patches, ash-leaf macules, occasional *café-au-lit* spots and there may be seizures and mental retardation. Eyelid hemangiomas are usually asymptomatic, unilateral and congenital and can be confirmed by appearance and blanching test. Nevus may be found on eyelids, are sometimes dome shaped, large with variable appearance. Xanthelasma is sometimes found in children with diabetes or hyperlipidemia and are yellowish plaque like lesions usually seen on nasal canthus. Sudoriferous cysts are asymptomatic inclusion cysts involving sweat glands and show transillumination on examination. Molluscum contagiosum, a dermal infection caused by pox virus, are flash colored nodules usually found in clusters and self limited.



*Fig. 1. Hyper pigmented nodular lesion and swelling on left upper eyelid.*



*Fig. 2. MRI showing bilateral thickened optic nerves (arrow) which were isotense on fat saturated T1 weighted image.*

Neurofibromatosis type-I (von Reckling-Hausen) disease is an autosomal dominant disorder with a frequency of 1 per 3000 births. It is believed to be generalized disorder of cells of neural crest origin. Neurofibromatosis -1 (NF-1) disease is caused by disruption of tumor suppressor gene. The NF-1 gene has been isolated, partially characterized, and is located at chromosome 17q 11.2. Different type of mutations include chromosome

translocation, insertion, deletions, and point mutation have been reported.

**Mahesh Maheshwari,  
Sheffali Gulati,**

*Department of Pediatrics,  
All India Institute of Medical Sciences,  
New Delhi 110 029, India.*

*Correspondence to:*

**Dr. Sheffali Gulati**

*E-mail: sheffalig@yahoo.com*

