

Juvenile Fibroadenoma of Breast

A 12-year-old girl presented with progressive enlargement of right breast for 2 months. It was not associated with any discharge, pain or history of trauma. On examination the right breast was uniformly swollen, non-tender, with no cracks or fissures. No definite lump was palpable though the entire breast had a firm consistency. Overlying skin was thin, tense, shiny, erythematous and superficial veins were visible. The axillary lymph nodes were not enlarged. The left breast was in SMR stage-III of development with normal consistency (*Fig. 1*). Ultrasonography of right breast revealed large heteroechoic mass with few diffusely scattered echogenic foci with post acoustic shadowing suggestive of calcific foci. Aspiration cytology of the lump showed sheets of benign ductal epithelial cells admixed with myoepithelial cells with background of benign bipolar nuclei and blood suggestive of fibroadenoma (confirmed as subsequent histopathology). There was no evidence of dysplasia or malignancy. Complete excision of right breast lesion was carried out using inframammary incision with preservation of nipple and areola complex. The patient is doing well on follow up.

Giant fibroadenoma of breast is uncommonly encountered in pre-adolescent age group. The other differential diagnosis to

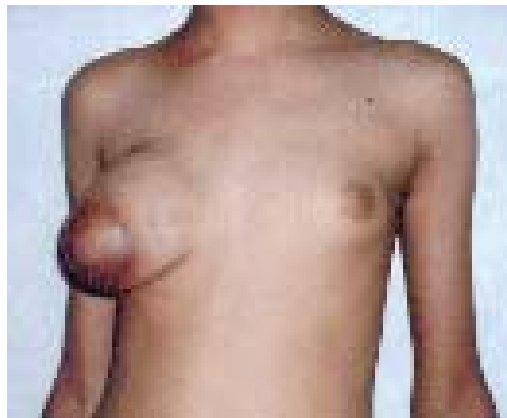


Fig. 1. Enlarged right breast due to fibroadenoma.

be considered in cases of unilateral breast enlargement in this age group is virginal hypertrophy of breast that is usually bilateral but one breast may be larger than the other. Overlying skin is normal and there is no significant lymph node enlargement. FNAC shows normal breast tissue. Other infrequent causes include post-traumatic fat necrosis and mastitis. In fat necrosis breast is usually not enlarged and a distinct lump is palpable while in mastitis all features of inflammation are seen.

**Atul Ahuja,
Anju Seth,**

*Department of Pediatrics,
Kalawati Saran Children's Hospital and
Lady Hardinge Medical College,
New Delhi 110 001, India.
E-mail: atahuja2001@yahoo.co.uk*