

Non-Bacterial Thrombotic Endocarditis in a Neonate

P. Vaideeswar
A. Sivaraman
J.R. Deshpande

Non-bacterial thrombotic endocarditis seldom affects the valves and the mural endocardium in the neonatal age. We report such a case in a one-day-old newborn. The pathogenesis may be related to altered hemodynamics due to perinatal stress.

Case Report

A one-day old male child was admitted in the neonatal nursery for respiratory distress. He was delivered by lower segment Caesarean section for abnormal lie (breech with hand prolapse) and non progression of labor. The child was appropriate for gestational age (34 weeks). The birth weight was 2.2 kg. The Apgar score was 8/10 after 5 and 10 minutes and cord pH 7.219. The hematocrit was 48% and platelets were adequate on a blood smear examination. On examination, the heart rate was 158/minute, respiratory rate 70/minute with grunting and intercostal retraction. Despite oxygen therapy, the child continued to have apneic spells and died within 19 hours of admission.

At autopsy, the heart was minimally en-

From the Department of Pathology, Seth G.S. Medical College and K.E.M. Hospital, Parel, Mumbai 400 012.

Reprint requests: Dr. Pradeep Vaideeswar, Department of Pathology, Seth G.S. Medical College and K.E.M. Hospital, Parel, Mumbai 400 012.

*Manuscript Received: March 25, 1997;
Initial review completed: May 6, 1997;
Revision Accepted: August 19, 1997*

larged (15 g). All the leaflets of the tricuspid valve showed pin-head sized, nodular, firm white vegetations along their atrial aspects (*Fig. 1*). Microscopically, these vegetations showed only fibrin and platelets. The lungs were dark red and rubbery. Most of the alveoli were collapsed with dilatation of the alveolar ducts. A few of these were lined by hyaline membranes. Other organs were unremarkable.

Discussion

Bland valvar or mural vegetations are rarely seen in the newborn. We had one such case (0.11%) among 904 neonatal autopsies in a five year period (1991-1995). A large series of 13 cases of neonatal non-bacterial thrombotic endocarditis was reported earlier(1). The neonates had a mean gestational age of 37.5 weeks and the mean age of death was 6.25 days. Vegetations were seen over the tricuspid valve in all, with additional involvement of the right atrial mural endocardium and the mitral valve in five cases. The authors observed a statistically significant association between persistent fetal circulation, thrombocytopenia and bland endocardial vegetations. Such a "combination could have led to hypoxia, disturbed hemodynamics and activation of platelets and procoagulants. This mechanism is further substantiated by a report(2), where valvar vegetations were identified by cross-sectional echocardiography in five neonates. Other factors like transient tricuspid regurgitation due to perinatal stress, hyaline membrane disease and physiologic polycythemia could also contribute to the pathogenetic mechanism(1,3).

In our case, neonatal stress due to prolonged labor and development of hyaline membrane disease resulted in hypoxia, leading to altered hemodynamics and coagulopathy. There were no features sug-

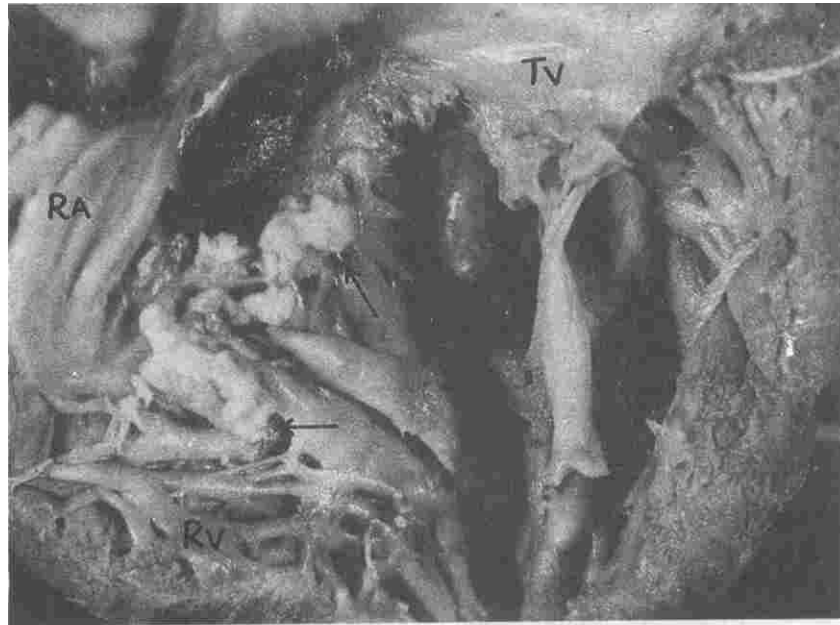


Fig. 1. Tricuspid valve (TV) with nodular white vegetations (arrows) over atrial aspect of the leaflets (RA-Right atrium, RV-Right ventricle).

gestive of persistent fetal circulation clinically or histopathologically

Acknowledgements

The authors are grateful to the Dean, Seth G. S. Medical College and K.E.M Hospital for permission to publish the article.

REFERENCES

1. Morrow WR, Haas JE, Benjamin DR.

Non bacterial endocardial thrombosis in neonates Relationship to persistent fetal circulation J Pediatr 1982;100: 117-122.

2. Menahem S, Robbie MJ, Rajaduran VS Valvar vegetations in the neonate due to fetal endocarditis Int J Cardiology 1991; 32: 103-105.

3. Krous HF Neonatal nonbacterial thrombotic endocarditis Arch Pathol Lab Med 1979;103: 73-78.

Renal Infarction Due to Umbilical Artery Catheters

R. Kishore Kumar
Malcolm G. Coulthard

Umbilical artery catheters allow reliable blood sampling and blood pressure moni-

From the Department of Pediatric Nephrology, Royal Victoria Infirmary, Newcastle upon Tyne NE14LP

Reprint requests: Dr. Malcolm G. Coulthard, Department of Pediatric Nephrology, Royal Victoria, Infirmary, Newcastle upon Tyne NE1 4LP.

Manuscript Received: July 24, 1997;

Initial review completed: August 6, 1997;

Revision Accepted: August 27, 1997