

## Hemiplegia

**T.S. Raghu Raman**

**K.K. Surendran**

**R.K. Gupta**

**A.K. Gupta**

**Ravichander**

**S.L. Sood**

Acute infantile hemiplegia is characterized by the sudden onset of hemiplegia in infancy or childhood usually prior to 6 years of age(1). In adult life, arterial occlusion is most frequently the consequence of arteriosclerosis of cerebral vasculature. In childhood, arterial occlusion usually results from congenital dysplasia of the vessels, cerebral arteritis, or trauma. Since the anterior cerebral circulation is usually affected, acute hemiplegia results. This clinical study was undertaken to review the cases of childhood hemiplegia especially with reference to the clinical presentation and radiological findings, and establish the possible etiology.

### Subjects and Methods

Children in the age group of 0 to 12 years admitted to a large referral hospital during the period Jan '94 to June '95 with hemiplegia were included in the study. The study was part by retrospective and part by prospective in nature. On admission, in

*From the Department of Pediatrics, Armed Forces Medical College, Pune 411 040.*

*Reprint requests: Wg. Cdr. T.S. Raghu Raman, Associate Professor, Department of Pediatrics, AFMC, Pune 411 040.*

*Manuscript received: October 14, 1995;*

*Initial review completed: February 6, 1996;*

*Revision accepted: July 10 1996*

every child, detailed history including onset and progress of the disease, associated symptomatology, antenatal, natal history and diagnostic and therapeutic interventions undergone was recorded. A careful and detailed clinical examination was conducted. Apart from routine investigations like complete blood counts, blood culture, serum electrolytes, CSF studies, EEG, CT scan, and MRI were done on individual basis and affordability. Angiographic studies were not performed. If permitted, autopsy studies were done.

The cases of hemiplegia were categorized under three groups, namely, (i) *Group A*: Associated with convulsions at the onset; (ii) *Group B*: not associated with convulsions at onset; and (iii) *Group C*: congenital hemiplegia. The following definitions were adopted: (i) *Birth asphyxia*: delayed initiation of breathing historically or documented by Apgar score of <6 at 1 min; (ii) *Birth injuries*: avoidable and unavoidable trauma sustained during the process of birth. On the basis of clinical features, EEG recordings and CT scan findings, an attempt was made to determine the cause of hemiplegia. Follow up of individual cases was not included in the study.

### Results

Forty children (21 boys and 19 girls) with hemiplegia formed the study material. Twenty eight cases were right handed. Nineteen children belonged to Group A, 9 to Group B, and 12 to Group C. Majority of the children in Group A were below 2 years of age (10/19) while all 9 cases in Group B were above 2 years. Majority of children had acute onset of hemiplegia (15/19 in Group A and 2/9 in Group B). Other important symptomatology included unconsciousness, fever, vomiting and headache. Past history of convulsions was elicited in 13 cases (Group A-10, Group C-3). Delayed developmental history was ob-

tained in 10 children (Group A-7, Group C-3). There was a single case of head injury. As a group, in congenital hemiplegia the illness was not suspected earlier by the parents. The time period between the onset of hemiparesis and admission varied from one day to months.

There were almost equal number of right and left sided hemiplegia. An important and distinctive feature of congenital hemiplegia cases was hypoplasia of limbs including the nails on the affected side. However, none of these children had demonstrable sensory loss. There were two children who had cardiovascular disease resulting in hemiplegia. One of them was a 10 years old male child with features of Marfan's syndrome and associated congenital bicuspid aortic valve and aortic regurgitation. The other was a 6 years old female child with features of polyangitis overlap syndrome and associated cardiomyopathy (Table I).

Based on CSF examination, 10 children were diagnosed to have meningitis (7 tubercular and 3 pyogenic) and one child in -

TABLE I—Clinical Features in Hemiplegia (n=40)

Features	Group A	Group B	Group C
<i>Hemiplegia</i>			
Right	10	2	9
Left	9	7	3
<i>Cranial nerve palsy</i>			
VII	10	4	—
III	2	—	—
Aphasia	5	1	—
Contractures	4	1	7
Limb shortening	13	1	12
Fundus	normal	normal	normal
Hypoplasia limbs/nails	—	—	12

tracranial hemorrhage. Abnormal EEG recordings were documented in 7 out of 11 cases. CT scan done in 23 cases revealed significant findings. Figs. 1 & 2 highlight two important CT scan findings. Table II summarizes the etiological classification based on the clinical features and investigative profile.

### Discussion

Infantile hemiplegia is not a disease, but rather is the non specific response of the central nervous system to multiple and varied conditions. These morbid processes, primary or secondary usually involve the blood vessels of the brain. Hemiplegia is the only consistent clinical feature of this ischemic or necrotic state. The mode of onset, subsequent clinical course, prognosis and the modality of management are in large part dependent upon specific etio-

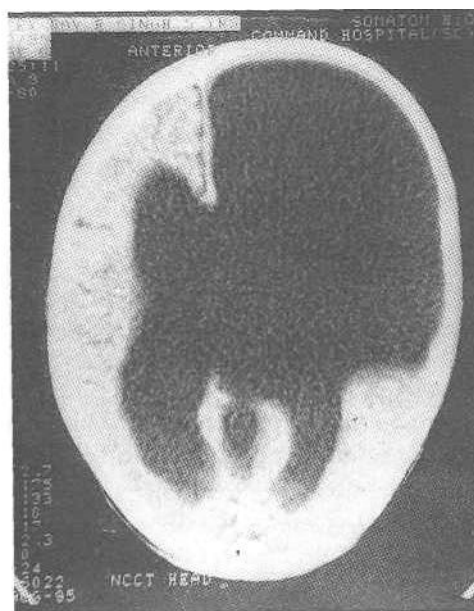


Fig. 1. Left porencephalic cyst in the left frontoparietal region in communication with lateral ventricle in a 5 year old with congenital hemiplegia.

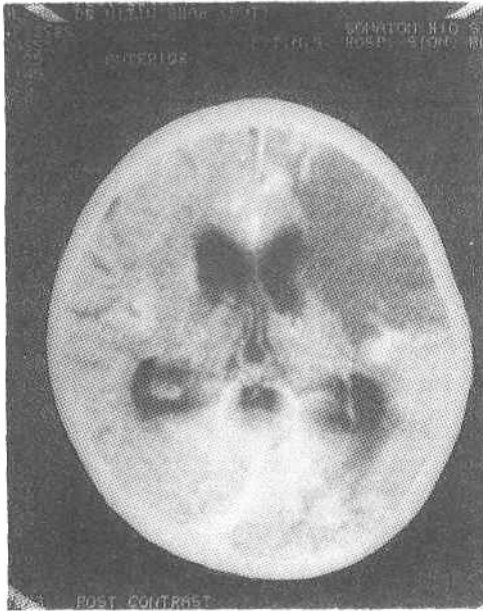


Fig. 2. Non enhancing hypodense area seen in the left parietal and frontal region with moderate dilatation of the lateral, III and IV ventricles. Exudates are also seen in the basal cisterns. The findings are suggestive of infarct with mild to moderate hydrocephalus in a 2 year old with tuberculous meningitis.

gic delineation. With improved diagnostic techniques many more children are now given a specific diagnosis.

Hemiplegia in childhood is not rare. Ford recalled observing some 200 patients with this condition at the Harriet Lane home in Baltimore(1). Parlauis *et al* reported the annual incidence of cerebrovascular disease in children to be 2.5 cases per 100,000 population every year(2). There was no gender difference in the present study, though a sex ratio of 1.5 in favor of males has been reported(3).

Acquired hemiplegia in an apparently healthy child by itself is not a common disease. Cases of acquired hemiplegia in

Group A had associated seizures at onset. Seizures are often an ischemic symptom in an infant brain which probably explains the preponderance of children upto 2 years of age in Group A(4). Onset of hemiplegia in the present study was acute in majority of Group A children (15/19), while only 2/9 children in Group B had acute onset. This difference has also been observed earlier(5). Loss of consciousness was a constant feature in those children with seizure at onset. Presence of fever, either before or at the onset of hemiplegia, seen more commonly in Group A cases, might have been due to the high frequency of infection in the younger age group. A unilateral growth arrest of the thumb nail, hand or extremity in a child with focal seizure disorder and hemiplegia suggests a chronic condition such as porencephalic cyst, arterio-venous malformation or cortical atrophy in the opposite cortex(6). In the present study, all the 12 cases of congenital hemiplegia had these features which could be correlated with CT scan findings. Associated facial paresis, disorders of speech and contractures have been reported earlier also(7). The important investigations include CSF studies, EEG, CT scan and MRI. Analysis of CSF can identify subarachnoid hemorrhage and meningitis. CT scan was done in 23 of 40 cases. Significant findings were observed in 20 of these cases correlated with clinical diagnosis. In an earlier study on the relationship of CT scan and clinical findings in children with congenital hemiplegia, four types of changes were observed. The scan can be normal or show unilateral ventricular enlargement with involvement of the periventricular white matter, or a wedge shaped cavitation of the cortex, or it can demonstrate major involvement of both the cortex and white matter(8). The value of CT scan in establishing the diagnosis of hemiplegia is well established(9).

TABLE II—Etiological Diagnosis in Hemiplegia (n=40)

Etiology	Specific condition	Number	(%)
Infection	Pyogenic meningitis	3	(7.5)
	Tubercular meningitis	7	(17.5)
Vascular	Intracranial hemorrhage	3	(7.5)
	Thromboembolism	5	(12.5)
Perinatal insult	Birth asphyxia	5	(12.5)
	Birth injury	3	(7.5)
	Porencephaly	2	(5)
	Unidentified	2	(5)
Trauma	Head injury	1	(2.5)
Pressure effect	Frontal astrocytoma	1	(2.5)
Cardiovascular	Bicuspid aortic valve and aortic regurgitation	1	(2.5)
	Polyangitis overlap syndrome and cardiomyopathy	1	(2.5)
Undiagnosed		8	(20)

Included in congenital hemiplegia are prenatal and perinatal disorders which may not be recognized until several months after birth, although the insult to the developing brain was sustained earlier. The commonest cause is probably a vascular lesion occurring during birth. Less often the condition may be due to a congenital deformity, such as true porencephaly or intracranial angioma(10). In acquired hemiplegia, viral and bacterial infections, trauma, immunizations, systemic diseases, cerebral arterio-venous malformations, cardiac abnormalities, status epilepticus and neoplasms and their ensuing complications are recognized etiologic factors. One important survey merits mention in this context. Of the 86 children with acute hemiplegia seen during a 21 year interval at the Colombian Presbyterian Medical Center, 11 were secondary to trauma, 11 had infection of CNS, 10 had miscellaneous conditions while in the remaining 25 cases, neither a specific etiology nor radiologic diagnosis could be established(8). Solomon

*et al.*(11) in a review of 86 infants and children presenting 6 months to 20 years after becoming acutely hemiplegic, concluded that the onset of hemiplegia associated with seizures in children with occlusive vascular disease portended subsequent epilepsy and a persistent motor deficit. In the present study also, epilepsy and persistent hemiplegic motor deficit was seen mostly in cases presenting with seizures and subjects with congenital hemiplegia.

It is concluded that hemiplegia of childhood in our setting occurs due to diverse etiologies, many of which can be accurately identified with the use of newer non invasive diagnostic modalities.

#### REFERENCES

1. Ford FR, Schaffer AJ. The etiology of infantile (acquired) hemiplegia. *Arch Neurol Psychiatry* 1927,18: 323-347.
2. Parluis SG, Gould JR, Zito ZL. Stroke in children. *Adv Pediatr* 1991, 38:151-171.
3. Marie-Th Abena Obama, Dongmo L,

- Nkemayim, Mbede J, Hagbe P. Stroke in children in Yaiunde, Cameroon. *Indian Pediatr* 1994, 31:791-794.
4. Bickerstaff ER. Cerebrovascular disease in infancy and childhood. *In: Hand Book of Clinical Neurology, Part II, Vol 12.* Eds. Vinken PJ, Bruyn GW. Oxford, North Holland Publishing Company, 1972, p 341.
  5. Malik GK, Sharma B, Misra PK, Chhabra DK, Tandon SC. A study of acute hemiplegia in children. *Indian Pediatr* 1979,16: 867-872.
  6. Behrman RE, Kliegman RM. Seizures in childhood. *In: Nelson Textbook of Pediatrics, 14th edn.* Eds Behrman RE, Kliegman RM. Philadelphia, W.B. Saunders Company 1992, pp 1491-1503.
  7. Gold AP, Carer S. Acute hemiplegia of infancy and childhood. *Pediatr Clin North Am* 1976, 23: 413-433.
  8. Molteni B. Relationship between CT patterns, clinical findings and etiological factors in children born at term, affected by congenital hemiparesis. *Neuropediatrics* 1987,18: 75-80.
  9. Ramsay RG. Congenital disorders of brain. *In: Neuroradiology 3rd edn.* Ed. Ramsay RG Philadelphia, W.B. Saunders, 1994 pp 137-173, 431-494.
  10. Waljon JN. Congenital and infantile hemiplegia. *In: Brain's Diseases of Nervous System, 8th edn.* Ed. Waljon JN. Oxford, Oxford University Press, 1977, pp 632-636.
  11. Solomon GE, Hilal SK, Gold AP, Carter S. Natural history of acute hemiplegia in childhood. *Brain* 1970, 93:107-120.