

## **Unusual Congenital Limb Anomalies**

**R.P. Agarwal  
M.C. Gupta  
D.K. Sharma  
Rajiv Gupta  
Rahul Nehra**

We present two very unusual cases of congenital limb anomalies. The first case had bilateral agenesis of proximal two thirds of femur, whole of the fibulae and patellae in lower limbs, and above elbow amputation of right upper limb. Only one such case has been reported earlier (1).

---

*From the L.L.R.M. Medical College, Meerut 250 004.*

*Reprint requests: Dr. R.P. Agarwal, Associate Professor, Department of Orthopedics, L-5, LLRM Medical College, Meerut 250 004.*

*Received for publication: December 21, 1993;  
Accepted: December 29, 1994*

---

Frantz and O'Rahilly(2) also reported a single case of bilateral femoral agenesis while Kacker and Agarwal(3) reported a case of unilateral complete femoral agenesis. The second case had congenital talipes equinovarus with 8 toes polydactyly (having 8 sets of metatarsals and phalanges) along with agenesis of patella on left side. Such an anomaly does not seem to have been documented earlier.

### **Case Report**

*Case 1:* A 5-year-old male child was born of full term normal delivery and of a non-consanguineous marriage. Milestones were normal except disability due to abnormalities. The child was able to walk like a duck. Height was 100 cm (upper segment = 83 cm, lower segment = 17 cm).

*Case 2:* A 3-year-old male child was born of full term normal delivery and of a non-consanguineous marriage. Milestones were normal except disability due to abnormalities. The salient clinico-radiological features (*Figs. 1 & 2*) of both cases are summarized in *Table I*.

CASE REPORT

TABLE I—Salient Features of The Two Cases

Feature	Features	
	Case 1	Case 2
Family history	Insignificant	Insignificant
Perinatal history	Insignificant	Insignificant
Face	Facial asymmetry	Normal
Pelvis	Broad	Normal
Genitals	Small penis and scrotum, testes not palpable	Normal
Upper limb	Congenital above elbow amputation (Lt.)	Normal
Lower limb		
Hip joints	Absent	Normal
Thigh	Small, proximal 2/3 of femur absent on both sides	Normal
Knee joints	Fixed, patella absent	Mobile Rt. patella absent
Leg	Small, fibulae absent	Rt. leg normal, Lt. leg—wasting of muscles and medial rotation of tibia
Foot	Valgoid feet	Rt. foot normal, Lt. foot—heel small, fore foot broad, foot planter flexed inverted and adducted, 8 toes polydactyly, 8 sets of metatarsals and phalanges

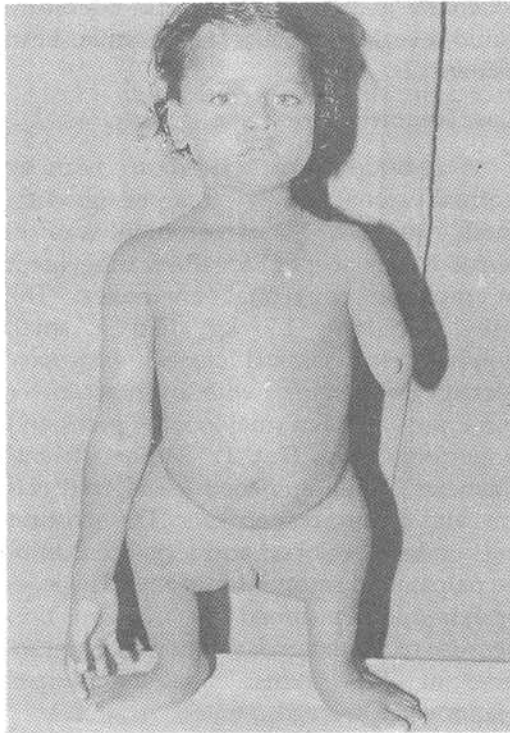


Fig. 1. Case 1 with agenesia of left elbow, forearm and hand, bilateral proximal phocomelia and valgoid feet.

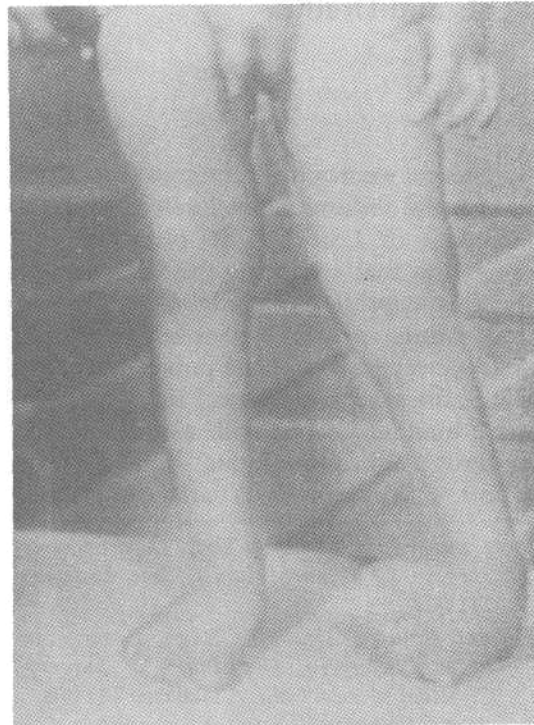

Fig. 2. Case 2 showing CTEV with 8 toes polydactyly and agenesia of patella.

### Discussion

Congenital bilateral proximal phocomelia with intercalary fibular hemimelia, agenesis of patellae and above elbow amputation of right upper limb is a very rare condition. Only Fixsen and Lloyd (1) have reported a similar case. There was multiple agenesis of bones along with primary hypogonadism and facial asymmetry. Similarly, 8 toes polydactyly with fully developed 8 sets of metatarsals and phalanges in association with ipsilateral club foot and agenesis of patella is an unusual anomaly not reported previously. These anomalies

are caused by multiple dysmorphogens during intrauterine life but the parents were not able to pinpoint them because of their illiteracy and ignorance

### REFERENCES

1. Fixsen JA, Lloyd RGC. Natural history and treatment of proximal femoral dysplasia. *J Bone Joint Surgery* 1974, 56B: 86-95.
2. Frantz CH, O'Rahilly R. Congenital skeletal limb deficiency. *J Bone Joint Surgery* 1961, 43A: 1202-1206.
3. Kacker JN, Agarwal RP. Proximal phocomelia of right lower limb. *J Indian Med Assoc* 1976, 6:133-134.

