

Fate of Sharp Metallic Foreign Bodies

Foreign body ingestion is a common problem in children. We share our experience of managing sharp metallic foreign body ingestion in four children.

A 7-month-old girl was brought to us with complaints of episodic excessive cry and blood tinged vomitus since two days. X-ray abdomen showed a hair pin in the small bowel loops (**Fig. 1A**). The baby was clinically stable without any symptoms. After 3 hours of hospitalization (36 hours after ingestion); baby passed the foreign body in stools (**Fig. 1B**).

A 6-year-old boy presented to us with accidental ingestion of a nail; there was no history of vomiting or pain abdomen. X-ray revealed sharp metallic foreign body in the stomach lying transversely (**Fig. 1C**). Under close observation, child passed the nail in the stools after 30 hours of its ingestion (**Fig. 1D**).

A 9-month-old girl was brought to us with history of accidental ingestion of an open safety pin. Serial X-rays showed the uneventful transit of foreign body through gastrointestinal tract (**Fig. 1E**). Baby passed the foreign body spontaneously in the stools after 36 hours of its ingestion (**Fig. 1F**).

A 13-year-old girl was brought to us with history of accidental ingestion of a table pin. X-ray revealed a sharp metallic foreign body in the small bowel (**Fig. 1G**). Her psychiatric evaluation was normal. She was closely observed with daily X-rays with watchful waiting, and she passed the foreign body in the stool after 10 days (**Fig. 1H**).

Majority of foreign bodies reaching the stomach will pass spontaneously in stools uneventfully [1]. However, the sharp metallic foreign body may rarely migrate to almost any intra-abdominal organ causing serious complications such as bowel perforation, bleeding, and obstruction [1,2]. As per Jackson's statement "advancing points perforate and trailing points do not"; *i.e.*, sharp metallic foreign body travels with its blunt end first [2,3]. This was witnessed in our series.

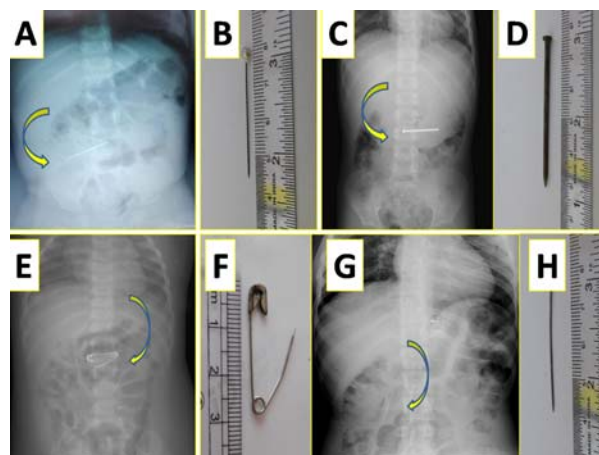


Fig. 1 Ingested sharp metallic foreign bodies in four children, as seen in X-ray abdomen (A,C,E,G), and after spontaneous passage in stools (B,D,F,H).

Endoscopic retrieval of sharp metallic foreign bodies, even if they have reached the stomach uneventfully, is advocated by some experts, while many centers manage them with watchful waiting [3,4]. Those not amenable to endoscopic retrieval need to be followed-up with daily radiographs; surgical removal should be contemplated if it fails to progress over three days [2,3].

JAYALAXMI SHRIPATI AIHOLE
 Department of Paediatric Surgery,
 Indira Gandhi Institute of Child Health,
 Bengaluru, Karnataka, India.
 jayalaxmisaihole@yahoo.com

REFERENCES

- Samual DD, Adegboyega OF, Ene OM. Spontaneous expulsion of ingested foreign bodies. Case series and review of literature. *American J Med Case Rep*. 2015;3:272-5.
- Spitz L. Management of ingested foreign bodies in childhood. *Br Med J*. 1971;4:469-72.
- Lee JH, Lee JS, Kim MJ, Choe YH. Initial location determines spontaneous passage of foreign bodies from the gastrointestinal tract in children. *Pediatr Emerg Care*. 2011;27:284-9.
- Gün F, Salman T, Abbasoglu L, Celik R, Celik A. Safety-pin ingestion in children: A cultural fact. *Pediatr Surg Int*. 2003;9:482-4.