

induced hyperthyroidism was suspected. Blood pressure recording in right upper arm was 140/100 mmHg. Her thyroid profile was within normal limits.

Child was put on propranolol and was investigated for secondary causes of hypertension. Renal function test, plasma adrenaline, noradrenaline; urine 24 hours metanephrine, 24 hours VMA; serum cortisol, aldosterone, and renin were within normal limits. CT abdomen showed normal sized kidneys and normal appearing liver and spleen. Echocardiography was within normal limits. CT renal angiography showed single renal artery on both sides with no coarctation or aneurysm, single renal veins on both sides, abnormal large splenorenal shunt between splenic vein and left renal vein, left renal vein dilated measuring 1.1 cm, shunt measured 0.6 cm, portal vein narrowed to 0.2 cm (**Fig. 1**).

Presently the child is on propranolol 5 mg twice a day, and L-thyroxine 50 µg daily. Her growth and milestones are within normal limits. Her BP and thyroid status is within range.

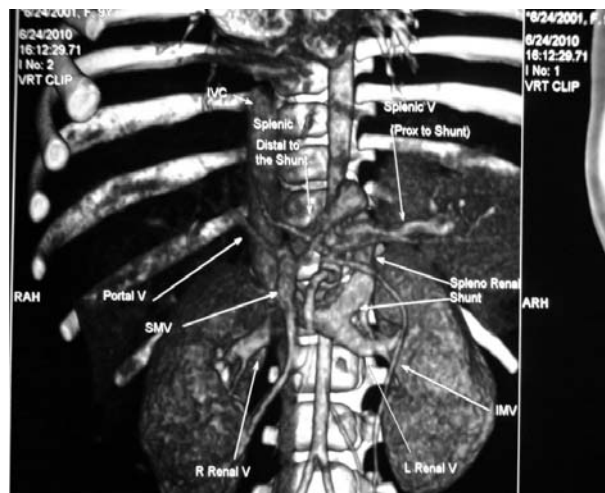


Fig.1 CT renal angiography showing large splenorenal shunt.

Biliary Atresia with Cytomegalovirus

We read with interest “Evolving biliary atresia with cytomegalovirus” in the August issue [1], as the etiology and pathogenesis of biliary atresia (BA) still remains an enigma. Instead of answers, we are left with several

Our dilemma was whether hypertension is due to the splenorenal shunt and the future management of this shunt. Pulmonary hypertension has been reported in cases with congenital porto-systemic venous shunt but we could not get any literature reporting systemic hypertension in this condition. Extremely hypoplastic kidneys have been reported in an aborted fetus with congenital splenorenal venous shunt. But ultrasonography shows bilateral normal size kidneys in this child.

It is reported that patients with congenital splenorenal shunt may be asymptomatic in the initial years but develop portosystemic encephalopathy at later stage. Hepatic cirrhosis has also been reported. We are following her with serial ammonia levels which are within normal limits. CT guided liver biopsy shows normal histology.

NIBEDITA MITRA AND C ANANDHI

*Southern Railway Head Quarter Hospital
Chennai, India.*

nibeditamitra1@yahoo.co.in

REFERENCES

- Ohno T, Muneuchi J, Ihara K, Yuge T, Kanaya Y, Yamaki S, *et al.* Pulmonary hypertension in patients with congenital portosystemic venous shunt: a previously unrecognized association. *Pediatrics*. 2008;121:e892-9.
- Ji EK, Yoo SJ, Kim JH, Cho KS. Congenital splenorenal venous shunt detected by prenatal ultrasonography. *J Ultrasound Med*. 1999;18:437-9.
- Ishii Y, Inagaki Y, Hirai K, Aoki T. Hepatic encephalopathy caused by congenital extrahepatic portosystemic venous shunt. *J Hepatobiliary Pancreat Surg*. 2000;7:524-8.
- Yamagami T, Nakamura T, Iida S, Kato T, Tanaka O, Matsushima S, *et al.* Hepatic encephalopathy secondary to intrahepatic portosystemic venous shunt: balloon-occluded retrograde transvenous embolization with n-butyl cyanoacrylate and microcoils. *Cardiovasc Intervent Radiol*. 2002;25:219-21.
- Ishii Y, Inagaki Y, Hirai K, Aoki T. Hepatic encephalopathy caused by congenital extrahepatic portosystemic venous shunt. *J Hepatobiliary Pancreat Surg*. 2000;7:524-8.

questions in our mind. It was not clear whether the author is implementing CMV as a cause for biliary atresia in these two cases or as a red herring? Though, there are several speculations about CMV causing biliary atresia, so far there is no hard evidence implementing the virus as a causative agent [2,3]. In the first case early liver decompensation and low gamma-glutamyl transferase (GGT of 10 IU/L) in the presence of severe cholestasis raise the suspicion of an underlying metabolic problem

such as Progressive familial intrahepatic cholestasis (PFIC). A combination of PFIC and biliary atresia is unusual, but worthwhile considering as a possibility.

The most important question in both the cases is about timing of portoenterostomy. Surgery was undertaken when the children were more than 6 months old. Chardot, *et al.* showed that, the success of portoenterostomy is practically nil after 141 days [4]. In the absence of liver transplantation facility surgery one could argue for late surgery, as it might work in the absence of severe cirrhosis with stable synthetic liver function and give patients some survival advantage. The author could put forward the above mentioned argument for the second case, but for the first case, we are intrigued by the fact that the child underwent portoenterostomy when he/she was in frank liver failure, where Kasai's procedure is contraindicated [5].

NARESH P SHANMUGAM AND V JAYANTHI
*Department of Paediatric Hepatology,
 Gastroenterology and Nutrition,
 Global Hospitals and Health City,
 Chennai, India.
 drnareshps@gmail.com*

REFERENCES

1. Mohanty S, Shah I, Bhatnagar S. Evolving biliary atresia with cytomegalovirus. *Indian Pediatr.* 2011;48:644-6.
2. Rauschenfels S, Krassmann M, Al-Masri AN, Verhagen W, Leonhardt J, Kuebler JF, *et al.* Incidence of hepatotropic viruses in biliary atresia. *Eur J Pediatr.* 2009;4:469-76.
3. Hartley JL, Davenport M, Kelly DA. Biliary atresia. *Lancet.* 2009;14:1704-13.
4. Chardot C, Carton M, Spire-Bendelac N, Le Pommelet C, Golmard J, Reding R, *et al.* Is the Kasai operation still indicated in children older than 3 months diagnosed with biliary atresia? *J Pediatr.* 2001;2:224-8.
5. Engelmann G, Schmidt J, Oh J, Lenhartz H, Wenning D, Teufel U, *et al.* Indications for pediatric liver transplantation. Data from the Heidelberg pediatric liver transplantation program. *Nephrol Dial Transplant.* 2007;22:viii23-8.

REPLY

We thank Shanmugam and Jayanthi for raising questions that are important while managing children with biliary atresia. In both our patients, we had children who progressed to biliary atresia and had simultaneous active CMV infection. Whether CMV was the cause of this progression remains unknown as we have not been able to depict CMV in the liver tissue. CMV infection has been

found in a large number of extra-hepatic biliary atresia (EHBA) cases [1,2]. However, etiopathogenesis of infection and EHBA still remains little understood and till then it cannot be established that CMV can cause EHBA. However the association is too frequent to be ignored.

Regarding age of surgery of both patients, it is known that the prognosis of the Kasai operation worsens when the age of the child at surgery increases [3]. Liver transplant in patients with biliary atresia is expensive and not easily accessible and available in our country. Thus, portoenterostomy may remain the only option in most of these patients. In both our patients, parents refused the option of liver transplant. Chardot, *et al.* [4] also reported that the five year survival rate in patients who got operated after 90 days of age was 25%±6.1% whereas in those in whom surgery was not done, only one patient survived till five years [4]. Survival was 100% with those having biliary atresia limited to common bile duct and those who did not have cystic biliary atresia or splenic malformations. Similarly, Davenport, *et al.*, [5] showed that age of surgery had no effect on isolated biliary atresia as compared to those with associated cysts or splenic malformation [5]. These data suggest that although everything should be done to perform the Kasai operation as early as possible, it still has a chance of success when performed after the age of 3 months, especially in patients without embryonal biliary atresia. In our patients, biliary atresia evolved over a period of time and thus a Kasai surgery may not even have been feasible earlier.

IRA SHAH
irashah@pediatricconcall.com

REFERENCES

1. Fischler B, Ehrnst A, Forsgren M, Orvell C, Nemeth A. The viral association of neonatal cholestasis in Sweden: a possible link between cytomegalovirus infection and extrahepatic biliary atresia. *J Pediatr Gastroenterol Nutr.* 1998;27:57-64.
2. Tarr PI, Haas JE, Christie DL. Biliary atresia, cytomegalovirus, and age at referral. *Pediatrics.* 1996;97:828-31.
3. Schneider BL, Brown M, Haber B, *et al.* A multicenter study of the outcome of biliary atresia in the United States, 1997 to 2000. *J Pediatr.* 2006;148:467-74.
4. Chardot C, Carton M, Spire-Bendelac N, Le Pommelet C, Golmard J, Reding R, *et al.* Is the Kasai operation still indicated in children older than 3 months diagnosed with biliary atresia? *J Pediatr.* 2001;2:224-8.
5. Davenport M, Caponcelli E, Livesey E, Hadzic N, Howard E. Surgical outcome in biliary atresia: etiology affects the influence of age at surgery. *Ann Surg.* 2008;247:694-8.