

## Interrupted Aortic Arch and Aortopulmonary Window Associated with Complete Atrioventricular Septal Defect

V VUKOMANOVIC, M STAJEVIC, S PRIJIC AND BJELAKOVIC

From the Departments of Pediatric Cardiology and \*Pediatric Cardiosurgery, Mother and Child Health Institute, Belgrade, Serbia; and †Department of Pediatric Cardiology, Clinic of Paediatrics, Clinical Center Nis, Serbia.

### Correspondence to:

Dr Vukomanovic Vladislav, Mother and Child Health Institute, Department of Paediatric Cardiology, R Dakica 6-8 St., 11070 Belgrade, Serbia.

vvladavuk@ptt.rs

Received: October 13, 2009;

Initial review: March 10, 2010;

Accepted: October 27, 2010.

We report a rare case of a neonate with interrupted aortic arch, aortopulmonary window and complete atrioventricular septal defect. To the best of our knowledge, this unusual triad has not been previously described. The main question of the surgical strategy for CAVSD, in setting of associated defects, is to classify the CAVSD as balanced or unbalanced.

**Key words:** Aortopulmonary window, Complete atrioventricular septal defect, Interrupted aortic arch.

Interrupted aortic arch (IAA) is the most frequently associated major lesion (23%) in patients with aortopulmonary window (APW), while APW can be detected in only 5% of patients with IAA. To our knowledge, 44 patients with associated IAA and APW were reported. Only a few associated major cardiac malformations, such as aortic valve atresia, anomalous origin of left coronary artery and pulmonary artery sling, were described in these patients, but complete atrioventricular septal defect (CAVSD) has not been reported yet. The diagnosis of this unusual triad was made by transthoracic echocardiography and confirmed intraoperatively and after autopsy.

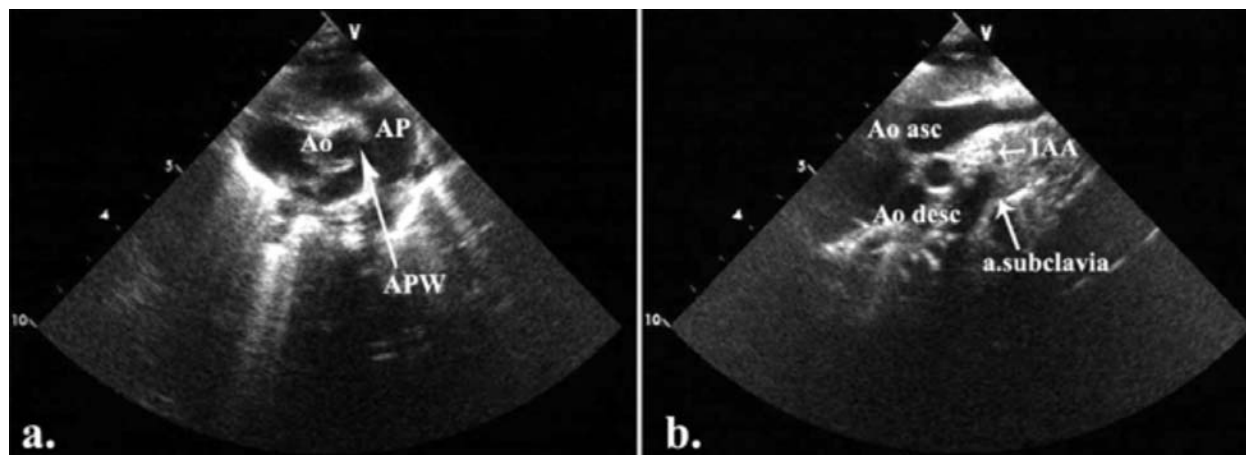
### CASE REPORT

A male newborn, weighting 3.280 kg, was admitted in our Institution on his 4<sup>th</sup> day of life. He was moribund, dispneic, tachycardic and cyanotic. He was nondysmorphic on evaluation. The liver was palpable 4cm below the right costal margin. Peripheral pulses were not palpable. The cardiac auscultation disclosed a gallop rhythm and a grade 2/6 ejection systolic murmur. The electrocardiogram showed a normal sinus rhythm, right axis deviation, right atrial enlargement, right ventricular hypertrophy, and nonspecific changes in ST segment. The chest X-ray demonstrated gross cardiomegaly and increased pulmonary vascular markings. Blood gas analysis revealed metabolic acidosis. He was ventilated and managed medically with prostaglandin E, dobutamin and dopamine. After overnight stabilization, the repair of the cardiovascular defects was performed. Fatal outcome occurred in the early postoperative course.

Echocardiogram revealed situs solitus, atrioventricular and ventriculoarterial concordance. The

left-sided superior caval vein drained to the right atrium via enlarged coronary sinus. Right ventricle was well developed, and left ventricle was border sized with AV valve index (left AV valve/total AV valve area) estimated as 0.4. There was a huge CAVSD with single left anterolaterally papillary muscle and common atrioventricular valve attached to the crest of the ventricular septum by chordae (**Fig. 1a**). Color Doppler demonstrated moderate regurgitation on the atrioventricular valve. The large aortopulmonary communication was observed just above tricuspid and nonstenotic aortic valve (APW- type 1). The relatively small ascending aorta was giving rise right and left common carotid arteries. The left subclavian artery was noticed arising from descending aorta just before the patent ductus arteriosus (IAA – type B) (**Fig. 1b**).

Post sternotomy, a hypoplastic and poorly ventilated left lung was immediately noted, which did not respond adequately to manual hyperventilation. Left persistent superior caval vein was dominant. Aortic arch was interrupted after the left carotid artery. Resection of ductus arteriosus and ligation of the left subclavian artery was performed in deep hypothermic cardiopulmonary bypass with mobilization of the descending aorta. The APW was 10 mm in diameter. A transection of the APW was done and the descending aorta anastomosed directly to the aortic part of the APW. The pulmonary artery was reconstructed with autologous pericardium. Cardio-pulmonary bypass was reinstated. Due to the border sized left ventricle, we decided to delay the complete repair of the CAVSD. After the first cessation of the cardiopulmonary bypass and initial promising hemodynamics with moderate inotropic support of 10 µg/kg/min of dopamine, the child developed sudden pulmonary edema with severe blood stasis in the left lung. Reinstitution of cardiopulmonary bypass and



**FIG. 1** (a) The defect in the aortopulmonary septum was seen in parasternal short-axis. Two separate aortic and pulmonary valve were present. Ao-aorta; AP-pulmonary artery; APW-aortopulmonary window. (b) Suprasternal long-axis view demonstrated the interruption of the aortic arch between left common carotid and left subclavian artery. Ao asc-ascending aorta; Ao desc-descending aorta; IAA-interrupted aortic arch.

prolonged circulatory support gave no effect. Low cardiac output and severe left lung blood stasis led to the lethal outcome. The diagnosis was re-confirmed after autopsy.

#### DISCUSSION

The associations between IAA and CAVSD, as well as between APW and CAVSD were reported previously [1,2]. IAA is present in approximately 1.3% and APW in only 0.2% of patients with congenital heart disease [3-5]. CAVSD comprises 5%-8% of all congenital heart defects and most frequently is associated with trisomy 21, but there is considerable evidence of genetic heterogeneity.

Sporadic reports of surgical treatment of IAA and APW with successful results have been reported in the literature [6,7]. In our case, the complex lesions of the great arteries was complicated by intracardiac finding of a CAVSD with a single papillary muscle in the left ventricle and intraoperative finding of a very poorly ventilated hypoplastic left lung. Although a satisfactory repair of the arch and the aortopulmonary window was obtained with a minimal gradient across the aortic anastomosis of 8 mmHg, the intraoperative decision to go for a staged approach rather than attempt to correct the CAVSD in the same procedure was made [8].

As echocardiographic AV valve index was borderline, our patient could not be clearly classified as unbalanced or balanced [9]. The decision for a staged approach was made based on the facts that there was a high probability of an unbalanced left ventricle with parachute deformity of the left sided atrioventricular valve and that a univentricular repair would be a more probable option. The great concern was the poorly developed and ventilated left lung,

technical challenges for the surgeon and associated anomalies (IAA, APW).

Although there are no established guidelines in unbalanced CAVSD for deciding between biventricular or univentricular repair, AV valve index could effectively characterizes the anatomic substrate and selects surgical strategy [9,10]. The main item of the operative strategy for CAVSD, in setting of great arteries anomalies, is to classify the CAVSD as balanced or unbalanced.

*Contributors:* All persons designated as authors qualified for the authorship. They reached authorship credit by contributions in concept, design and article drafting. Also they helped with final approval of the version to be published.

*Funding:* None; *Competing interests:* None stated.

#### REFERENCES

1. Browdie DA, Norberg W, Devig P, Atwood G, Damle J, Agnew R, *et al*. Surgical management in interrupted aortic arch and atrioventricular canal. *J Thorac Cardiovasc Surg.* 1984;88:764-9.
2. McElhinney DB, Paridon S, Spray TL. Aortopulmonary window associated with complete atrioventricular septal defect. *J Thorac Cardiovasc Surg.* 2000;119:1284-5.
3. Brown JW, Ruzmetov M, Okada Y, Vijay P, Rodefeld MD, Turrentine MW. Outcomes in patients with interrupted aortic arch and associated anomalies: a 20-year experience. *Eur J Cardiothorac Surg.* 2006;29:666-74.
4. Oosterhof T, Azakie A, Freedom RM, Williams GW, McCrindle WB. Associated factors and trends in outcomes of interrupted aortic arch. *Ann Thorac Surg.* 2004;78:1696-702.
5. Backer CL, Mavroudis C. Surgical management of aortopulmonary window: a 40-year experience. *Eur J Cardiothorac Surg.* 2002;21:773-9.

6. Davies MJ, Dyamenahalli U, Leanage RR, Firmin RK. Total one-stage repair of aortopulmonary window and interrupted aortic arch in a neonate. *Pediatr Cardiol*. 1996;17:122-4.
7. Konstantinov IE, Karamlou T, Williams WG, Quaegebeur JM, DeNido PJ, Spray TL, *et al*. Surgical management of aortopulmonary window associated with interrupted aortic arch: A Congenital Heart Surgeons Society study. *J Thorac Cardiovasc Surg*. 2006;131:1136-41.
8. Codispoti M, Mankad PS. One-stage repair of interrupted aortic arch, aortopulmonary window, and anomalous origin of right pulmonary artery with autologous tissues. *Ann Thorac Surg*. 1998; 66:264-7.
9. Jegatheeswaran A, Pizarro C, Caldarone CA, Cohen MS, Baffa JM, Gremmels DB, *et al*. Echocardiographic definition and surgical decision-making in unbalanced atrioventricular septal defect. *Circulation*. 2010;122: S209-15.
10. Kim WH, Lee TY, Kim SC, Kim SJ, Lee YT. Unbalanced atrioventricular septal defect with parachute valve. *Ann Thorac Surg*. 2000;70:1711-2.

## Jejunal Atresia in a Neonate due to Intrauterine Intussusception

SANJAY D DESHMUKH, RUPALI BAVIKAR AND \*AJAY M NAIK

From the Departments of Pathology and Pediatric Surgery, Smt Kashibai Navale Medical College, Narhe, Pune, Maharashtra, India.

Correspondence to: Dr Sanjay Deshmukh, Professor and Head, Department of Pathology, Smt. Kashibai Navale Medical College, Narhe, Pune, Maharashtra 411041, India. [drsanjay123in@yahoo.co.in](mailto:drsanjay123in@yahoo.co.in)  
Received: August 23, 2010;  
Initial review: August 31, 2010;  
Accepted: December 1, 2010.

We report a female neonate, who presented with abdominal distension and failure to pass meconium. Antenatal ultrasound at 32 weeks gestation and postnatal ultrasound on day 1 suggested intestinal obstruction. During laparotomy, atresia of distal jejunum was found. The lumen of the distal segment contained an intussusceptum. Resection of the blind ends was done and end-to-end anastomosis was performed.

**Key words:** Intrauterine, Intussusceptum, Jejunal atresia, Newborn.

Jejunal atresia is generally considered to result from intrauterine vascular disruptions in a segment of the developed intestine [1]. Volvulus, herniation and constriction have been implicated in causation of jejunal atresia [1]. Intrauterine intussusception is a rare cause of jejunal atresia [2].

### CASE REPORT

A 20 year old primigravida underwent a routine ultrasound scan at 28 weeks gestation. The scan showed dilated loops of intestine suggestive of intestinal obstruction. A follow up scan at 32 weeks gestation confirmed the findings. At term, a baby girl weighing 2.3 kg was delivered. Abdominal distension was present at birth and gastric aspirate was bile stained. Postnatal ultrasound and X-ray abdomen showed dilated fluid filled bowel loops suggestive of small intestinal obstruction.

Exploratory laparotomy revealed a proximal jejunal atresia 6 cm segment along with curved sausage like loop of intestine 2.5 cm in length i.e., intussusception of the jejunum 25 to 30 cm distal to the duodeno-jejunal junction (Type 1 atresia). The intussusceptum and atretic segment were resected and an end-to-end anastomosis

was done. The patient showed good improvement after surgery and was started on gavage feeding on day 5 which was tolerated well and postoperative period was uneventful.

Gross examination of the respected specimen did not reveal any gangrene. Microscopic examination confirmed intussusception. The proximal atretic jejunum had a blind end.

### DISCUSSION

Intussusception is rare in the neonatal period. Of about 6000 published cases in the pediatric population, only 28 occurred in the neonatal period [3]. The commonest site was the ileum. The jejunum is an uncommon location. The cause of the intussusception is unknown in majority of the cases. A case of ileal atresia consequent to intrauterine intussusception has been reported before in Indian literature [4]. Intrauterine intussusceptions causing jejunal atresia is further rare with only few cases described in the literature [2, 5].

It has been suspected that intestinal atresia may be secondary to prolonged bowel ischemia *in utero* [6], thus a