

FIG.1 Tonsil Stone.

extrusion of egg-like structures was misleading and was responsible for the delay in diagnosis. Although some worms infecting lungs during their life cycle can present with regurgitation of eggs, the helminthic eggs are too small to be seen with naked eye [5]. However, larval stages of housefly can be seen in cases of oral myiasis. But they are photophobic and often tend to hide deep into tissues for a suitable niche to develop into pupa [6].

Tonsilloliths frequently consist of carbonates and phosphates of calcium and magnesium [1]. The exact pathogenesis is not known, but is believed to be associated with chronic or recurrent oral infections [3,4]. Fibrosis near the openings of the tonsillar crypts due to repeated inflammation may result in accumulation of bacterial and epithelial debris and formation of retention cysts which can subsequently calcify [2]. Unlike most reported cases,

there were no features suggestive of tonsillitis in our case. This condition may be diagnosed by simple inspection of both tonsillar crypts and can be confirmed by a panoramic radiograph or computed tomography without contrast [1, 2]. Most tonsilloliths are small and asymptomatic and require no treatment [2]. Small, symptomatic tonsilloliths can be removed manually under local anesthesia, while large, symptomatic tonsilloliths associated with pain, swelling and dysphagia should be removed surgically [1].

#### REFERENCE

1. Mesolella M, Cimmino M, Di MM, Criscuoli G, Albanese L, Galli V. Tonsillolith. Case report and review of the literature. *Acta Otorhinolaryngol Ital.* 2004;24:302-7.
2. de Moura MD, Madureira DF, Noman-Ferreira LC, Abdo EN, de Aguiar EG, Freire AR. Tonsillolith: a report of three clinical cases. *Med Oral Patol Oral Cir Bucal.* 2007;12:E130-3.
3. Thakur JS, Minhas RS, Thakur A, Sharma DR, Mohindroo NK. Giant tonsillolith causing odynophagia in a child: a rare case report. *Cases J.* 2008;1:50.
4. Pruet CW, Duplan DA. Tonsil concretions and tonsilloliths. *Otolaryngol Clin North Am.* 1987;20:305-9.
5. Singh TS, Sugiyama H, Umehara A, Hiese S, Khalo K. *Paragonimus heterotremus* infection in Nagaland: A new focus of Paragonimiasis in India. *Indian J Med Microbiol.* 2009;27:123-7.
6. Sharma J, Mamatha GP, Acharya R. Primary oral myiasis: a case report. *Med Oral Patol Oral Cir Bucal.* 2008;13:E714-6.

## Corrosive Tracheo-esophageal Fistula Following Button Battery Ingestion

MM HARJAI, WVBS RAMALINGAM, #G CHITKARA AND #A KATIYAR

From the Department of Surgery and Paediatric Surgery, Command Hospital (Southern Command) Pune 411 040, Maharashtra; and Department of Otorhinolaryngology, and #Department of Surgery, Army Hospital (Research & Referral), Delhi Cantt, New Delhi 110 010, India.

#### Correspondence to:

Colonel Man Mohan Harjai, Professor, Senior Advisor Surgery and Paediatric Surgery, Command Hospital, (Southern Command), Pune 411 040, Maharashtra, India.  
harjai101@hotmail.com

Received: October 03, 2010;

Initial review: October 07, 2010;

Accepted: October 28, 2010.

We describe a case of corrosive tracheo-esophageal fistula following button battery ingestion in a 1-year old nonverbal pediatric patient. The delay in diagnosis was caused by failure to obtain correct history and failure to detect opacity of the battery in the neck at the first visit. The large fistula was successfully treated with division and repair with non absorbable sutures, with interposition of strap muscles between separated trachea and esophagus.

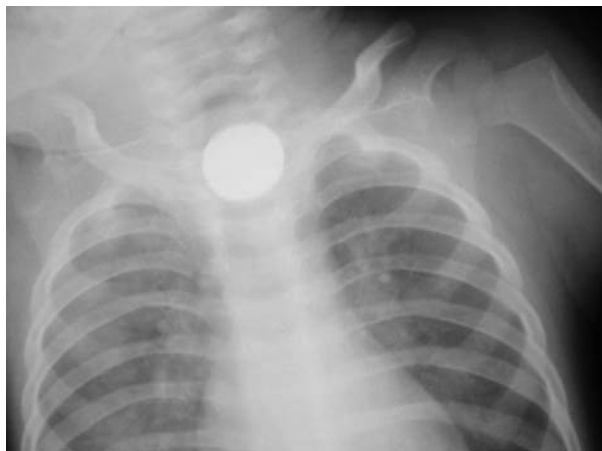
**Key words:** Button battery, Corrosive ingestion, Ingestion, Tracheo-esophageal fistula.

**T**racheo-esophageal fistula following a foreign body impaction in the esophagus is a rare and serious complication. We report consequences of an unrecognized button battery impaction in

the esophagus, which resulted in tracheo-esophageal fistula formation and was not diagnosed for more than 18 days due to masquerading of button battery shadow by haziness of associated pneumonia.

## CASE REPORT

One year old child was taken to a private practitioner by the parents for sudden onset of hoarseness of voice. He was treated as a case of acute laryngitis. When symptoms of high grade fever, cough, change in voice and drooling persisted for 10 days, baby was brought to the emergency room of a peripheral hospital. The chest radiograph revealed hazy opacities all over both lung fields with unclear cervical region. A diagnosis of acute laryngotracheobronchitis was made and patient treated accordingly. However, patient was not maintaining saturation and developed cyanosis. He was placed on ventilatory support along with broad spectrum antibiotics and other supportive measures. Patient showed signs of improvement after 48 hours and was extubated after 72 hours. Even after extubation patient did not show expected improvement. He had persistent excessive drooling of saliva with increased cough on swallowing and had episodes of desaturation. On 18<sup>th</sup> day of illness a fresh chest skiagram showed a hitherto unnoticed round opacity in the neck region (**Fig. 1**). A possibility of foreign body impacted in the esophagus was considered. Review of old skiagram of chest, the same opacity was now be discerned. The foreign body was extracted with the help of a rigid esophagoscope. It was a button battery of 1.5 cm diameter from a toy electronic harmonium. The symptoms persistently increased even after removal of button battery. Patient was transferred to our centre with a provisional diagnosis of esophageal stricture. Contrast study revealed spill of dye in the lung fields. A diagnosis of acquired tracheo-esophageal fistula secondary to button battery impaction was made. A upper gastrointestinal endoscopy revealed a large wide fistula at the level of thoracic one vertebrae. The endotracheal tube was clearly visible from the esophageal side. In view of wide fistula in a



**FIG. 1** Skiagram chest showing appreciable button battery shadow in the neck region on 18<sup>th</sup> post-ingestion day.

symptomatic child, decision of primary closure of the fistula was taken. The fistula was divided and repaired with non absorbable sutures with interposition of strap muscles between separated trachea and esophagus. He was kept on elective ventilation for 48 hours. Post operative period was uneventful.

## DISCUSSION

In our patient, a wide tracheo-esophageal fistula developed due to the presence of impacted foreign body for 20 days. In this child, button battery must have lodged or impacted for tissue damage to occur. The esophagus is especially susceptible to foreign body retention due to its several anatomic areas of narrowing and weak peristalsis [1,2]. The tissue damage that result from contact with charged battery is a chemical burn caused by production of sodium hydroxide (cathode) and hydrochloric acid (anode) generated from electric current passing through physiologic electrolyte solution [3]. Failure to recognize or appropriately manage a foreign body in the oesophagus may lead to complications and occasional mortality. Management approaches include endoscopic or open surgical repair. Unfortunately, these procedures can be complicated by high rates of recurrent laryngeal nerve injury, tracheal stenosis, recurrent fistula and significant patient mortality. These fistulae can be managed conservatively by use of esophageal rest to permit closure by secondary intention [4]. However, we did a primary repair of tracheo-esophageal fistula with interposition of strap muscles of neck as we found on upper gastrointestinal endoscopy that the margins of fistula were healthy and the fistula was very wide, which was unlikely to close spontaneously.

*Contributors:* All contributors have participated sufficiently in the intellectual content, conception and design of this work, as well as the writing of the manuscript, to take public responsibility for it and have agreed to have their name listed as a contributors. *Funding:* None; *Competing interests:* None stated.

## REFERENCES

1. Hamilton JM, Schraff SA, Notrica DM. Severe injuries from coin cell battery ingestions: 2 case reports. *J Pediatr Surg.* 2009;44:644-7.
2. Bernstein JM, Burrows SA, Saunders MW. Lodged oesophageal button battery masquerading as a coin: an unusual cause of bilateral vocal cord paralysis. *Emerg Med J.* 2007;24:e15.
3. Sigalet D, Lees G. Tracheoesophageal injury secondary to disc battery ingestion. *J Pediatr Surg.* 1988;23:996-8.
4. Grisel JJ, Richter GT, Casper KA, Thompson DM. Acquired tracheoesophageal fistula following disc-battery ingestion: can we watch and wait? *Int J Pediatr Otorhinolaryngol.* 2008;72:699-706.