

## Systemic Melioidosis

There are certain comments regarding a recent article regarding Melioidosis [1]. *Burkholderia Pseudomallei* has been described as a Vietnamese time bomb and is considered as a potential biological weapon. Despite disputes regarding the etiology of Plague in Maharashtra and Gujarat in 1994, the likely etiology was *B. pseudomallei* [2]. We have reported around 20 cases in a span of 4 years. Most of the published data on Melioidosis comes from the coastal areas mainly Kerala, Karnataka, Maharashtra and Pondicherry [3-5] and most of the patients were diabetics. The infection is usually seen during the melioidosis, prophylactic ceftazidime is advisable for the treatment as the infection may lead to septicemia and may have bad prognosis. In the laboratory, bipolar, gram negative bacilli should arouse the suspicion of *B. Pseudomallei*. Wrinkled, pinkish colonies on McConkey's agar which are oxidase positive should be tested for gentamicin, and polymyxin B, as the bacilli is resistant to both.

Edwin Dias and Meena Dias,\*  
Departments of Pediatrics and Microbiology,\*  
KVG Institute of Medical Sciences,  
Sullia;  
and \*Father Muller's Medical College,  
Mangalore;  
Karnataka, India.  
dredwindias@gmail.com

### REFERENCES

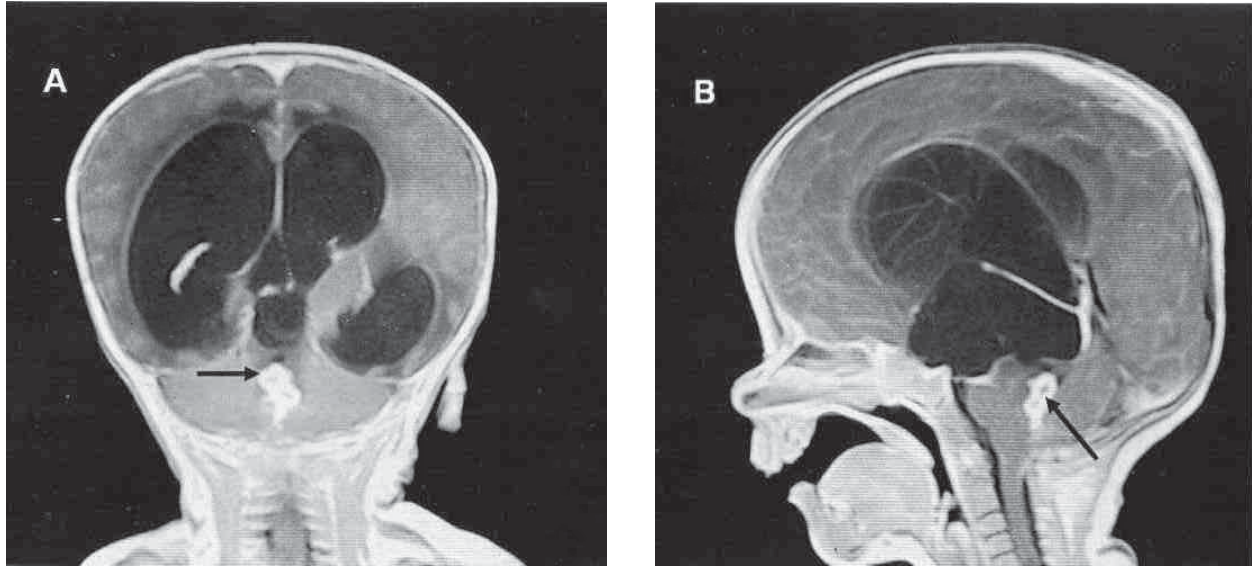
1. Shivabalan SO, Reddy N, Tiru V, Thomas K. Systematic melioidosis presenting as suppurative parotitis. Indian Pediatr. 2010;47:799-801.
2. Bharadwaj R, Kagal A, Deshpandey SK. Outbreak of plague like illness caused by *Pseudomonas Pseudomallei* in Maharashtra, India. Lancet. 1994;344:1574.
3. Kanungo R, Padhan P, Bhattacharya S, Srimannarayan J, Jayanthi S, Swaminathan RP. Melioidosis: A report from Pondicherry, South India. J Assoc Physicians India. 2002;50:1438-9.
4. Vidyalakshmi K, Shrikala B, Bharathi B, Suchitra U. Melioidosis: An under diagnosed entity in Western coastal India; A clinico microbiological analysis. Indian J Med Microbiol. 2007;25:245-8.
5. Antony B, Pinto H, Dias M, Shetty AK, Scaria B, Kuruvilla T, et al. Spectrum of melioidosis in the suburbs of Mangalore, S West coast of India. Southeast Asian J Trop Med Public Health. 2010;41:1-6.

## Fourth Ventricle Tuberculoma

Neurotuberculosis presenting as space occupying lesion (tuberculoma) within the brain parenchyma is commonly encountered in developing countries [1]. Tuberculomas occur due to hematogenous spread and are generally intra-parenchymal in location with extra-axial and intra-ventricular locations being rare [1-4]. We present a rare case of fourth ventricular tuberculoma.

A four-and-half year old female child presented in a semiconscious condition with a history of

progressive severe headache, vomiting and double vision for one week and low grade fever for two months. There was no past history of tuberculosis. Fundus examination revealed papilledema; rest of the neurological examination was unremarkable. Chest X-ray was normal. MRI showed conglomerate ring enhancing lesions in the fourth ventricle with moderate hydrocephalus (**Fig. 1**) and leptomeningeal enhancement in the left temporal region. Surgical shunting of CSF was done by placing ventriculo-peritoneal shunt. CSF examination of the patient demonstrated elevated protein levels (310 mg/dL) and low sugar (38 mg/dL) with 90% lymphocytes. CSF culture yielded growth of Mycobacterium. Child was started on



**FIG.1** Contrast enhanced MRI images, (a) coronal and (b) sagittal, showing conglomerate ring lesions (arrow) in the fourth ventricle causing hydrocephalus.

antituberculous treatment. The patient was symptom free after three months and treatment was continued for nine months.

Common locations of intracranial tuberculoma are cerebral and cerebellar hemispheres. Other less preferred locations being quadrigeminal cistern, cerebellopontine angle and suprasellar region [1]. Extra-axial tuberculomas are rare and intraventricular lesions are even less often seen [1-4]. This phenomenon is likely due to ventricles being more immune towards various infections. The most likely route of ventricular infections is through choroids plexus by hematogenous spread [1]. In tuberculosis choroid plexus gets inflamed with formation of tubercles, which may enlarge and form intraventricular tuberculoma. Tuberculoma formation in areas devoid of choroid plexus may be due to formation of subependymal tubercles.

**Amar Mukund and Shivanand Gamanagatti**

*Department of Radiology,  
All India Institute of Medical Sciences,  
New Delhi,  
India 110 029.  
dramarmukund@gmail.com*

#### REFERENCES

1. Desai K, Nadkarni T, Bhatjiwale M, Goel A. Intraventricular tuberculoma. *Neurol Med Chir (Tokyo)*. 2002;42:501-3.
2. Sonmez G, Ozturk E, Mutlu H, Sildiroglu O, Haholu A, Kutlu A, *et al*. An unusual intraventricular lesion: tuberculoma. *J Neuroradiol*. 2008;35:63-4.
3. Khanna PC, Godinho S, Patkar DP, Pungavkar SA, Lawande MA. MR spectroscopy-aided differentiation: "giant" extra-axial tuberculoma masquerading as meningioma. *Am J Neuroradiol*. 2006;27:1438-40.
4. Vajramani GV, Devi BI, Hegde T, Santosh V, Khanna N, Vasudev MK. Intraventricular tuberculous abscess: a case report. *Neurol India*. 1999;47:327-9.