

## **Case Reports**

### **Ponto-Bulbar Palsy with Deafness (Violetto-Van Laere Syndrome)**

**Vinod Puri  
A. Rohtagi  
P.S. Parihar**

The syndrome described by Brown(1) Violetto(2) and Van Laere(3) is a rare, often familial, characterized by bilateral nerve deafness followed or accompanied by involvement of various motor cranial nerves, e.g., 7th and 9th to 12th, rarely 3rd, 5th and 6th. On rare occasions, there may also be involvement of spinal motor nerves and less commonly of upper motor neurons. The onset of the disease is usually in childhood and the course irregularly progressive. There is paucity of reports of this entity in the World literature. Although Fazio-londe disease has been reported(4), there is yet no report of this rare entity from India to the best of our knowledge. We report a case of Violetto-Van Laere Syndrome.

---

*From the Department of Neurology G.B. Pant Hospital, New Delhi 110 002.*

*Reprint requests: Dr. Vinod Puri, Professor of Neurology, G.B. Pant Hospital, New Delhi 110 002.*

*Received for publication: June 17, 1994;*

*Accepted: February 15, 1995*

---

### **Case Report**

This eleven years old boy, the fifth of seven children of healthy unrelated parents was born after an uneventful pregnancy. The birth history was normal as were developmental milestones. His one elder brother and four sisters (3 elder and 1 younger) suffered from illness similar to his and all died due to chest infection within six months to 4 years of the onset. As per the historical clues, all had hearing impairment, difficulty in swallowing, drooling of saliva and inability to close eyes during sleep. His only alive, 2 years old sister was healthy and normal on examination. He had been immunized against poliomyelitis, diphtheria, whooping cough and tetanus.

His illness began at 4 years of age with noisy breathing and the child would keep the eyes open while asleep. He would not respond to normal pitch spoken words. One year later, he deteriorated and required emergent intubation and admission in an intensive care unit. Tracheostomy was performed because of his continued need for mechanical ventilation. At this time, he had bilateral ptosis and facial diplegia. Five years after the onset, he developed difficulty in swallowing, drooling of saliva and nasal regurgitation. His hearing had further diminished. The neurological examination confirmed the existence of bilateral ptosis, facial diplegia and bilateral sensorineural impairment (45 decibel loss). Fundoscopy was normal and there was no ophthalmoplegia. The masseter on both sides were weak and

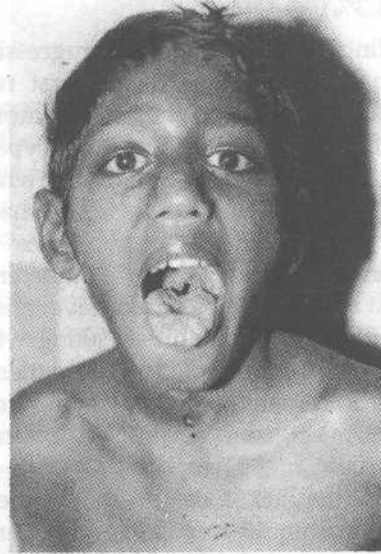
## CASE REPORTS

wasted. The tongue was wasted (*Fig. 1*) and weak with fasciculations. The palatal movements were poor. The limbs had power grade 4/5 with hyper-reflexia and upgoing plantars. No abnormality of sensations could be detected. Routine hematological and biochemical investigations were normal. The plasma creatine kinase(CK) level was normal as was cerebrospinal fluid examination. MRI cranium was normal. The motor and sensory conduction velocities in the limbs were normal. Needle electromyogram of quadriceps, deltoid, brachioradialis, tibialis anterior were normal, while orbicularis oris showed the presence of fibrillations with polyphasic potentials. Some of the potentials reached upto 280  $\mu$ v but most were below 150  $\mu$ v. The EMG findings were interpreted as showing evidence of neurogenic process.

### Discussion

The chronic progressive bulbar palsy in the present case alongwith bilateral pyramidal signs could be due to Fazio-londe disease, Madras pattern of motor neurone disease or Vialletto-Van Laere syndrome.

Fazio-londe disease has an onset between 2 and 14 years of age and usually follows a sub acute course with survival up to 2 years after onset. Only the rare cases with chronic course develop amyotrophy and hyperreflexia in the limbs(5). Deafness is never seen with Fazio-londe disease but is a definite feature of Vialletto-Van Laere syndrome(6) and may occur in up to 45% of cases with Madras pattern of motor neurone disease(7). Both of these disorders have their onset in adolescence and follow a slowly progressive course. In about 1/3rd cases of Vialletto-Van Laere syndrome, deafness may precede by several years, while in the remaining 2/3rd it either accompanies or follows the development of bulbar palsy(8).



*Fig. 1. Photograph showing atrophy of tongue.*

The present case had deafness and onset at 4 years of age. His brother and sisters also had deafness along with an early onset of the disease.

Vialletto-Van Laere syndrome is mostly familial with autosomal recessive inheritance or may be sporadic(6). However, all reported cases of Madras pattern of motor neurone disease were non-familial(7,9). The pedigree of the present case was suggestive of autosomal recessive inheritance with fatal

Harding(10) classified the progressive bulbar palsy presenting in the first two decades of life as bulbar hereditary motor neuropathy Type I and Type II; Type I being Vialletto-Van Laere syndrome, while Type II as Fazio-Londe disease. Mcshane *et al.*(11) described three sub-types of Fazio-Londe disease; rare autosomal dominant and two types of recessive inheritance with early or late onset along with respiratory symptomatology outcome in 5 of 6 affected cases (83.3%).

The patients with less prominent respiratory symptoms had late onset and protracted course. Rosemberg *et al.* (12) reported a case of progressive bulbar palsy with deafness who died within 13 months of onset and had on necropsy degeneration of motor cranial nerve nuclei of 12th, 11th, 9th and 7th nerves along with anterior horn cells of cervical and upper dorsal spinal cord. They considered their case as a bridge between Fazio-Londe and Vialette-Van Laere syndrome.

The present case as well his pedigree had several common features between Fazio-Londe disease, *i.e.*, early onset, subacute progression, respiratory symptoms, fatal outcome in 5 of 6 affected cases and deafness of Vialette-Van Laere syndrome.

The overlap between these two syndromes perhaps may be of genetic consequence and needs be probed.

#### REFERENCES

1. Brown CH. Infantile amyotrophic lateral sclerosis of the familial type. *J Nerv Ment Dis* 1894, 21: 707-716.
2. Van Laere JE. Un Nouveau cas de paralysie bulbopontine chronique progressive avec surdite. *Revue Neurol* 1977, 113: 119-124.
3. Vialette E. Contributo alla forma ereditaria della paralisi bulbare progressiva. *Riv Sper Freniat* 1936, 40: 1-24.
4. Reddy MV, Murthy JMK. Progressive bulbar paralysis of childhood (Fazio-Londe disease). *Indian Pediatr* 1982, 19: 805-806.
5. Bunday S. Paralysis, progressive bulbar of childhood (Fazio-Londe disease). *In: Handbook of Clinical Neurology*, Vol. 42. Eds. Vinken PJ, Bruyn GW. Amsterdam, North Holland Publishing Company 1981, pp 94-95.
6. Aird RB. Paralysis, bulbo-pontine with deafness. *In: Hand-Book of Clinical Neurology*. Eds. Vinken PJ, Bruyn GW. Amsterdam, North Holland Publishing Company, 1981, pp 95-96.
7. Meenakshisundaram E, Jagannathan K, Ramamurthi B. Clinical pattern of motor neuron disease seen in younger age groups in Madras. *Neurol India* 1970, 18: 109-112.
8. Gallai V, Hockaday JM, Hughes JT, Lane DJ, Oppenheimer DR, Rushworth G. Ponto bulbar palsy with deafness (Brown-Vialette-Van Laere Syndrome) *J Neurol Science* 1981, 50: 259-275.
9. Sayeed ZA, Velmurugendran U, Arjundas G, Masareen M, Valmiki-nathan K. Anterior horn cell disease seen in South India. *J Neurol Science* 1975, 26: 489-498.
10. Harding AE. Inherited neuronal atrophy and degeneration predominantly of lower motor neurons. *In: Peripheral Neuropathy*, 2nd edn. Eds. Dyck PJ, Thomas PK, Lambert EH, Bunge R. Philadelphia, W.B. Saunders 1984, pp 1537-1556.
11. Mcshane MA, Boyd S, Harding B, Brett EM, Wilson J. Progressive bulbar paralysis of childhood. *Brain* 1992, 115: 1889-1900.
12. Rosemberg S, Lancellotti CLP, Arita F Campos C, Castro NDP. Progressive bulbar paralysis of childhood (Fazio-Londe disease) with deafness. *Eur Neurol* 1982, 21: 84-89.