

containing fats and oils, vitamin supplementation and percutaneous application of minute amounts of sunflower oil to prevent essential fatty acid deficiency(8). Bone marrow transplantation, the use of lovastatin, and infusion of the missing enzyme are experimental therapies(9).

#### REFERENCES

1. Sundaravalli N, Raju BB, Prema A, Pushpa V. Wolman's disease. *Indian Pediatr* 1986, 23: 950-953.
2. Rosowsky A, Crocker AC, Trites DH, Modest EJ. Gas liquid chromatographic analysis of tissue sterol fraction in Wolman's disease. *Biochem Biophys Acta* 1965, 98: 617-620.
3. Sloviter HA, Janic V, Nalman JL. Lipid synthesis by RBC preparation in Wolman's disease (Familial lipidosis). *J Clin Chem Acta* 1968, 20: 423-426.
4. Kikuchi M, Igarashi K, Noro T, Igarashi Y, *et al.* Evaluation of Jejunal function in Wolman's disease. *J Pediatr Gastroenterol Nutr* 1991, 12: 65-69.
5. Wolman M, Sherk W, Datt S, Frenke M. Primary familial xanthomatosis with involvement and calcification of the adrenals: Report of 2 more siblings of described case. *Pediatrics* 1961, 28: 742-746.
6. Harnison RB, Francke P Jr. Radiologic findings in Wolman's disease. *Radiology* 1977, 19: 57-66.
7. Bona G, Gallina MR, Dolfi G, *et al.* Prenatal diagnosis of heterozygosis in pregnancy at risk for Wolman's disease at the eight week of gestation. *Panminerva Med* 1989, 31: 180-182.
8. Wolman M. Proposed treatment for infants with Wolman's disease. *Pediatrics* 1989, 83:1074-1075.
9. Krivit W, Freeze D, Chan KW, Kulkarni F. Wolman's disease: A review of treatment with bone marrow transplantation and consideration for the future. *Bone Marrow Transplant* 1992, 10(Suppl 1): 97-103.

## Tuberous Sclerosis with a Brain Tumor

Deepika Chaudhary  
Ashok Kumar  
Arvind Srivastava

Tuberous sclerosis or Bourneville disease is a neurocutaneous disorder characterized by the triad of seizures, mental retardation, and adenoma sebaceum. Intracranial lesions of tuberous sclerosis consist of calcified

subependymal glial nodules and tubers-occupying a cortical /subcortical location. Malignant transformation of the intracranial lesions of tuberous sclerosis occurs rarely(1). In a recent publication, none of the seven patients with this con-

---

*From the Departments of Radiology and Pediatrics, Institute of Medical Sciences, Banaras Hindu University, Varanasi 221 005.*

*Reprint requests: Dr. Ashok Kumar, B 31/83 R, Bhogabir, Lanka, Varanasi 221 005.*

*Received for publication: July 12, 1994;*

*Accepted: November 4, 1994*

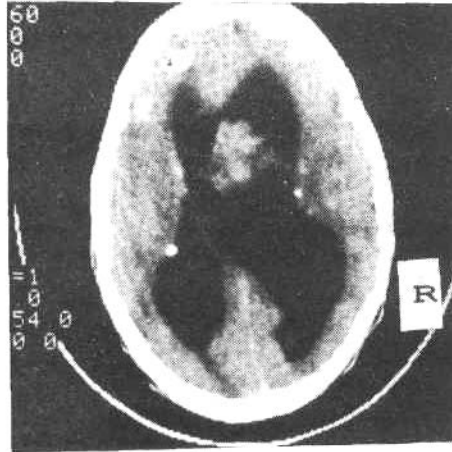
dition had a brain tumor(2). The rare occurrence of brain tumor in tuberous sclerosis prompted us to report this case.

### Case Report

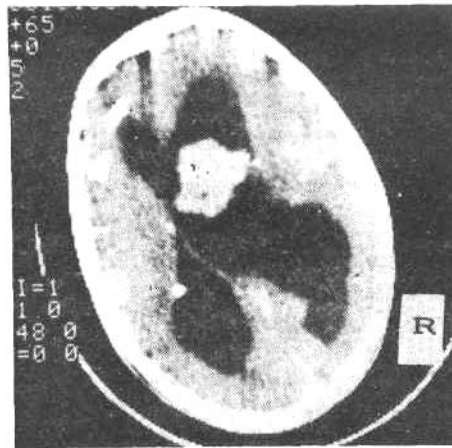
A fourteen-year-old male presented with history of generalized tonic-clonic seizures and mental retardation since early childhood, and poor vision, headache, and vomiting of 2 months' duration. Seizures appeared when he was 2 years old and persisted despite various antiepileptic drugs. Skin lesions in the form of brownish papules were noted over the cheeks at the age of 6 years. There was history of delayed acquisition of developmental milestones and poor scholastic performance. The family history was unremarkable.

On examination, the child was mentally retarded (IQ, 56). Adenoma sebaceum were noted over the malar areas of the face. The Macewen sign was positive and fundi revealed papilledema. There were no other stigmata of the disease and no localizing neurological signs were detected. Skull X-ray showed separation of sutures, increased convolitional markings, and widely scattered intracranial calcification. Cranial CT (unenhanced) showed dilatation of both the lateral ventricles, multiple calcined nodules in the periventricular and cortical regions of the brain, and a large heterogeneous mass of increased attenuation in the region of the foramen of Monro (*Fig. 1*). The third and fourth ventricles were normal. Contrast CT revealed enhancement of the tumor and no change in the density of subependymal and cortical nodules (*Fig. 2*). Subtotal resection of the tumor was done

through frontal craniotomy. The tumor arose from the floor of the right lateral ventricle and extended through the foramen of Monro into the left lateral ventricle. The biopsy of the lesion revealed giant cell astrocytoma. Post-



*Fig. 1. Plain CT scan showing dilatation of both lateral ventricles, calcified periventricular and cortical nodules, and a tumor mass in the region of the foramen of Monro.*



*Fig. 2. Contrast CT scan showing enhancement of tumor mass. Periventricular and cortical nodules did not show any change in density.*

peratively, the features of raised intracranial tension were controlled, but he continued to have seizures despite the combined use of sodium valproate and carbamazepine.

### Discussion

Tuberous sclerosis is an autosomal dominant condition with variable expression. About 50% of the cases appear to be new mutations. Seizures and mental retardation are early but nonspecific manifestations of the disease. The skin lesions of tuberous sclerosis include facial angiofibroma (adenoma sebaceum), forehead/scalp fibrous plaques, peri/subungual fibromas, hypomelanotic macules, and shagreen patches(3). The first three are considered pathognomonic of tuberous sclerosis. The term adenoma sebaceum is a misnomer, and the preferred term is facial angiofibroma. These facial lesions are not adenomas of sebaceous glands, but rather fibrous hamartomas of the dermis. The diagnostic importance of adenoma sebaceum is limited because they are not found in all the patients and by their late appearance.

Seizures are the most frequent clinical sign of tuberous sclerosis, and occur in all who are mentally retarded. Infantile spasms are frequent during infancy; generalized and focal seizures predominate later(4). Mental retardation is found in 60-70% of patients in this condition.

Early diagnosis of tuberous sclerosis is important for genetic counselling of the family. CT scan is suggestive of diagnosis even in the absence of cutaneous stigmata. The characteristic finding is of multiple, small calcified foci in

relation to the walls of lateral ventricles and frequently protruding into them(5). CT scan is much more sensitive than plain radiography in detecting the calcified lesions. Only about half of the lesions shown by CT are visible on the skull films, particularly in the first few years of life(6).

Histopathologically, the condition is characterized by hamartomas involving numerous organs including brain, skin, eyes, heart, kidneys, bone, and lungs(3,7-9). The cerebral hamartomas are present in every case of tuberous sclerosis and are composed of abnormal neurons and glial cells and occur throughout the cortical grey matter and in subependymal regions adjacent to the ventricles.

In 10% of cases of tuberous sclerosis, brain hamartomas undergo malignant transformation(1,10). Those hamartomas situated near the foramen of Monro are most liable to such a change. These tumors are benign giant cell astrocytomas and grow slowly. On CT, they appear slightly hyperdense, and enhance intensely with intravenous contrast(11). In comparison to this, the hamartomas do not show contrast enhancement(12,13). Therefore, any change in the density of subependymal lesions following contrast injection should arouse suspicion of malignant transformation.

### REFERENCES

1. Kapp JP, Paulson GW, Odom GL. Brain tumors with tuberous sclerosis. *J Neurosurg* 1967, 26:191-202.
2. Gulati P, Jena A, Sanchette PC, Tripathi RP, Chandra. Demonstration of brain lesions in tuberous sclerosis by magnetic resonance imaging. *Indian Pediatr* 1993, 30: 533-536.

## BRIEF REPORTS

3. Bell DG, King BF, Hattery RR, Charboneau JW, Hoffman AD, Houser OW. Imaging characteristics of tuberous sclerosis. *Am J Roentgenol* 1991,156:1081-1086.
4. Berg BO. Neurocutaneous syndromes: phakomatosis and allied conditions. *In: Pediatric Neurology: Principles and Practice*. Ed. Swaiman KF. St Louis, CV Mosby, 1989, pp 800-801.
5. Rao KCVG, Harwood-Nash DC. Cranio-cerebral anomalies. *In: Cranial Computed Tomography and MRI*, 2nd edn. Eds. Lee SH, Rao KCVG. New York, McGraw-Hill, 1987, pp 219-221.
6. Sutton D, Moseley IF. Computed tomography—CNS. *In: A Textbook of Radiology and Imaging*, 4th edn. Ed. Sutton D. Edinburgh, Churchill Livingstone, 1987, pp 1611-1612.
7. Lagos JC, Holman CB, Gomez MR. Tuberous sclerosis: neuro-radiologic observations. *Am J Roentgenol* 1968,104: 171-176.
8. Dewan M, Agarwal S. Tuberous sclerosis: A case report. *Indian J Pathol Microbiol* 1988, 31: 89-91.
9. Rawade SR, Amanpure PA, Raichur DV, Patil PG. Cystic kidneys in tuberous sclerosis. *Indian Pediatr* 1993, 30: 921-924.
10. Fitz CR, Harwood-Nash DC, Thompson JR. Neuroradiology of tuberous sclerosis in children. *Radiology* 1974, 110: 635-642.
11. Hershey BL, Zimmerman RA. Pediatric brain computed tomography. *Pediatr Clin North Am* 1985, 32: 1477-1508.
12. Lee BCP, Gawler J. Tuberous sclerosis: comparison of computed tomography and conventional neuroradiology. *Radiology* 1978,127: 403-407.
13. Gardens D, Palmieri A, Mashaly R. Cranial computed tomography in the phakomatosis. *Neuroradiology* 1983, 25: 293-303.

---

### Effect of Myleran Therapy in Multitransfused Thalassemic Children

**Amita Lal**  
**H.P. Pati**  
**L.S. Arya**  
**Ved P. Choudhry**

Thalassaemia syndrome is an inherited disorder affecting either alpha or beta chain synthesis(1,2). Allogenic bone marrow transplantation offers cure(3)

but is feasible in nearly 30% of cases. However, only few lucky thalassaemic children have undergone bone marrow transplantation because of its prohibitive cost. It has been observed that an

---

*From the Departments of Pediatrics and Hematology, All India Institute of Medical Sciences, New Delhi 110 029.*

*Reprint requests: Dr. V.P. Choudhry, Additional Professor, Department of Hematology, All India Institute of Medical Sciences, New Delhi 110 029.*

*Received for publication: August 9,1994;*

*Accepted: November 4,1994*