

Choledochal Cyst

Y.K. Sarin
C.S. Sharma
L.D. Agarwal
M. Zaffar
A.K. Sharma

We report an unusual case of diverticulum of the extrahepatic biliary system treated successfully with hepaticoducho-duodenostomy.

Case Report

A 2V4-year-old female child was admitted with complaints of abdominal distension and loss of weight for three months and abdominal pain for two days. Although there was history of passing acholic stools, there was no history of jaundice, fever or pruritis. There was no family history of hepato-biliary disease and the past medical history was unremarkable. On physical examination, she was a pale, malnourished, anicteric child having generalized distension of the abdomen. A huge, cystic, nontender, ill-defined

From the Department of Pediatric Surgery, S.M.S. Medical College and Attached SPMCIII, Jaipur 302 004.

Reprint requests: Dr. A.K. Sharma, B-2, Doctors Bungalow, Gangwal Park, Jaipur 302 004.

Received for publication: August 18, 1993

Accepted: October 3, 1993

mass having restricted mobility was felt in the right half of the abdomen. The liver and spleen were not palpable; there were no stigmata of chronic liver disease.

Initial investigations showed Hb of 5.0 g/dl; TLC and DLC were normal. Liver function tests and blood biochemistry were normal. Abdominal radiography showed a soft tissue shadow in the right half of the abdomen displacing the loops of bowel to the opposite side. Ultrasonography of the abdomen revealed a large choledochal cyst occupying the whole of the right abdomen and extending upto the pelvis. There was gross dilatation of the intrahepatic biliary radicals in both the lobes of liver. Liver parenchyma, however, was normal.

After initial resuscitation with blood transfusions and intravenous hyperalimentation, the child was taken up for surgery. At laparotomy, a huge diverticulum of the extrahepatic biliary system measuring 15x12x10 cm was seen. 1500 ml of thick bile could be aspirated from the same (*Fig. 1*). The dilated common hepatic duct measured 1.5 cm in diameter. The common bile duct distal to the communication of the diverticulum was atretic. Intra-operative cholangiography performed through the common hepatic duct showed the dilated intrahepatic biliary radicals. The lumen of the distal common duct was completely obliterated, no dye was going down to the duodenum (*Fig. 2*). Excision of choledochal cyst and hepaticoducho-duodenostomy was performed.

Histopathological examination of the excised cyst showed dense connective tissue with some smooth muscle. Epithelial lining was deficient in most of the areas, occasional patches of flattened epithelium were

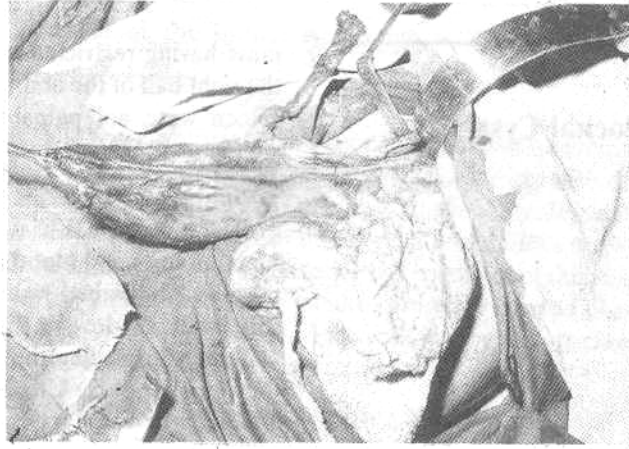


Fig. 1. Intra-operative photograph showing large diverticulum of extra-hepatic duct after an impressive amount of 1,500 ml of bile had been aspirated from it.

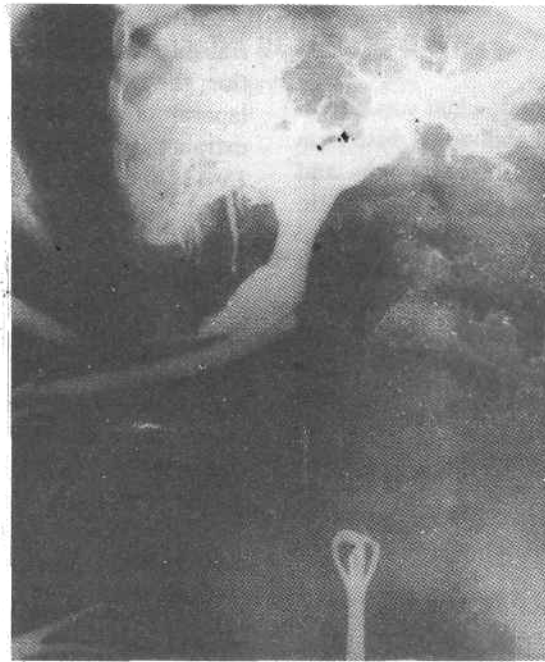

Fig. 2. Intra-operative cholangiogram showing dilated intra-hepatic biliary radicals and common hepatic bile duct. Note that no dye was going down beyond the communication of the diverticulum with the extrahepatic bile duct system.

seen. Evidence of non-specific inflammation was present throughout.

Post-operative period was uneventful. The child has been on regular follow up. Repeat ultrasonography performed a year after the surgery revealed the intrahepatic biliary radicals to be of near normal caliber.

Discussion

Diverticulum of the extrahepatic duct (choledochal cyst type II - Alonzo-Lej classification(1) is an exceeding by Tare abnormality representing only 2% of all the choledochal cysts(2). Considering the incidence of choledochal cyst in the vicinity of 1 in 2,000,000 live births in the 'non-oriental populations(3), the true incidence of the type of anomaly described above would be 1 in 100 million. Only one case of this type of anomaly has been reported previously from India(4).

The accepted theories regarding the etiology of the type II diverticular form of choledochal cyst include Hayes *et al.*'s theory of an earlier stage of bile duct over-development⁽⁵⁾ and Lilly *et al.*'s theory of end stage healing of prenatal rupture of the common duct.(6)

The present case of the second reported case of type II diverticular form of choledochal cyst from India. Other than its huge size, this case is unique in regards to the absence of jaundice inspite of the complete obstruction of the distal common bile duct. The probable explanation is that the obstruc-

tion was probably progressive and the complete obstruction (atresia of distal common bile duct) had occurred only in the recent past. The bile secreted during this period accumulated in the diverticulum and thus the child remained anicteric, although passed acholic stools as no bile reached the intestines. Exclusion of the bile salts/acids from the enterohepatic circulation resulted in malabsorption and loss of weight.

REFERENCES

1. Alonzo-Lej F, Revor WB, Pessango DJ. Congenital choledochal cyst, with a report of 2 and an analysis of 94 cases. *Surg Gynecol Obstet Internal Abst Surg* 1959, 108: 1-30.
2. Yamaguchi M. Congenital choledochal cyst. Analysis of 1433 patients in Japanese literature. *Am J Surg* 1980, 140: 653-657.
3. Howell CG, Templeton JM, Weiner S. Antenatal diagnosis and early surgery for choledochal cyst. *J Pediatr Surg* 1983,18: 387-393.
4. Modi RN, Thakar YM, Talwalker VC. Choledochal cyst. *Indian Pediatr* 1985,22: 624-628.
5. Hayes MA, Goldenberg IS, Bishop CS. The developmental basis for the bile duct anomalies. *Surg Gynecol Obstet* 1958,107: 446-456.
6. Lilly JR, Weintraub WH, Altman RP. Spontaneous perforation of the extrahepatic bile ducts and bile peritonitis in infancy. *Surgery* 1974, 75: 664-673.