

## Acknowledgement

The authors wish to express their gratitude and thank Dr. (Mrs.) P.M. Pai, Dean, K.E.M. Hospital for permission to publish this article.

## REFERENCES

1. Huttenlocker PR. Nervous system. *In*: Nelson Text Book of Pediatrics, 13th edn. Eds Behrman RE, Vaughan VC. Philadelphia, W.B. Saunders Company, 1987, pp 1303-1304.
2. Etheridge Jr JE. Birth defects and developmental disorders. *In*: Pediatric Neurology, 3rd edn. Ed Farmer TW. Philadelphia, Harper & Row Publishers, 1983, pp 68-71.
3. Osborn BI, Silverstein AM, Prendergast RA, *et al*. Experimental viral induced hydranencephaly and porencephaly caused by blue tongue vaccine virus. *Lab Invest* 1971, 25: 197-205.
4. Lyen KR, Lingam S, Butterfill AM, *et al*. Multicystic encephalomalacia due to fetal viral encephalitis. *European J Pediatr* 1981, 137: 11-16.
5. Chutorian AM, Michener RC, Defendini R, Hilal SK, Gambos ET. Neonatal polycystic encephalomalacia. Four new cases and review of the literature. *J Neuro Neurosurg Psychiatr* 1979, 42: 154-160.
6. Alford Jr CA, Griffiths PD. Rubella. *In*: Infectious Diseases of the Fetus and Newborn Infant, 2nd edn. Eds Remington JS, Klein JO. Philadelphia, W.B. Saunders Company, 1983, pp 76-80.
7. Rorke LB, Spiro AJ. Cerebral lesions in congenital rubella syndrome. *J Pediatr* 1979, 70: 243-255.

## Ataxia Telangiectasia with Acute Lymphoblastic Leukemia

S.R. Rao  
R.S. Iyer  
B. Gladstone  
S.H. Advani

Ataxia telangiectasia (AT) is an autosomal recessive syndrome characterized by ataxia, oculocutaneous telangiectasia, recurrent sinopulmonary infections and variable immune deficiencies. Individuals with AT are prone to develop lymphoreticular malignancies like leukemias and lymphomas(1). The management of patients of AT with acute lymphoblastic leukemia has not been uniform. We hereby report a case of AT who developed acute lymphoblastic leukemia (ALL) and was treated with reduced doses of chemotherapeutic drugs. He was in complete remission for 5 months but died following relapse of the disease.

### Case Report

A 6-year-old boy, born of a nonconsanguinous marriage presented to the Tata Memorial Hospital in January with history of fever for a month and failure to thrive. On examination, we saw a dull appearing boy whose height (117 cm) and weight (16 kg) were between the 5th and 25th percentile for age. Prominent bulbar telan-

---

*From the Department of Medical Oncology, Tata Memorial Hospital, Parel, Bombay 400 012.*  
*Reprint requests: Dr. S.H. Advani, Chief, Department of Medical Oncology, Tata Memorial Hospital, Parel, Bombay 400 012.*

*Received for publication: January 16, 1992;*  
*Accepted: June 18, 1992*

giectasia (Fig. 1) in both conjunctivae, *cafe au lait* spots were seen along with cervical and inguinal lymphadenopathy without any organomegaly. Neurological examination revealed marked ataxia, dysarthric speech with hypotonic muscles and diminished reflexes. Examination of the respiratory system was normal. On enquiry, parents gave a history of similar ataxic gait noticed in their 2-year-old daughter since she had started walking. On examining her, apart from ataxia she had no other relevant findings.

The patient's hemoglobin was 12.8 g/dl, total white cell count was 21,100 with 24% blasts, 45% polymorphs, 22% lymphocytes, 1% monocyte, 8% eosinophils and a platelet count of  $3.75 \times 10^9/L$ . The chest X-ray showed a mediastinal mass. Bone marrow aspiration was hypercellular with 48% blasts of L1 morphology. The blast cells were negative for Sudan black, myeloperoxidase and PAS stains. Immunophenotype revealed Ia and CD 19 (B4) positive blasts the rest of the B and T markers [ CD 10 (CALLA), CD 7 (pan T), CD 4, CD 8 (helper and suppressor T) ] being negative. A cytocentrifuge on the cerebrospinal fluid did not reveal blasts. Hence he was diagnosed to have "Null" type of ALL. Other investigations to substantiate a diagnosis of AT in both the patient and his sibling are shown in the Table. The patient's peripheral blood cytogenetics revealed breaks and gaps in 50% of the metaphases (Fig. 2) and a translocation (14; 14) (Fig. 3). He was induced with our chemotherapy protocol (Fig. 4) with a 25% reduction in doses. He completed I1 cycle smoothly and achieved complete remission. Subsequently he was started on the I 2A cycle (Fig. 4) with a 25% reduction in doses and omission of cranial radiotherapy to avoid any further neurological deteriora-

tion. He remained in remission for 5 months after which he had a recurrence of the mediastinal mass and succumbed to progressive disease.

### Discussion

Ataxia telangiectasia is a multisystem hereditary disorder with an autosomal re-

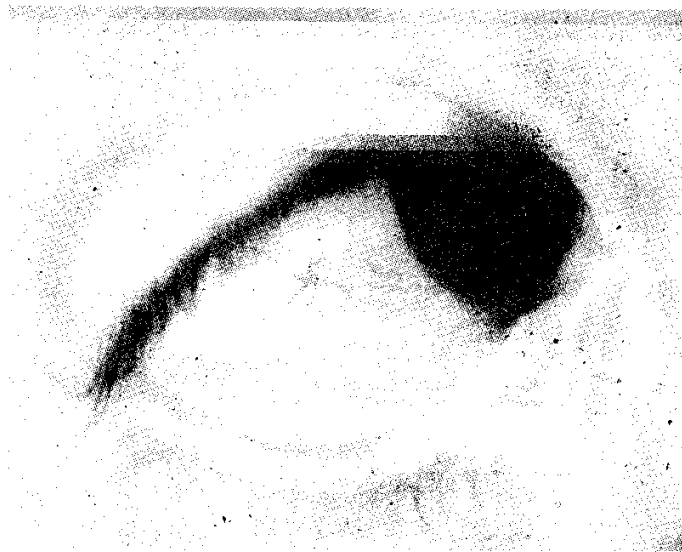

Fig. 1. Photograph showing telangiectasia.

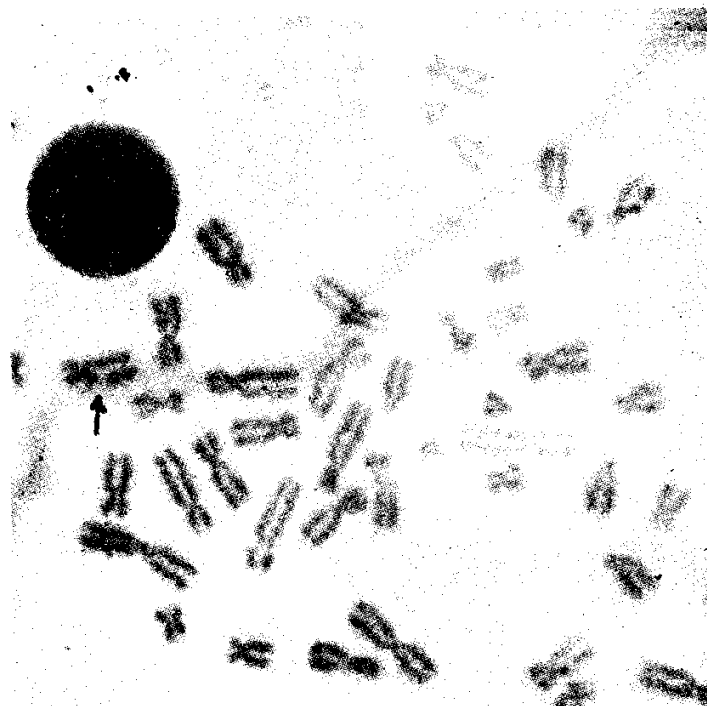


Fig. 2. A Metaphase spread showing a gap.

The incidence of hematological malignancies in patients with AT is 10% of which 75% are non-Hodgkins lymphomas of various histologic subtypes(4). The

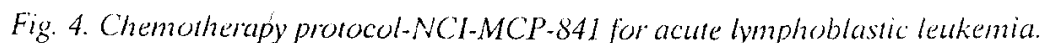
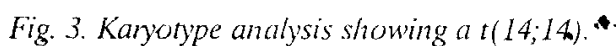


TABLE - *Summary of Investigations*

Investigations	Patient	Sibling
Blood sugar (mg/dl)	84	81
Alfa-fetoprotein & $\beta$ -human chorionic gonadotrophin	raised	raised
Mantoux test	negative	negative
Cytogenetics on peripheral blood	t(14; 14) breaks & gaps	t(14; 14) breaks & gaps
Polymorph functions	phagocytic & bactericidal index decreased	phagocytic & bactericidal index decreased
T cell function	depleted	depleted
Serum immunoglobulins	normal	normal
Mental age	4 years	not evaluable

remaining 20% comprise acute and chronic lymphocytic leukemias, adenocarcinoma of the gastrointestinal tract, basal cell carcinomas and brain tumors(1). Twenty-two cases of acute lymphoblastic leukemia have been reported in the Immunodeficiency Cancer Registry, none of them surviving longer than 36 months(2). Our patient developed ALL at the age of 6 years, while the sibling aged 2 years remains fine.

The exact reason as to why patients of AT develop malignancies is not known. The primary immunodeficiency state, chromosomal instability, defective DNA repair alone or in combination has been postulated. A fundamental genetic proclivity for recombinase error may promote translocation involving band 14q32 leading to a juxtaposition of a T cell receptor locus with a cellular proto-oncogene. Deregulation of

the cellular proto-oncogene involved in the translocation would then cause the clonal expansion of the cells carrying the translocation(5). It has been proposed that the AT gene might be associated with faulty recombinase activity and this might account for the immuno deficiency, the high spontaneous frequency of chromosomal translocation and the deficient DNA repair(6). Our patient has also shown t(14; 14).

Published data regarding the treatment of ALL in AT patients suggests a poor responses to therapy(4). This is probably due to a relatively older age at presentation(7), a high initial white cell count, T or B cell surface markers(8), and presence of a mediastinal mass on chest roentgenogram(9). Our patient seems to have all the unfavorable prognostic factors.

Taking into account the experience of past workers(3) we omitted radiotherapy which is usually a part of the central nervous system directed therapy in our protocol (*Fig. 4*), though we continued to give him intrathecal methotrexate with a 25% reduction in dosage. Neurologically patient remained stable during remission. Despite a 25% reduction in the chemotherapeutic dosage our patient did achieve complete remission and remained in remission for 5 months. However, he developed recurrence of the mediastinal mass and succumbed to progressive disease after six months of diagnosis.

More information is required regarding dosage of chemotherapeutic agents so as to prolong remission in these patients.

#### REFERENCES

1. Waldmann TA, Misiti J, Nelson DL, Kraemer KH. Ataxia telangiectasia—A multisystem hereditary disease with immuno deficiency, Impaired organ maturation, X-ray hypersensitivity and a high incidence of neoplasia. *Ann Int Med* 1983, 99: 367-379.
2. Toledano SR, Lange BJ. Ataxia telangiectasia and acute lymphoblastic leukemia. *Cancer* 1980, 45: 1675-1678.
3. Eyre JA, Gardner-Medwin D, Summerfield GP. Leukoencephalopathy after prophylactic radiation for leukemia in ataxia telangiectasia. *Arch Dis Child* 1988, 63: 1079-1093.
4. Kersey JH, Spector BD, Good RA. Primary immunodeficiency diseases and cancer: The Immunodeficiency Cancer Registry. *Int J Cancer* 1973, 12: 333-347.
5. Russo G, Isobe M, Pegoraro L, Finan J, Nowell PC, Croce Cm. Molecular analysis of a t(7; 14) (q35;q32)—Chromosome translocation in a T cell leukemia of a patient with ataxia telangiectasia. *Cell* 1988, 53: 137-144.

6. Bridges BA, Harnden DG. Untangling ataxia telangiectasia. *Nature* 1981, 289: 222-223.
7. Simone JV, Verzosa MS, Rudy JA. Initial features and prognosis in 363 children with acute lymphocytic leukemia. *Cancer* 1975, 36: 2099-2108.
8. Chessels JM, Hardisty RM, Rapson NT. Acute lymphoblastic leukemia in children. Classification and prognosis. *Lancet* 1977, 2: 1307-1309.
9. Dow LW, Borella L, Sen L, *et al.* Initial prognostic factors and lymphoblast erythrocyte rosette formation in 109 children with acute lymphoblastic leukemia. *Blood* 1977, 50: 671-682.

---

### Acephalus Acardia Syndrome

**J.B. Sharma**  
**N. Gulati**  
**S. Malik**

Acephalus acardia syndrome is characterized by absence of head and heart with abnormality of limbs. The condition is extremely rare and is estimated to occur once in 40,000 deliveries(1). It is exclusively seen in monozygotic twin pregnancies where one fetus develops normally while the other becomes an amorphous mass with its blood supply coming from the normal fetus through anastomosis in

---

*From the Department of Obstetrics and Gynecology, Medical College and Hospital, Rohtak.*  
*Reprint requests: Dr. J.B. Sharma, c/o Dr. S.L. Sharma, 20 Jagdish Marg, Patiala 147 001.*  
*Received for publication: November 19, 1990;*  
*Accepted: June 30, 1992*