

### Achondrogenesis Type II (Langer-Saldino)

T. Reddeppa  
H.V. Kishor  
V.P. Singhal  
D.S. Divekar

Achondrogenesis is a form of lethal neonatal dwarfism originally described by Parenti in 1936, under the term 'anosteogenesis' and considered it, a form of osteogenesis imperfecta(1). The present designation 'achondrogenesia' was coined by Fraccaro in 1952(2). It is a group of autosomal recessive chondrodystrophies characterized by disproportionately large cranium, short trunk, extreme micromelia, short ribs and deficient ossification of spine and pubic bones. The two main types of achondrogenesis, most often clinically indistinguishable but, radiologically and histologically two distinct entities, described are Type I (Parenti-Fraccaro) and Type II (Langer-Saldino). The reported incidence is 0.23 per 10,000 births(3) and

120 cases were reported in literature up to 1990(4). The present communication describes a case of Langer-Saldino variety of achondrogenesis, because of its rarity.

#### Case Report

A full term female neonate, product of non-consanguineous marriage, was born to a booked primi gravida by emergency cesarean section. The father and mother were aged 27 and 22 years, respectively. The baby had severe birth asphyxia (APGAR 2/10), which remained unchanged despite adequate cardiopulmonary resuscitative measures. The neonate died within 33 min after birth.

The child weighed 900 g and measured 29 cm in length. The following dysmorphic features were noted in the new-born: a large head almost resting on a short neck, bulging eyes, protruding tongue, short and square trunk, distended abdomen (fetal hydrops), and very short limbs held away from the body in extended posture (*Fig. 1*). Infantogram revealed a poorly mineralized skull, short ribs, total lack of ossification centres of vertebral bodies, ischium and pubis, and very short lung bones with cupping and metaphyseal flaring (*Fig. 2*).

There was no history of having similar babies or consanguineous marriages in the family. The mother did not undergo routine antenatal ultrasonography. Permission for post-mortem was not granted.

#### Discussion

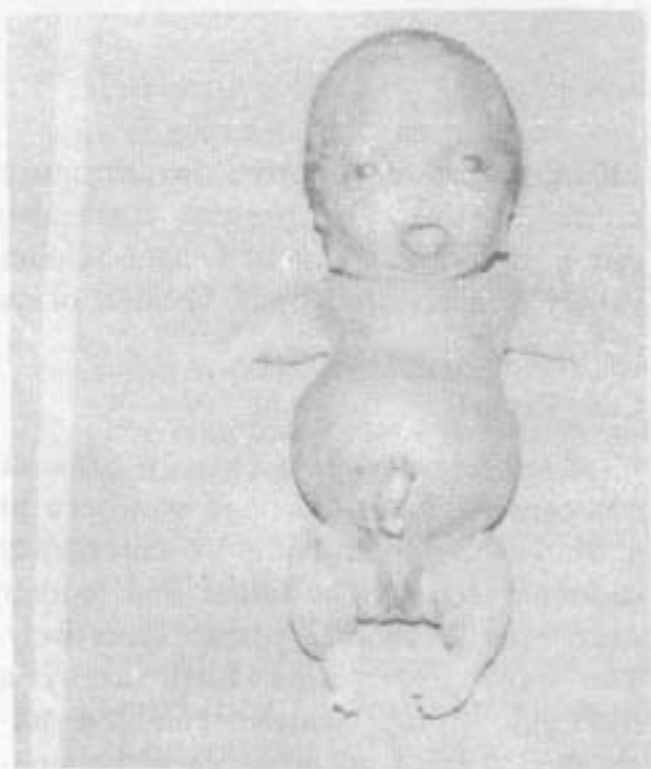Achondrogenesis is distinguished as a separate entity among the other skeletal dysplasias by the presence of poorly ossified skull and vertebral bones, severe micromelia with rudimentary ossicles of long

*From the Department of Pediatrics and Radio-diagnosis, Military Hospital, Agra Cantt (UP) 282 001.*

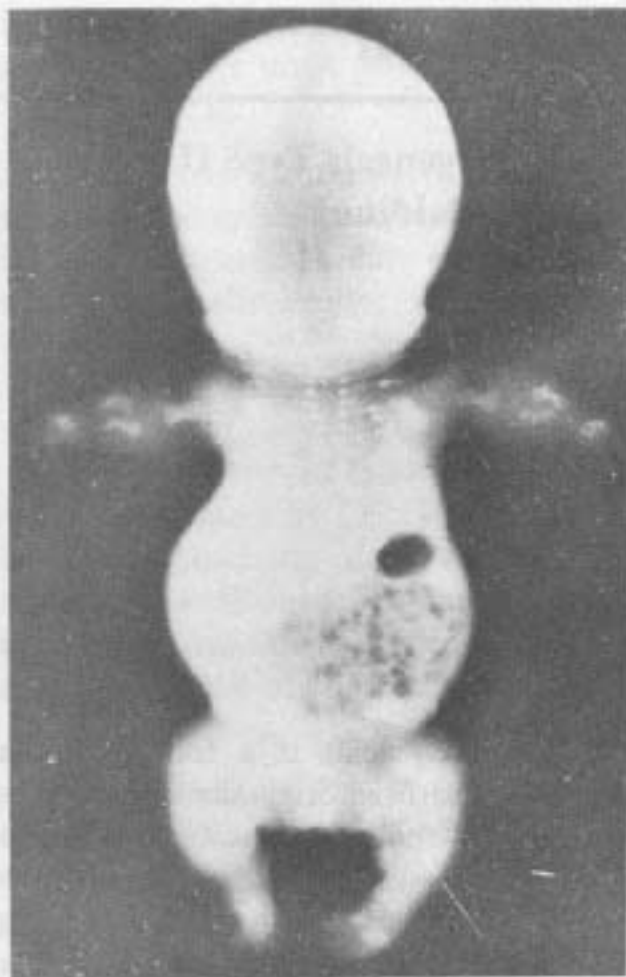
*Reprint requests: Maj T. Reddeppa, Department of Pediatrics, Military Hospital, Agra Cantt (UP) 282 001.*

*Received for publication: November 20, 1991;*

*Accepted: March 22, 1992*



*Fig 1. Photograph of Achondrogenesis Type II (Langer-Saldino) showing extremely short limbs and globular body.*



*Fig 2. Infantogram of the newborn.*

bones and greatly underossified iliac bones with absence of sacrum and pubic bones. The clinical and radiological features presented by us are diagnostic of Type II achondrogenesis (Langer-Saldino).

Type I (Parenti-Fraccaro) achondrogenesis is characterized clinically by head size proportionate with the trunk, extremely soft skull, short and stubby hands and barrel shaped thorax; radiologically by poorly ossified vault of skull, thin ribs with multiple fractures, total lack of ossification of the cervical through sacral vertebral bodies, extremely short long bones with definite metaphyseal expansion and prominent bony projections(5).

Histologically the two types of achondrogenesis are quite distinct from each other. In type I, resting cartilage is abnormal with chondrocyte inclusion bodies and dense cellularity in the hypertrophic zones

with disorganized endochondral ossification whereas in Type II, ballooning of chondrocytes with little intervening matrix and epiphyseal cartilage becoming lobulated and mushroomed giving an appearance of hypercellularity; are the usual findings on histopathology.

The conditions which are lethal and commonly confused with achondrogenesis are thanatophoric dwarfism and osteogenesis imperfecta (Type II). Thanatophoric dwarf can be differentiated from achondrogenesis by the presence of a prominent forehead, pear shaped chest, rhizomelic shortening of long bones, inverted 'U' appearance of lumbar spine and rectangular iliac bone. Babies of os-

teogenesis imperfecta (Type II) are small for gestation, often stillborn or premature, have a relatively large head, deep blue black sclera, beading of ribs, virtual absence of skull bones and crumpled (concertina) long bones with or without camptomelia.

Genetic counselling to the parents, after due confirmation of the diagnosis is a must, as achondrogenesis is an autosomal recessive disorder, where the affected individuals are almost always born in only one generation of a family. Antenatal diagnosis with real time ultrasound is now possible to identify the various fetal skeletal dysplasias in early pregnancy, so that, those with the poor postnatal prognosis can be terminated(6).

#### Acknowledgements

The authors wish to acknowledge Mrs. Gladys D'Souza for all her help and the Department of Virology, NIMHANS, Bangalore for help in investigations.

#### REFERENCES

1. Parenti GC. La anosteogenesi (una varietà della osteogenesi imperfetta). *Pathologica* 1936, 28: 447).
2. Fraccaro M. Contributo allo studio delle malattie del mesenchyma osteopoietico. L'achondrogenesi. *Folia Hered Pathol* 1952, 1: 190.
3. Camera G, Mastroiacova P. Birth prevalence of skeletal dysplasias in the Italian multicentric monitoring system for birth defects. In: *Skeletal Dysplasias*. Eds Papadatos CJ, Bartsocas CS. New York, Alan R. Liss, 1982, pp 441-449.
4. Jeelson UC, Prabhu S, Nambiar D. Prenatal diagnosis of Achondrogenesis. *Indian Pediatr* 1990, 27: 190-193.
5. Sillence DO, Rimoin DL, Lachman R. Neonatal dwarfism. *Pediatr Clin North Am* 1978, 25: 453-483.
6. Pretorius DH, Rumack CM, Manco-Johnson ML, *et al.* Specific skeletal dysplasias *in utero*: Sonographic diagnosis. *Radiology* 1986, 159: 237-242.

### Proximal Focal Femoral Deficiency

G. Mehrotra  
S.K. Bhargava  
V.K. Shiv  
K. Taneja

Proximal focal femoral deficiency (PFFD) which includes a congenital absence of proximal one third to two third of the femur often associated with other congenital anomalies, viz., absence of fibula, shortening of tibia, equinovarus foot, syndactyly, absence fourth and fifth rays, congenital dislocation of hip or oblique talus, has been studied by many authors, several of whom have proposed their own classifications. However, the most widely followed classification is by Aitken(1) based on the maturity of development of

*From the Department of Radiology, University College of Medical Sciences (Delhi University) and G.T.B. Hospital, Delhi 110 095.*

*Reprint requests: Prof. S.K. Bhargava, Head, Department of Radiology, University College of Medical Sciences and G.T.B. Hospital, Shahdara, Delhi 110 095.*

*Received for publication: July 23, 1990;*

*Accepted: April 16, 1992*