SPECIAL ARTICLE

BALLOON VALVOPLASTY—HOW TO DO IT

S. Shrivastava

Balloon catheters have been in use for therapeutic procedures since the introduction of balloon atrial septostomy by Rashkind and Miller in 1968(1). In this procedure, a fully inflated latex balloon is pulled across the foramen ovale, using a tangential force to tear the atrial septum. A similar tangential force was used by Semb *et al.* in 1979(2) to relieve pulmonary stenosis by pulling a fully inflated balloon angiocatheter across the pulmonary valve. However, successful relief of pulmonary valve stenosis by inflating a rigid balloon made of polyurethane under pressure, thus utilising the radial force to split the valve, was first reported by Kahn *et al.* in 1982(3). Since then, this procedure has been used to relieve stenosis of all heart valves and a variety of other obstructive lesions like pulmonary artery stenosis, aortic stenosis shunt or baffle obstructions.

Percutaneous balloon valvoplasty though a relatively new technique has shown promising results. It is safe and avoids thoracotomy. It has already become established as the treatment of choice for patients with isolated pulmonary valve stenosis in all age groups. It is cheaper than surgical pulmonary valvotomy which is an open heart procedure. The initial results of aortic valve balloon valvoplasty are encouraging but the long term results are awaited. It may possibly emerge as a useful palliative procedure for aortic valve stenosis of the young and elderly. This procedure is safer and cheaper than surgical aortic valvotomy.

Mitral valve balloon valvoplasty is feasible and has shown good initial results, but it is a complicated procedure. The natural history of the inter-atrial communication created is yet to be evaluated. The procedure is akin to closed surgical mitral valvotomy but the present cost of balloon mitral valvoplasty is much greater. It may become the alternative in circumstances where surgery is not desired or not possible. The experience with tricuspid valvoplasty is very limited but its feasibility has been established.

This article describes how percutaneous balloon valvoplasty is performed.

Steps of Valvoplasty

The steps of valvoplasty are outlined below.

1. Cross the stenosed valve with an end-hole catheter.
2. Pass an exchange guide wire and position it securely distal to the stenosis.
3. Remove the end hole catheter leaving the guide wire in position for the balloon dilatation catheter to be advanced over it.
4. Position the balloon dilatation catheter across the stenosed valve, with the valve at the centre of the balloon.

From the Department of Cardiology, All India Institute of Medical Sciences, New Delhi-110 029.

Received for publication January 24, 1989; Accepted September 23, 1990

5. Inflate the balloon till the waist disappears, hold it ior 8-10 sec and deflate rapidly. Repeat inflation and deflation 3-4 times.

Precautions During Valvoplasty

These include:

1. Keep one unit of blood ready.
2. Administer intravenous fluids slowly.
3. Monitor the cardiac rhythm and the systemic pressure carefully.
4. Keep the following drugs (in appropriate dosages) loaded in syringes: (*i*) Atropine, (*ii*) Verapamil, (*iii*) Methoxamine, (*iv*) Lidocaine, (*v*) Diazepam, and (*vi*) Morphine.
5. Keep the Cardioverter charged and fixed at appropriate levels of watts (this is particularly important in children).
6. Administer heparin in an appropriate dosage at the time of dilating the valve.

After Valvoplasty one should carefully monitor the vital signs and examine for cardiac tamponade and observe for any local vascular complications.

The technique used for individual valves are described below.

Pulmonary Valve Stenosis

Isolated pulmonary valvar stenosis with a gradient of more than 40 mm Hg merits valvoplasty. The procedure is contraindicated with a dysplastic pulmonary valve, infundibular pulmonary stenosis, and associated lesions (like ventricular and atrial septal defects) which will themselves need open heart surgery.

Procedure

The cardiac catheterisation and balloon dilatation procedure (BD) is performed under sedation with an intramuscular injection of pethidine, phenargan and chlorpromazine, supplemented with intravenous diazepam if necessary. The right and left heart studies are done by the routine percutaneous technique. A high femoral puncture is performed to facilitate the introduction of large sized balloon catheters. Pressures are recorded and samples are taken for cardiac output estimation.

Right ventricular angiography is performed in postero-anterior and lateral projections and the left ventricular angiography in the left anterior oblique view. The pulmonary annulus is measured on the angiogram and the location of the pulmonary valve delineated in relation to the left bronchus. This facilitates positioning of the balloon dilatation catheter (BDC) correctly across the pulmonary valve using the left bronchus as the landmark during fluroscopy. The arterial catheter is withdrawn into the descending aorta to monitor the arterial pressure during the procedure. A number 7F end-hole catheter is passed across the pulmonary valve and positioned in the distal left or right pulmonary artery. A teflon-coated exchange guide wire (260 cm long, 0.35-0.38 inch diameter) is introduced through the catheter and positioned deep in the pulmonary artery. The catheter and the sheath are then withdrawn taking care that the guide wire remains in position (*Fig. 1a*). Heparin 100 units/kg body weight is given at the time of BD. A Meditech balloon dilatation catheter, with balloon size 20 to 40% wider than the measured pulmonary valve annulus on the angiogram, is selected and passed over the guide wire across the pulmonary valve with the stenotic valve in the centre of the balloon (In some patients with very critical stenosis it is better to use a smaller balloon

Fig. 1. Pulmonary valvoplasty: Lateral view (a) guide wire across the pulmonary valve, (b) balloon dilatation catheter partially inflated 'waist' seen at the site of stenosed valve, and (c) fully inflated balloon with disappearance of the 'waist'.

Fig. 2. Aortic valvoplasty: Left anterior oblique view (a) guide wire with deflated balloon dilatation catheter across the aortic valve, (b) partially inflated balloon with 'waist' at the site of aortic valve, (c) fully inflated balloon with disappearance of the 'waist'

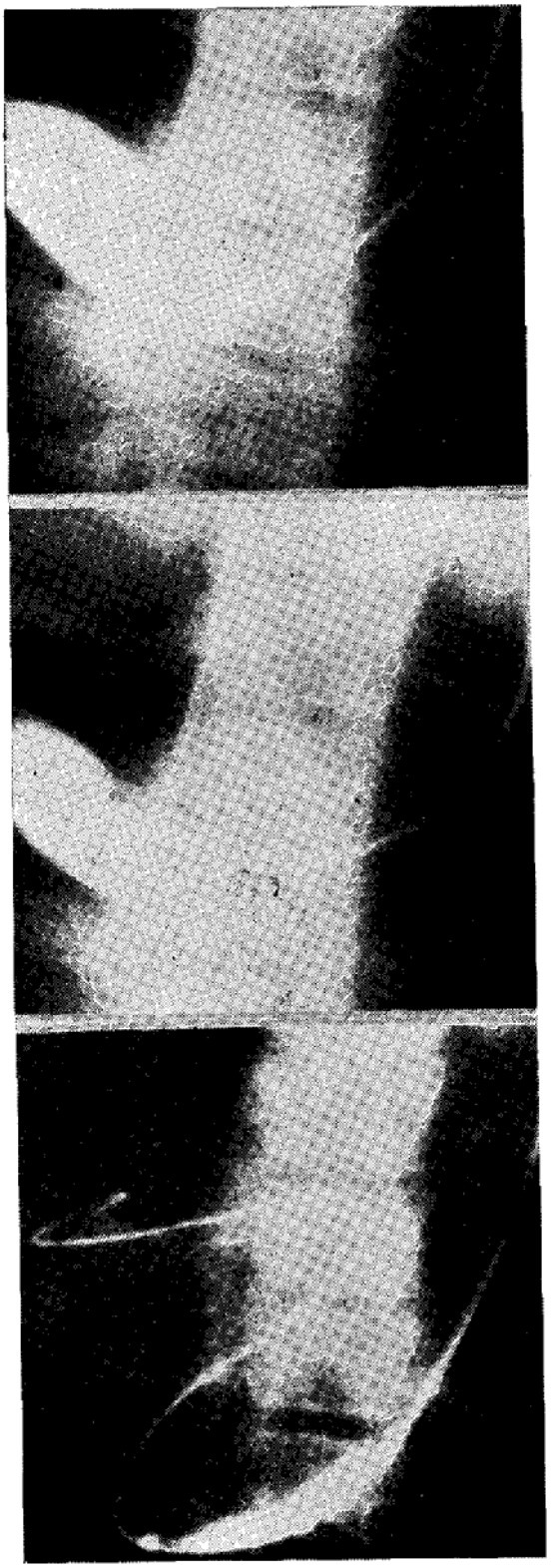

Fig. 3. Mitral volvoplasty: Right anterior oblique view (a) balloon dilatation catheter across the interatrial septum with the guide wire across the mitral valve, (b)balloon dilatation catheter partially inflated with the 'waist' at the mitral valve, and (c) balloon fully inflated with disappearance of the 'waist'.

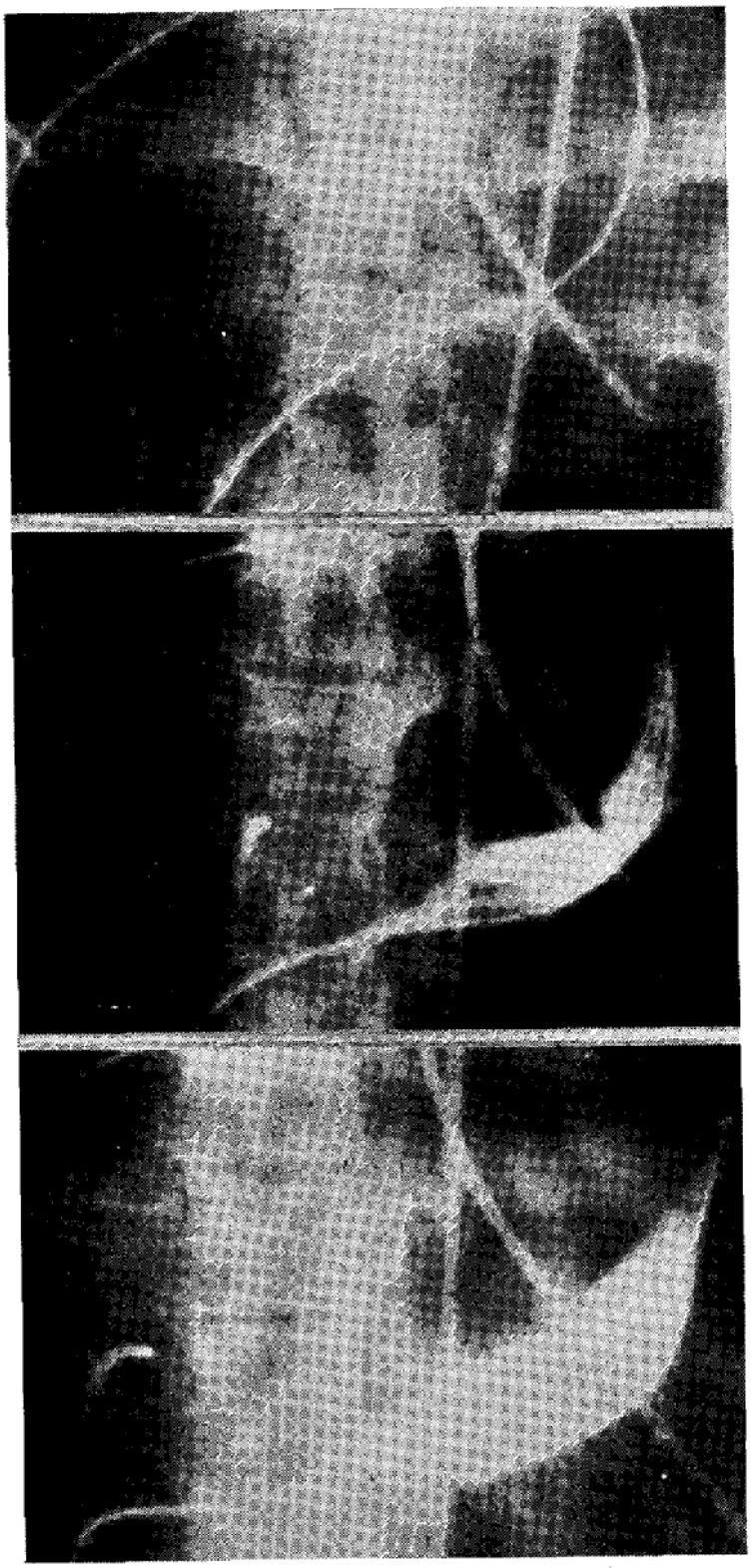

Fig. 4. Tricuspid valvoplasty: Posteroanterior view (a) guide wire with the balloon dilatation across the tricuspid valve, (b) balloon partially inflated with 'waist' at the site of the tricuspid valve, and (c) balloon fully inflated with disappearance of the 'waist'.

initially and then gradually go upto the desired size).

If the pulmonary valve annulus is bigger than 20 mm, a single BDC may not be adequate, two balloons will have to be used as the largest size BDC available is 25 mm in diameter. For the double balloon technique, another catheter is introduced from the left groin. The balloon is inflated with diluted angiographic contrast (1:4). In the initial phase of inflation a waist is seen at the site of the stenotic valve (*Fig. 1b*); the inflation pressure is increased till the waist disappears (*Fig. 1c*). Inflation is maintained for 8-10 sec. The balloon is then rapidly deflated. The procedure is repeated 3-4 times.

During inflation a fall in blood pressure and heart rate is noted. These recover spontaneously on deflation. Sometimes, bradycardia is slow to recover and intravenous atropine may be needed. The balloon dilatation catheter is withdrawn and sheath and endhole catheter are reintroduced over the guidewire. Right and left heart pressures and cardiac output are determined. The patient can be sent home the next day.

Pulmonary valvoplasty is very safe procedure. Except for transient arrhythmias during the balloon inflation, no complications are encountered.

Aortic Valve Stenosis

Isolated aortic valvar stenosis with a peak systolic gradient of more than 75 mm of Hg across the aortic valve is an indication for this procedure. The contraindications include more than mild aortic regurgitation, unicuspid aortic valve, and associated lesions needing open heart surgery.

Procedure

The right and left heart pressures and samples for cardiac output estimation are taken as described earlier. An additional arterial catheter is introduced from the left groin and placed in the descending aorta to monitor the arterial pressure(4). Aortic root and left ventricular angiograms are performed to evaluate the degree of aortic regurgitation, exclude any subvalvar pathology and measure the aortic annulus size. A BDC which measures 90% of the measured aortic valve annulus is taken. The aortic valve is crossed with an endhole catheter. A long 260 cm teflon coated 0.35-0.38 inch diameter guidewire is taken and an extra double curve is made over it using a pair of artery forceps. (However, preshaped guide wires may soon be commercially available). This curve facilitates the guide wires retention in the left ventricle and reduces the incidence of ventricular arrhythmias. This guide wire is passed through the catheter and positioned into the left ventricle; the catheter and the sheath are withdrawn and the selected BDC is passed over the guide wire and positioned across the aortic valve with the centre of the balloon at the level of the aortic valve. The inflation and deflation are carried out as described earlier. During the inflation many times the balloon is milked out of the aortic valve. To avoid this, the balloon catheter and the guide wire should be held firmly and, if milking is noted the balloon should be immediately deflated and repositioned. The right and left heart pressures are measured and samples for cardiac output estimation are again taken. An aortic root angiogram is repeated to assess the degree of aortic regurgitation.

The *complications* reported to occur are: (*i*) Local vascular complications of

bleeding or thrombosis of the artery; (*ii*) Malignant ventricular arrhythmias; (*iii*) Prolonged hypotension; (*iv*) Cerebrovascular accident; (*v*) Left ventricular perforation leading to cardiac tamponade; (*vi*) Tear of the aortic wall, aortic cusp avulsion, injury to the interventricular septum and severe aortic regurgitation (due mainly to the use of balloon which are too large).

Mitral Valve Stenosis

The main *indication* for the procedure is isolated mitral stenosis with moderate to severe pulmonary venous hypertension. The *contraindications* include (*i*) Mitral regurgitation more than mild; (*ii*) Aortic valve disease requiring surgery; (*iii*) Left atrial thrombus; and (*iv*) Severe subvalvular deformity.

Procedure (5)

Cardiac catheterisation is performed as described earlier. Right and left heart pressure data and blood samples for the estimation of cardiac output are obtained. A Swan-Ganz catheter is introduced from the left femoral vein to monitor the pulmonary artery wedge pressure.

Left ventricular angiogram is done in the right anterior oblique view to exclude mitral regurgitation, study the subvalvular apparatus and to define the position of the stenosed mitral valve in relation to the aortic sinuses. The last step helps in correctly positioning the BDC across the mitral valve.

The left heart catheter is positioned in the aortic sinus for later reference. The right heart catheter is withdrawn to the junction of superior vena-cava and the right atrium. A 140 cm, 0.25 inch guide wire is exchanged for a 7F Millin's transseptal sheath and dilator (Pediatric upto 12 yr of age). A standard Brokenborough (BB) transeptal needle (Pediatric upto 12 yr of age), is then advanced to the tip of the dilator. Both the needle and dilator are withdrawn over the atrial septum and the fossa ovalis identified by a sudden jerk of the needle. The needle position is confirmed under fluoroscopy in the lateral view, the needle should be pointing posteriorly. The fossa ovalis is then punctured by advancing the tip of the needle in an upward and leftward directions with a sudden motion(6). The "pop" of the BB needle is felt and, the position of the needle in the left atrium is confirmed by sampling, pressure measurements and contrast injection. The sheath and dilator are then advanced over the needle. The sheath is further advanced upto the tip of the dilator and then the dilator and needle are withdrawn leaving the sheath in the left atrium. A No. 7 Swan-Ganz catheter is advanced into the left atrium and manipulated to enter the left ventricle. A teflon coated exchange guide wire 0.35 or 0.38 inch diameter 260 cm long is taken and a wide arc J curve made over the soft end. This facilitates the positioning of the guide wire into the left ventricular cavity during the dilatations.

The Swan-Ganz catheter and the sheath are now withdrawn leaving the tip of the guide wire in the left ventricle. An 8 mm BDC is now passed on the guide wire and the balloon positioned across the interatrial septum (*Fig. 3a*). With the help of lateral fluoroscopy the centre of the balloon is positioned at the entry site of the left atrium. The balloon is then inflated and deflated as described earlier. The BDC is then withdrawn and changed to a 25 mm BDC. The method to accurately estimate the size of the BDC for mitral valve stenosis has not yet been worked out. I use

25 mm BDC in patients with a BSA of above 1 m^2 and 20 mm size in patients with a BSA of less than 1 m^2 or patients with very tight mitral stenosis in whom 25 mm BDC cannot be passed. The BDC is positioned across the mitral valve taking the landmark of the aortic sinuses as the reference point. Inflation and deflation are carried out as described earlier (*Figs. 3b & c*).

The pulmonary arterial wedge pressure and the left ventricular end-diastolic pressure are recorded. If the fall in the mitral valve gradient is not adequate, dilatation is repeated with two balloons. Two balloons are passed by using a double lumen catheter to pass two exchange guide wires and then positioning two BDCs of 15 mm each across the mitral valve. The BDC is then withdrawn and replaced by an end hole catheter.

The pressure data, blood samples for cardiac output and an oximetry run to assess any left to right atrial shunt is taken. Left ventricular angiogram in right anterior oblique view and pulmonary angio follow-through in the hepatoclavicular view are obtained to assess if mitral regurgitation and left to right atrial shunt at the site of transeptal puncture, respectively are present. Immediately after the procedure an echocardiogram is performed to exclude presence of any fluid in the pericardium. Later in the ward, the patients are carefully monitored for the next 24 hours for any evidence of pericardial effusion.

The *complications include* (*i*) Pericardial tamponade due to perforation of cardiac chamber at the time of transeptal puncture or manipulation of the guide wire; (*ii*) Malignant ventricular arrhythmias; (*iii*) Significant mitral regurgitation; (*iv*) Cerebrovascular accidents; and (*v*) Persistence of an atrial septal defect.

Tricuspid Valve Stenosis

A stenosed tricuspid valve merits valvoplasty.

Procedure

Right and left heart pressures and samples for cardiac output are obtained. Transtricuspid gradient is recorded with two catheters, one in the right atrium and the other in the right ventricle during held inspiration(7). A 260 cm large guide wire (0.038 inch) is placed in the distal pulmonary artery and a No. 25 mm balloon dilation catheter is passed over the guide wire (*Fig. 4a*) . The balloon is positioned across the tricuspid valve. The site of the tricuspid orifice is determined by withdrawing the right ventricular end-hole catheter across the tricuspid valve and noting the site of change in pressure tracing. The balloon catheter is inflated with diluted angiographic contrast till the waist formed by the stenotic valve disappears (*Figs. 4b and c*). Repeat left and right heart pressures are recorded. If the fall in gradient is not adequate by single balloon, two balloons are used.

Significant tricuspid regurgitation is a potential complication.

REFERENCES

1. Raskind WJ, Miller WW. Transposition of the great arteries: Results of palliation by balloon atrioseptostomy in thirty one infants. Circulation 1963, 38: 453-462.
2. Semb BKH, Tjonneland S, Stake G, Aabyholm G. Balloon valvulotomy of congenital pulmonary valve stenosis with tricuspid valve insufficiency. Cardiovasc Radiol 1970, 2: 239-241.
3. Kan JS, White R (Jr), Mitchell SE, Gardner TJ. Percutaneous transluminal

balloon valvuloplasty-New method for treating congenital pulmonary valve stenosis. N Eng J Med 1982, 307: 540-542.

4. Lababidi Z, Wu JR, Walls JT. Percutaneous balloon aortic valvuloplasty results in 23 patients. Am J Cardiol 1984, 53: 194-197.

5. Lock JE, Khalilullah M, Shrivastava S, Bahl V, Keane JF. Percutaneous catheter commissurotomy in rheumatic mitral stenosis. N Eng J Med 1985, 313: 1515-1520.

6. Duff DF, Mullins CE. Transseptal left heat catheterisation in infants and children. Catheter Cardiovas Diag 1978, 4: 213-223

7. Shrivastava S, Radhakrishnan S, Dev V. Concurrent balloon dilatation of tricuspid and calcific mitral valve in a patient of rheumatic heart disease. Int J Cardiol 1988, 20: 133-137.

NOTES AND NEWS

SHORT COURSES IN BIOSTATISTICS

The Christian Medical College, Vellore, Department of Biostatistics along with Epidemiology and Health Management Network of India (EPIDMAN), will be organizing the following intensive, application-oriented 3-week course in Biostatistics from April 22 to May 10, 1991: (*a*) Demographic-Analysis and their Biostatistical Applications; (*b*) Applied Multivariate Techniques; (*c*) PC-based Statistical Software in Health Care; (*d*) Introduction to Biostatistics and Hospital Statistics; and (*e*) Epidemiologic Methods and Analysis.

Fees: India Rs. 1000/- per course.

Last date for Registration: 15th March, 1991.

For further information contact:

Dr. P.S.S. Sundar Rao,
Professor and Head,
Department of Biostatistics,
Christian Medical College,
Vellore-632 002.