

Caudal Duplication Syndrome

A neonate born at 36 weeks of gestation through vaginal route with a birth weight of 2.1 kg was noted to have abnormal genitalia. There was bilaterally symmetrical duplication of labia minora, urethral openings, vaginal openings and anal dimples (*Fig. 1*). Both the anal openings were imperforate. Single pair of labia majora was visible on either side. The child was passing meconium through both the vaginal openings suggestive of bilateral recto-vaginal fistulae. On ultrasonography, kidneys were normal with no duplication of pelvic/lyceal system. Child had single urinary bladder, two urethra, single uterine cavity, single cervix with two vagina. Keeping in view the clinical and sonographic findings, we made a diagnosis of caudal duplication syndrome. The neonate later died due to shock and renal failure.

Caudal duplication syndrome consists of duplication of genitourinary, gastrointestinal system, especially hind gut, vertebral column, spinal cord and lower limb. The theories postulated include abnormal adherence between ectoderm and endoderm; or damage to caudal cell mass and posterior hind gut at day 23 to 25 of pregnancy. No risk factor and sex predominance is described. Treatment with multi-staged corrective surgeries is individualized according to extent of

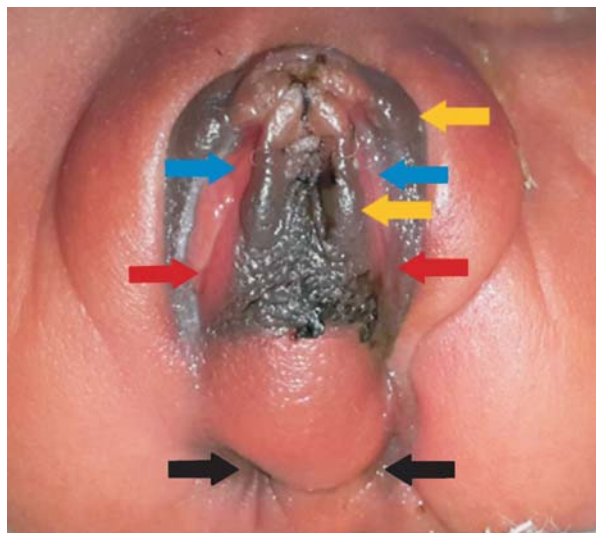


FIG. 1 Duplication of labia minora (yellow arrow), urethral openings (blue arrow), vaginal orifices (red arrow) and anal dimples (black arrow).

duplication and functionality of organ systems involved.

SONU MEENA AND *PRERNA BATRA

*Department of Pediatrics, University College of Medical Sciences (University of Delhi) and GTB Hospital, Delhi, India.
drprernabatra@yahoo.com

Congenital Non-syndromic Partial Anonychia

A 4-month-old infant presented with absence of eight fingernails and five toenails since birth (*Fig. 1*). There was no abnormality in the bones or teeth. Radiological examination of the hands and feet showed no abnormality. The infant did not have any delay in developmental milestones. Family history was non-contributory. A diagnosis of congenital non-syndromic partial anonychia was made.

Anonychia refers to absence of nail plate with an autosomal dominant or recessive inheritance. Congenital anonychia is rare and may be associated with other ectodermal or mesodermal malformations like epidermolysis bullosa, DOOR syndrome (deafness, onychodystrophy, osteodystrophy, and mental retardation)

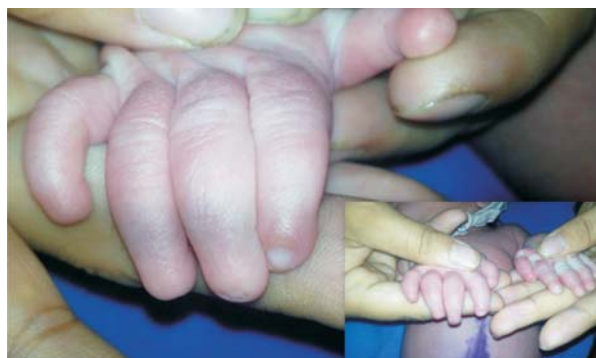

FIG. 1 Absence of the finger nails in congenital anonychia.

and Iso-Kikuchi syndrome. It is caused due to mutations in the exon 2 of *R-spondin 4* gene located on chromosome 20p13. Artificial nails are a treatment option.

SIDHARTH SONTALIA AND **ANUPAM DAS

*The Skin Clinic, Gurgaon; and #Medical College and Hospital, Kolkata; India. *anupamdasdr@gmail.com*